

Impact of Selenium on Structural Changes Induced by Hypothyroidism In Adult Male Rat's Testis

Eman G. Alhealy¹, Maysoon M. Alqazzaz², Wahda M. AL-Nuaimy³

1 Department of Anatomy, College of Medicine, University of Ninevah , Mosul, Iraq. 2 Department of Anatomy, College of Medicine, University of Mosul, Mosul, Iraq.

3 Department of Pathology, College of Medicine, University of Mosul, Mosul, Iraq.

Corresponding author: Eemanalhealy6@gmail .com

Received 04-05-2021 Accepted 29-07-2021

ABSTRACT

Background: Hypothyroidism is a common thyroid disorder which influences the function of many organs including the reproductive organ

Aim of this work: To examine the structural changes induced in the testis of adult male rats by hypothyroidism and the possible protective role of selenium.

Methods: forty male albino rats were classified into 4 groups; Group I: used as a control. Group II: were given carbimazole for hypothyroid induction; and Group III, IV received selenium alone and combination of carbimazole with selenium respectively, orally for 3 months

Results: The all outcomes of Group I and Group III rats showed no significant difference; therefore, they were collective in one group (control). Serum concentration of TSH was significantly increase while the level of T4, and testosterone concentrations were significantly decreased in groups II and IV. Testis of hypothyroid rats showed irregularity of some seminiferous tubule with thickening of their basement membrane, the diameter of seminiferous tubule and the height of germinal epithelium significantly decreased with decreases in the number of spermatocytes, Sertoli and Leydig cells. There was disorganization of the germinal epithelium with vacuolar degeneration of spermatocyte. In Addition, there was a widening of interstitium associated with edema and congested blood vessels. However, rats of group IV showed significantly an improvement in hormonal level and histological structure of the testicular tissue compared to group II. **Conclusion:** hypothyroidism affects the structure of a testis but adding selenium has ameliorative role on thyroid function and histological changes of the testis.

Keywords: hypothyroidism, selenium, testis.

الخلاصة:

الخلفية: قصور الغدة الدرقية هو اضطراب شائع في الغدة الدرقية يؤثر على وظائف العديد من الأعضاء بما في ذلك الجهاز التناسلي.

الهدف من هذا العمل: التركيز على التغيرات الهيكلية التي تحدث في خصية ذكور الجرذان البالغة بسبب قصور الغدة الدرقية والدور الوقائي للسيلينيوم.

الطريقة: تم تصنيف 40 ذكر من جرذان الوستر البيضاء إلى 4 مجموعات. المجموعة الأولى: تستخدم كعنصر تحكم. المجموعة الثانية: أعطيت كاربيمازول لتحريض قصور الغدة الدرقية. والمجموعة الثالثة والرابعة تلقت السيلينيوم وحده ، مزيج من كاربيمازول مع السيلينيوم على التوالي ، عن طريق الفم لمدة 3 أشهر

النتائج: لم تظهر نتائج جردان المجموعة الأولى والثالثة أي فرق كبير لذلك تم تجميعهم في مجموعة واحدة (مجموعة السيطرة). زاد تركيز هرمون TSH في المصل بشكل كبير بينما انخفض مستوى T4، وتركيزات التستوستيرون بشكل كبير في المجموعة الثانية والرابعة. أظهرت خصية الفئران المصابة بقصور الغدة الدرقية عدم انتظام بعض الأنايب المنوية مع سماكة غشاءها القاعدي، وانخفاض قطر النبيبات المنوية وارتفاع الظهارة الجرثومية بشكل ملحوظ مع انخفاض في عدد الخلايا المنوية وخلايا سيرتولي ولبيديك.. بالإضافة إلى ذلك، كان هناك اتساع في النسيج الخلالي المرتبط بالوذمة واحتقان الأوعية ومع ذلك، أظهرت جردان المجموعة الرابعة تحسناً ملحوظاً في المستوى الهرموني والتركيبي النسيجي لنسيج الخصية مقارنة بالمجموعة الثانية.

الخلاصة: قصور الغدة الدرقية يؤثر على بنية الخصية ولكن إضافة السيلينيوم له دور محسن في وظيفة الغدة الدرقية والتغيرات النسيجية للخصية والتي يمكن أن تعزى إلى نشاطها كمضاد للأكسدة.

الكلمات المفتاحية: قصور الغدة الدرقية، السيلينيوم، الخصية، الجردان

INTRODUCTION:

The thyroid gland secretes thyroxin (T4) and triiodothyroine (T3) hormones¹. These hormones play a critical role in controlling the infant's brain and somatic development and in the adult they regulate metabolic activity and the function of many organs². Previously, the scientist was thought that male gonads were unresponsive to thyroid hormones; however, recently thyroid receptors have been discovered in various tissues of the body including the gonads^{3,4}. Many investigators studied the relationship between the thyroid hormones and male reproductive system, the thyroid gland controls the proliferation and maturation of Sertoli cells and Ledyig cells during the developmental stage of testis in human and rodents⁴⁻⁶.

Thyroid dysfunction is a public problem, the incidence of thyroid disorder is increased considerably during the last decade⁷. Hypothyroidism is the most common thyroid dysfunction, the prevalence of which is correlated to age and sex⁸. Many organs in the body can be affected by thyroid dysfunction including male reproductive organ⁹. Hypothyroidism in post-pubertal men triggered many sexual dysfunctions as

decreased libido and delayed ejaculation⁵. The researcher showed that male fertility was not affected in short term hypothyroidism while impairment of reproductive function had been reported in prolonged condition¹⁰. However, decreased thyroid hormones level in hypothyroidism influence the number of Sertoli cells and altered the shape and motility of the sperm leading to fertility impairment¹¹.

Hypothyroidism is associated with the reduction of antioxidant defense mechanism against free radicles which produced by normal cellular metabolism^{12,13}. The accumulation of free radicles is responsible for abnormal function of the cells with increased cell death¹⁴.

Selenium (Se) is an essential micronutrient element for animals, it has an antioxidant properties¹⁵. And plays an important role in several physiological processes such as immunity and thyroid hormones production¹⁶. It has been used widely as an anticancer in several conditions including liver and renal cancer¹⁷. It has a protective role against the cisplatin-induced hepatotoxicity in mice¹⁸.

Therefore, the objective of this study was to determine the impact of

selenium on the histological changes in the testis of hypothyroid rats induced by carbimazole (antithyroid) drug.

2.MATERIAL AND METHODS

2.1.Carbimazole: is an antithyroid drug obtained from the local markets in Iraq as tablets supplied under the trade name NeoMercazole. It was dissolved in distilled water and orally administered to animals at a dose level of 6 mg/kg BW¹⁹.

2.2. Selenium: is an antioxidant agent existing as sodium selenite powder. It was dissolved in distilled water and orally administered to animals at a dose level of 10 µg/kg BW²⁰.

2.3. Experimental protocol

Forty adult male Wistar albino rats weighing about (190- 225) grams and aged about three months were purchased from the animal house of Veterinary College, University of Mosul. They were housed in polypropylene cages for period from the 1st of January till the 1st of April 2020. The animals were kept in well-ventilated cages, under standard environments, with free access to the standard diet and water. All animals had been examined carefully for general health status. The animals were divided into four groups (ten rats in each group) as following: Group I (control group) receive 0.5 distilled water daily for three months. Group II (hypothyroid group) the animals in this group received carbimazole dissolved in water and given as 0.5ml orally by gastric tube once daily for three months to induce hypothyroidism. Group III (Se treated) rats were given distilled water daily for three months and selenium was added orally by gastric tube once daily for the last two months. Group IV (hypothyroid + Se) rats were

given carbimazole as same as group II but we added sodium selenite orally by gastric tube once daily for the last two months. Towards the end of the experiment blood samples were collected from the retro-orbital venous plexuses for serum separation. Then all animals were killed by cervical decapitation, the testes were dissected out, the right testis used to estimate the level of Malonaldehyde (MDA) which regard as marker for oxidative stress while the left testis was fixed in Bouin's solution and processed through a series of alcohol dilutions and embedded in the paraffin wax to get sections of 5µm thickness which stained with haematoxylin-eosin (H&E) to be examined under the light microscope.

2.3.1. Hormonal assay: All blood samples were aspirated in the morning about 10-11 AM. The blood centrifuged at 400r Pm for 15 mint then serum was separated and stored at -20°C. Serum TSH, T4 and sex hormones (testosterone) were determined by using the minividis technique.

2.3.2. Morphometrical analysis: using colorr USB digital Image camera, which was provided with image processing software forr measuring all parameter. Seminiferous tubule diameter, germinal epithelium thickness were measured in six sections perr testis from ten ddifferent rats in each group at magnification power 400 X. Also, numbers of different germinal cells, Sertoli cells, and Leydig cells were also countedd in the same slides.

2.4. Statistical analysis : All data were reported as mean± SE (standard error). Statistical significant of data was performed by Graph pad prism using one-way ANOVA followed by the

Student-Newman-Keuls multiple comparison tests with the level of significance set at $P \leq 0.05$.

3.RESULTS

The all outcomes of Group I (control) and Group III (selenium treated) rats showed no significant difference; therefore, these two groups were collective in one group (control).

3.1.Hormonal

Analysis:

Hypothyroidism was established by measuring TSH and T4. The serum concentration of TSH, T4 level and testosterone were offered in Table (1) and Table(2). Serum TSH was significantly increased at ($p \leq 0.05$) while T4 was significantly decreased in GII (hypothyroid) followed by GIV (hypothyroid + Se) in comparison to control group and there was a significant difference between both treated groups (GII and GIV). The serum concentration of testosterone showed the least significant decrease in GII followed by GIV compared to control group. There was a significant differences between both treated groups.

3.2. Oxidative stress biomarker of the testis:

The mean concentration of MDA in the testis was highest significant in Group II (hypothyroid)

followed by Group IV (hypothyroid +Se) in comparison to control group. The MDA level in Group IV was decreased but the difference was not significant compared to group II ($P > 0.05$) (Table 3).

3.4.Quantitative-micro-morphometrical measurement:

A- parameters of seminiferous tubule (ST) were illustrated in the table (4): there was a significant decrease in diameters of ST of hypothyroid group at ($P \leq 0.05$) compared to control and hypothyroid + selenium treated groups. In addition, the height of germinal epithelium reduced in treated groups with significant decrease in hypothyroid group at ($P \leq 0.05$) compared to control group but the difference was not significant compared to hypothyroid+selenium treated group. Whereas the thickness of basement membrane of ST was significantly increased in hypothyroid group compared to both control and hypothyroid +selenium treated groups. P-values of spermatogenic, Sertoli, and Leydig cells were presented in table(5). Hypothyroidism caused a statically significant reduction in a number of spermatogenic, sertoli and leydig cells ($P \leq 0.05$)

Table 1: serum concentration of thyroid hormones in different groups of male rats .Data were expressed as Mean ± SE

Groups Parameters	GI (Control)	GII (Hypothyroid)	GIV(Hypothyroid+Se)
TSH (µIU/ml)	2.68±190 A	5.86±0.03 B	4.42±0.11 C
T4 (nmol/L)	76.66±1.49 a	55.67±0.18 b	67.47±1.16 c

-Different letters mean there is a significant difference at $p \leq 0.05$.

Table 2: The serum concentration of testosterone in different groups of male rats . Data were expressed as Mean ± SE

Parameter	Control group	Hypothyroid group	Hypothyroid+Sel group
testosterone (ng/ml)	4.39±0.37 A	0.68±0.10 B	2.34±0.17 C

-Different letters mean there is a significant difference at $p \leq 0.05$.

Table 3: The effect of hypothyroidism on MDA level in testicular tissues.

Parameters	Groups		
	Control group	Hypothyroid group	Hypothyroid+Se group
MDA ng/gram tissue	212.10±8.73A	350±10.26 B	315.8±6.38 C

-Different letters mean there is a significant difference at $p \leq 0.05$.

Table (4): The parameters of ST (µm).

Groups	Tubular diameter	Germinal epithelium thickness	Basement membrane thickness
GI (Control)	373.6±50.9 a	91.5±5.03 A	2.0 ±0.1 a
GII (Hypothyroid)	172.7±20.9 b	70.06±5.2 B	2.9±0.3 b
GII(Hypothyroid+Se)	338.6±28.2 a	77.2±3.2 AB	1.4±0.1 a

-Different letters with in column mean there is a significant difference at $p \leq 0.05$.

-similar letters within column mean there is a non-significant difference at $p > 0.05$.

Table (5): The values of spermatogenic, sertoli and leydig cells.

Groups	speratogonia	spermatocyte	spermatid	sertoli	leydig
GI (Control)	61.5±1.0a	174.2±3.8 A	215.7±3.8 a	19.5±0.8 a	29.3±0.9 a
GII (Hypothyroid)	52.2±3.0 ab	56.2±1.6 B	96.2±4.2 b	7.8±0.5 bc	5.2±0.5 b
GII (Hypo+Se)	55.7±1.0 ac	64.5±1.3 C B	175±5.1 c	9.6±1.0 c	16.5±2.0 c

-Different letters within column mean there is a significant difference at P≤ 0.05.

-similar letters with in column mean there is a non-significant difference at P> 0.05.

3.4. Histological Finding:

Control groups: in this group, the testis exhibited normal architecture . it made up of many rounded to oval seminiferous tubules (ST) separated by narrow connective tissues interstitial spaces (Fig.1). Each tubule is surrounded by intact basal lamina on which arrest spermatogenic and sertoli cells. The spermatogenic lineage consist of spermatogonia that rest on the basement membrane and appeared as small cells with rounded nuclei, followed by large primary spermatocytes with large spherical nuclei. spermatids were detected along with spermatozoa that filled the lumen of ST (Fig. 2). In addition, between the germ cells there was a sertoli cells (supporting cells) which characterized by its oval or triangular nuclei, in the interstitium there were blood vessels with clump of rounded eosinophilic leydig cells (Fig 3).

Hypothyroid group: experimental hypothyroidism produced histological changes in testicular parenchyma represented by the widening of interstitium with several ST had irregular boundaries, there were dilated and congested blood vessels in the interstitium (Fig. 4). Some seminiferous

tubule showed disorganization of the germinal epithelium with wide gap spaces between the cells associated with exfoliation of the germinal epithelium to lumen of tubule (Fig. 5) degenerated cells with a dark nucleus and highly eosinophilic cytoplasm were detected associated with vacuoles in the cytoplasm of spermatocyte and in the interstitium there was hyaline acidophilic material (Fig. 6). Moreover, some tubules showed regulatory and thickening of their basement membrane with few, vacuolated Sertoli cell and arrested spermatogenesis at spermatocyte level with few leydig cells (Fig. 7).

Hypothyroid + selenium treated group: treated rats with selenium showed improvement in the histopathological changes induced by hypothyroidism . Most of ST looked normal with a regular outline and lumen contain sperm, with less widening of intertubular space (Fig. 8). Most of ST showed improvement of the germinal epithelium with spermatogonia spermatocyte, spermatid and spermatozoa, there were few gap spaces between germinal epithelium (Fig. 9).

Still, there is edema in the interstitium

with increased leydig cells (Fig. 10).

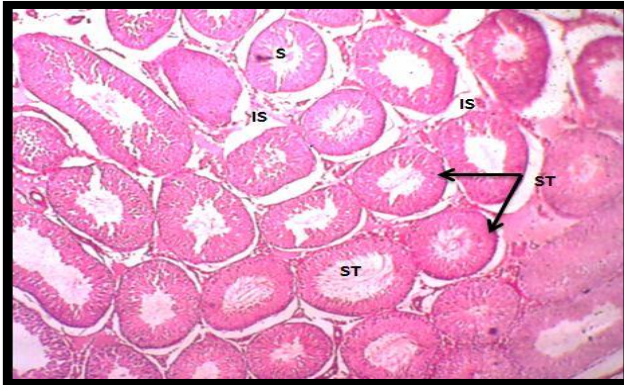

Fig .1: Control group, testicular tissue showed many rounded and oval seminiferous tubule (ST). Narrow interstitial tissues (IS). H&E, 100X

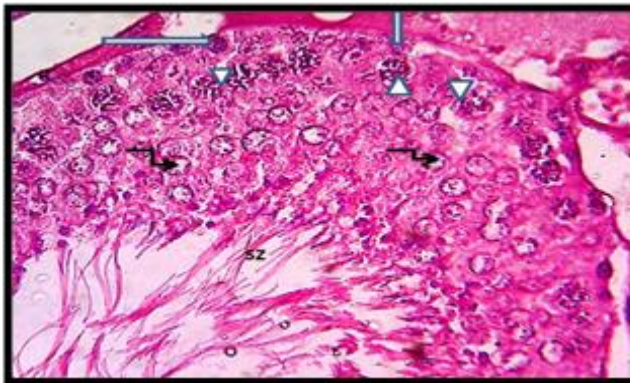


Fig .2: Control group, seminiferous tubule showed basement membrane (BM) spermatogonia (arrow). Primary spermatocyte (head arrow), spermatid (curved arrow), spermatozoa (SZ) filled the lumen of ST. H&E.400X

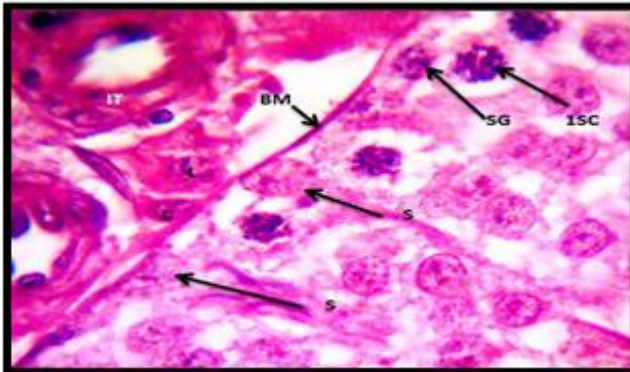


Fig3: Control group showed spermatogonia (SG), sertoli cell (S) rest on basement membrane (BM). Primary spermatocyte (ISC). Interstitial tissue (IT) with leydig cell (L) and blood vessel (BV) H&E. 400X.

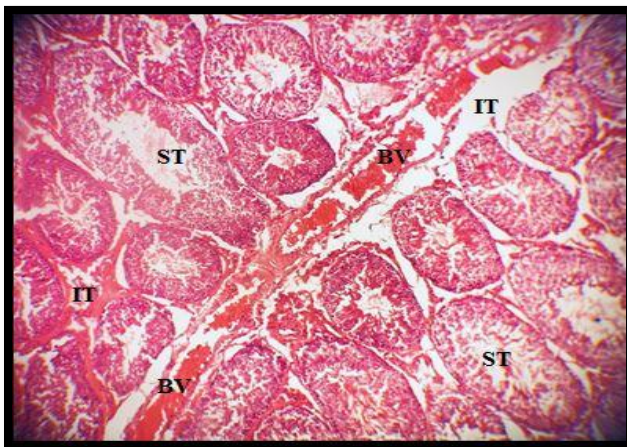


Fig.4: Hypothyroid testis. Testicular tissue showed irregularly of some seminiferous tubule (ST) with widening, edema and hemorrhage of interstitial tissue (IT). Dilated blood vessel (BV). H.E.100X.

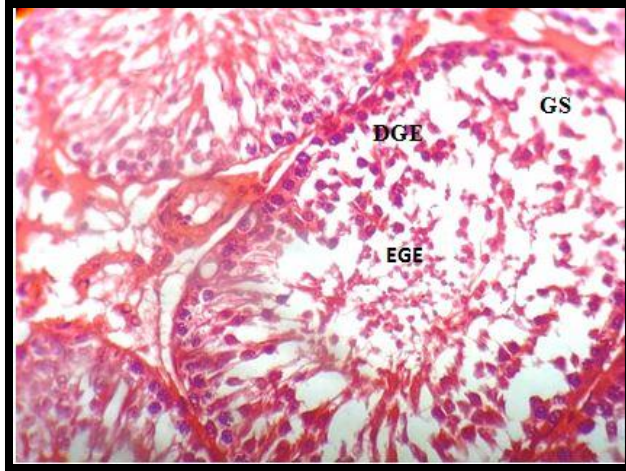


Fig.5: Hypothyroid group: seminiferous tubule showed disorganization of germinal epithelium (DGE) with wide gap spaces between the cells (GS). Exfoliation of germinal epithelium to lumen of tubule (EGE).

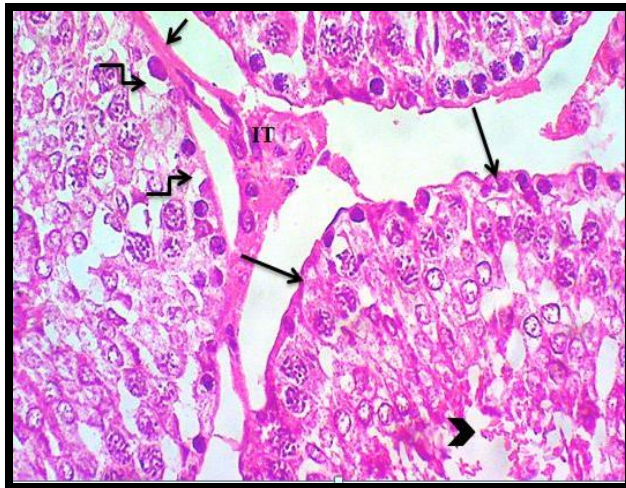


Fig.6: Hypothyroid group some ST showed irregularly of basement membrane (arrows). Vacuolated cell (curved arrows). Arrested of spermatogenesis at spermatocyte level with degenerated spermatid (head arrow). Interstitial space (IT) with few leydig cell. H&E.400X

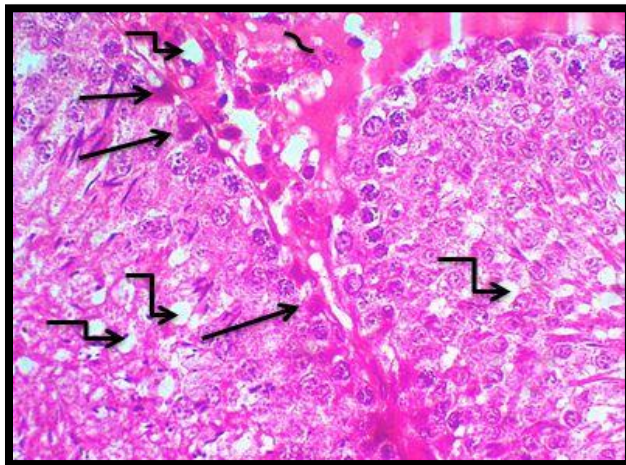


Fig 7: Hypothyroid Group: seminiferous tubule showed degenerated cells with dark nucleus (arrows). With Vacuoles in the cytoplasm of spermatocyte and in the interstitium (curved arrows) associated with deposition of hyaline acidophilic material (~). H&E. 400X

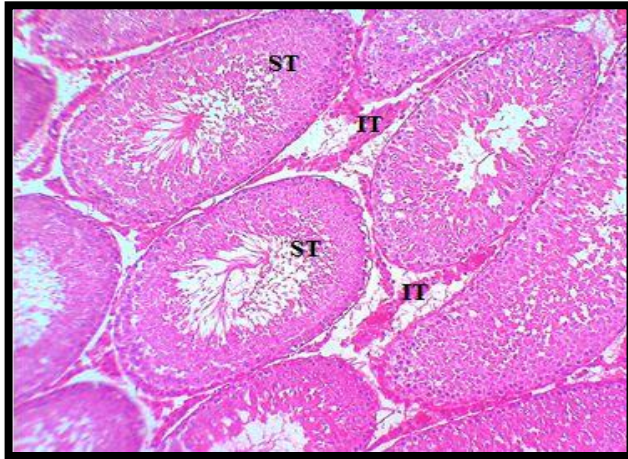


Fig.8. Hypothyroid- selenium treated group: testicular tissue showing most of seminiferous tubule (ST) look normal with regular outline and lumen contains sperm(S).with less widening of intertubular space. H&E.

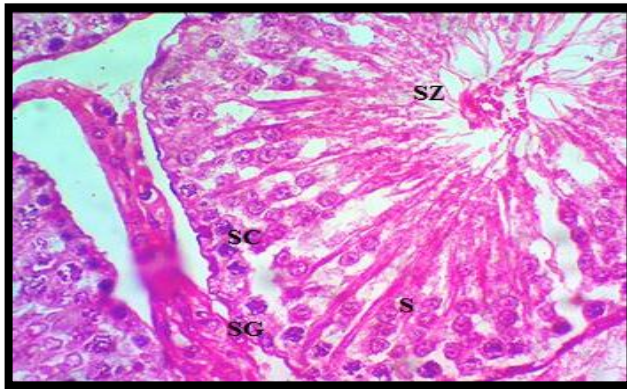


Fig.9. Hypothyroid- selenium treated group, ST showed improvement of germinal epithelium , spermatogonia (SG) spermatocyte(SC) , spermatid (S) and spermatozoa (SZ). still there were few gap spaces (GS)between germinal epithelium.H&E.300X

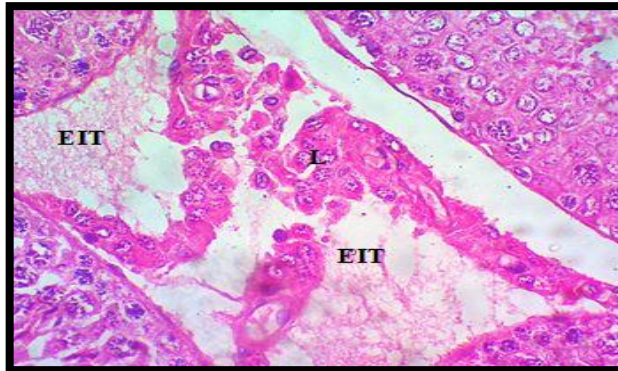


Fig.10: Hypothyroid-selenium treated group: still there is edema in the interstitium (EIT) with increased leydig cells (L). H&E 400X

4-DISCUSSION

Hypothyroidism is a clinical condition caused by reduction in the secretion of thyroid hormones from thyroid gland, it adversely affects the function of many organs including the reproductive function²¹. A previous study confirmed the role of thyroid hormones in testicular development⁵, other one suggested that thyroid dysfunction in adult men was

related to an abnormality in sexual activity and impaired fertility²².

TSH and T4 were used as an indicator for normal thyroid function in human and other animals²³. The induction of hypothyroidism in this study was confirmed by significant reduction in T4 and elevation of TSH concentration. This result coincide with other studies that used carbimazole for

six weeks to induce hypothyroidism in experimental animals²⁴. The reduction of thyroid hormones level is due to the action of carbimazole which inhibit iodination of tyrosine in the thyroid gland and as a consequences the concentration of TSH was elevated by positive feed-back effect on hypophysis²⁵. However, the thyroid function was improved by given selenium to hypothyroid rats in which the level of T4 and TSH were closer to the control group.

The correlation of hypothyroidism to testicular function is controversial some authors showed that hypothyroidism poorly affect testicular function^{26,22}

However, The achieved data of this study approved that hypothyroidism produced a structural change on the testis represented by irregularity of the outline of some ST with arrested of spermatogenic maturation and exfoliated of germinal epithelium in the lumen of tubule. Moreover, there was disorganization in germinal epithelium with decreased in the height of these cells. Reduction in the number of spermatocytes, spermatid, sertoli and leydig cells had been recorded. A similar finding was obtained by other authors^{24, 27}. To understand the structural changes of testicular tissues produced by hypothyroidism, the oxidant-antioxidant state was studied in this work by measuring the level of MDA which is regarded as a marker for oxidative stress. The obtained data showed a significant elevation of MDA level in the hypothyroid group. This result was in accordance with other researchers who attributed the pathological features of testis in hypothyroidism to the accumulation of free radicals and increased oxidative stress with lipid

peroxidation which was responsible for cellular damage and testicular dysfunction that represented by a reduction in sperm count with an increase of abnormal and immotile sperm²⁸.

Furthermore, the reduction of testosterone level which observed in this study and also reported by other investigator²⁹ may explain early detachment of spermatids from Sertoli cells leading to exfoliation of degenerated cells in the lumen of the ST.

The reduction of testosterone level in hypothyroidism may be attributed to many factors as decreased production of binding globulin for sex hormones from the liver³⁰. Other factors include the disruptor effect of hypothyroidism on hypothalamus-pituitary-testis axis with the subsequent reduction in testosterone³¹. While other authors explain the inhibition of steroidogenesis to the effect of hypothyroidism on the number and function of leydig cells³²

Moreover, The result of current study showed widening of interstitium associated with edema and dilated blood vessels. This result was observed by another investgator²⁴. This may be related to an excess of lymphatic exudate and capillary destruction which result from increased blood endotoxins and toxic effect of free radicle in oxidative stress status³². The treatment of hypothyroid rats in the current study with (Se) showed improvement in the thyroid function represented by elevation of T4 with depression of TSH level compared to hypothyroid group (GII) and this result was supported by other studied^{33,34} who explained this improvement by the action of Selenoenzyme, which has an important

role in thyroid hormones production. Moreover, treatment of rats with (Se) resulted in a significant increase in testosterone level and improvement in structural changes induced by hypothyroid status. This result was in agreement with another study that observed an improvement in the ultrastructure of rat's testis treated with carbimazole³⁵. Many investigators studied the effect of (Se) on toxicity produced by different chemicals, however, some reported its protective effects³⁶. While others deny it³⁷. Santos

Acknowledgments

Authors extend grateful thanks to the Faculty of Veterinary Medicine Mosul, Iraq for their help during research work.

5- References

1. Guyton A and Hall J. Guyton and Hall Textbook of Medical Physiology. 12th ed ., Saunders; Elsevier Limited, USA, (2011): P.907
2. Alahmar A, Dutta S, Sengupta P. Thyroid hormones in male reproduction and infertility. *Asian Pac J Reprod* 2019; 8(5): 203-210.
3. Wajner SM, Wagner MS, Melo RC, Parreira GG, Chiarini-Garcia H, Bianco AC. Type 2 iodothyronine deiodinase is highly expressed in germ cells of adult rat testis. *J Endocrinol*, 2007;194: 47–54.
4. Billings, H.J, Viguie, C, Karsch, F.J.; Goodman, R.L, Connors, J.M. and Anderson, G.M .Temporal requirements of thyroid hormones for seasonal changes in LH secretion. *Endocrinol* . 2002; 143(7): 2618- 25.
5. Carani, C, A. M. Isidori, A. Granata, E. Carosa, M. Maggi, A. Lenzi,. Multicenter study on the prevalence of

and Takahashi (2008) reported that chemo protective mechanism of (Se) may be due to its antioxidant activity as well as its role in the reduction of lipid peroxidation and in DNA repair pathway³⁸.

In conclusion, the current study noted the protective effect of selenium against structural changes of rat testis induced by hypothyroidism. This may be attributed to its role in thyroid hormones production as well as its antioxidant activity with reduction of oxidative stress induced by hypothyroidism

Conflict of interest

The authors assert no conflict of interests of the manuscript.

- sexual symptoms in male hypo- and hyperthyroid patients.- *J. Clin. Endocrinol. Metab.*2005; 90(12): 6472-79.
6. Holsberger, D. R, P. S. Cooke. Understanding the role of thyroid hormone in Sertoli cell development: a mechanistic hypothesis. *Cell Tissue Res.* 2005; 1: 133-140.
7. Tananakina, N., V. I. Kravchenko, I. A. Luzanchuk, I. P. Lubyanova, A. N. Karakashyan, I. V. Kalachova. The frequency of goiter and iodine supply in the southeast region of Ukraine in the beginning of governmental program of iodine insufficiency prevention.- *Mezhdunar. endokrinol. Zh.* 2005; 1: 34-8 (in Ukrainian).
8. Fatourech V. Subclinical hypothyroidism: an update for primary care physicians. *Mayo Clinic Proceedings.*2009;84:65-71.
9. Krassas, G. E., K. Poppe, D. Glinoe.. Thyroid function and human

- reproductive health.- *Endocr. Rev.* 2010; 31 (5): 702-55.
10. Krassas G.E.,and Pontikides N Male reproductive function in relation with thyroid alterations. *Clin Endocrinol Metab.* 2004; 18:183-95.
11. Krassas G. E., Pontikides N., Deligianni V., Miras K. A prospective controlled study of the impact of hyperthyroidism on reproductive function in males. *J Clin Endocrinol Metab.* 2002;87:3667-71.
12. Sahoo DK, Roy A, Bhanja S, Chainy GB. Hypothyroidism impairs antioxidant defense system and testicular physiology during development and maturation. *General and Comparative Endocrinol.* 2008;156: 63–70.
13. Zamoner A, Barreto KP, Filho DW, Sell F, Woehl VM . Propylthiouracil-induced congenital hypothyroidism upregulates vimentin phosphor ylation and depletes antioxidant defenses in immature rat testis. *J. Mol. Endocrinol.* 2008;40(3) :130-4.
14. Küçükakin B, Gögenur I, Reiter RJ, Rosenberg J. Oxidative stress in relation to surgery: is there a role for the antioxidant melatonin? *J Surg Res.*2009;152: 338–47.
15. El -Demerdash FM and Nasr HM. Antioxidant effect of selenium on lipid peroxidation, hyperlipidemia and biochemical parameters in rats exposed to diazinon. *J Trace Elem Med Biol.*2014; 28:89–93..
16. Tinggi U. Selenium: Its role as an antioxidant in human health. *Environ Health Prev Med.* 2008;13:102–8.
17. Brigelius-Flohé R, Banning A and Schnurr K. Selenium-dependent enzymes in endothelial cell function. *Antioxid Redox Signal.* 2003; 5:205–15.
18. Liao Y, Lu X, Lu C, Li G, Jin Y, Tang H. Selection of agents for prevention of cisplatin-induced hepatotoxicity. *Pharmacol. Res.*2008;57(2): 125-31.
19. Treesh SA and Khair NS. Effect of thyroid disorders on the adult female albino rats (Histological and Histochemical Study) *J Cytol Histol.* 2014; 5:4.
20. Swathy S, Panicker S, Indira M. Effect of exogenous selenium on the testicular toxicity induced by ethanol in rats. *Ind. J. Physiol. Pharmacol.* 2006; 50(3): 215-24.
21. Krassas GE, Markou KB. The impact of thyroid diseases starting from birth on reproductive function. *Hormones.* 2019:1-7.
22. La Vignera S, Vita R. Thyroid dysfunction and semen quality. *Int J Immunopathol Pharmacol* 2018; 32: 1-5.
23. Kelly, G.S. Peripheral metabolism of thyroid hormones: a review, *Altern Med Rev.* 2000; 5:306- 33.
24. Saber Abdel-Rahman Sakr, Sobhy Elsaïd Hassab ELnaby, Yosry Aly Okdah, Ahmed Mohamed El-Shabka. Impact of ginger aqueous extract on carbimazole induced testicular degenerative alterations and oxidative stress in albino rats. *J Coast Life Med .* 2017; 5(4): 167-173.
25. Abraham P, Avenell A, Park CM, Watson WA, Bevan JS. A systemic review of drug therapy for Graves hyperthyroidism. *Eur J Endocrinol.* 2005;153:484–98
26. Wagner MS, Wajner SM, Mala AL. Is there a role for thyroid hormone on spermatogenesis? *Microsc Res Tech.* 2009; 72: 796-808.
27. Prathima P, Venkaiah K, Pavani R, Daveedu T, Munikumar M, Gobinath M, Valli M, Sainath SB. α -lipoic acid inhibits oxidative stress in testis and attenuates testicular toxicity in rats exposed to carbimazole during

- embryonic period. Toxicology reports. 2017;4:373-81.
28. Hoda I. Bahr and Abdelaziz E. Ibrahim. Phytopreventive effect of *Salvia officinalis* L. on infertility induced by hypothyroidism in male albino rats. *Int. J. Sci. Res.* 2015; : 4 (1) :2277 –79
29. Donnelly P., White C. Testicular dysfunction in men with primary hypothyroidism; reversal of hypogonadotropic hypogonadism with replacement thyroxine. *Clin Endocrinol.* 2000; 52: 197-201.
30. Jassim. M. A. Alkal and Sarah. J. S. Alzerjawi. Effect of propyl thiouracil-induced hypothyroidism on reproductive efficiency of adult male rats. *Bas.j.vet.Res.* 2013; 12(2): 113-21
31. Chiao Y.C., Cho W.L., and Wang P.S. Inhibition of testosterone production by propylthiouracil in rat Leydig cells. *Biol Reprod* 2002;67:416-22.
32. Jalilvand N, Hosseini M, Beheshti F, Ebrahimzadeh-Bideskan A. Protective effect of PPAR γ agonist pioglitazone, on testicular tissue and sperm parameters in hypothyroid rats. *Toxin Reviews.* 2019;24:1-10
33. Amara, I.B.; Bouaziz, H.; Guermazi, F. and Zeghal, N. Effect of selenium on
38. Santos R A, Takahashi C S Anticlastogenic and antigenotoxic effects of selenomethionine on hypothyroidism induced by methimazole (MMI) in lactating rats and their pups, *Acta Biologica Hungarica.* 2010; 61(2), pp: 145–57.
34. Erdal, M.; Sahin, M., Hasimi, A.; Uckaya, G.; Kutlu, M. and Saglam, K. Trace element levels in hashimoto thyroiditis patients with subclinical hypothyroidism", *Biological Trace Element Research.* 2008;123(1-3):1-7.
35. Saber A. Sakr, Hoda A, Mahran Amany E. Effect of selenium on carbimazole-induced ultrastructural changes in testes of albino rats. *Egypt. J. Exp. Biol (Zool.)* . 2011; 7(1): 33 – 41
36. Kara H, Cevik A, Konar V, Dayangac A, Yilmaz M. Protective effects of antioxidants against cadmium-induced oxidative damage in rat testes. *Biol. Trace Elem. Res.* 2007; 120(1-3): 205-11.
37. Adesiyan AC, Oyejola TO, Abarikwu SO, Oyeyemi MO, Farombi EO. Selenium provides protection to the liver but not the reproductive organs in an atrazine-model of experimental toxicity. *Exp. Toxicol. Pathol.* 2011; 63(3): 201-7.