

The Role of Local Dermal Tube in Atrophic Scar Revision

Zainab Noori Fakhir, Zakaria Yahya Aradjy

ABSTRACT:

BACKGROUND:

Atrophic scars are commonly faced. The common feature of these scars is their bottom, which is located below the level of the surrounding tissue. Scar revision can be a complex process that requires a careful assessment, technical expertise, recognition of the psychosocial issues if a satisfactory outcome is to be achieved.

OBJECTIVE:

The application of the dermal tube technique was first used by Mallucci et al. for the treatment of atrophic tethered scars.

PATIENTS AND METHODS:

Between January 2017 to April 2018, 16 patients presented to us with atrophic tethered scars. Their ages ranged between (4 -40) years and they included seven females and nine males. The locations of the scars were in the face; (5) patients, in the neck; (2) patients, in the forearm; (3) patients, in the arm; (1) patient, in the back; (1) patient, in the abdomen; (2) patients, in the buttocks; (1) patient, and in the leg; (1) patient. The average history of scar was one and a half year. All scars were treated surgically using dermal tube technique.

RESULTS:

Sixteen patients with tethered atrophic scars at different sites and due to different etiologies were treated surgically with scar revision by the dermal tube technique. Patients results were evaluated subjectively by the visual analogue scale for the post-surgical results. The average value of the visual analogue scale was 7.8 with excellent improvement of the contour of the atrophic scar, and a near normal skin texture with no recurrence of the deformity during the follow up period. Three of our sixteen patients were unsatisfied with their results.

CONCLUSION:

dermal tube technique is an effective method to correct tethered atrophic scars. It is a simple and single stage operation can be performed under local anesthesia ,with good results regarding scar appearance and minimal recurrence of the deformity

KEYWORDS: dermal tube, atrophic scars, scar revision, tethered scars, collagen

INTRODUCTION:

A scar can be defined as a fault or blemish resulting from some former condition, wound, sore or burn. This scar tissue lacks the characteristics of normal uninjured skin⁽¹⁾. Scarring is an integral component of the healing process and an outcome of the remodeling stage of wound repair which begins 2-3 weeks after injury and lasts for a year or more. A preferred scar is one that has matured rapidly without contraction or increase in width or formation of more collagen than necessary for its strength⁽²⁾. Scar revision can be one of the most complex aesthetic procedures depending upon the severity and location of the scar.

An extensive combination of techniques may be employed. Scar revision maybe an option to

improve or reduce the appearance of a scar⁽³⁾. It can also restore function and correct disfigurement of the skin which has its own cellular make up and function⁽⁴⁾. Some scars after a long period and sometimes because of treatment, become very thin, pale and atrophic⁽⁵⁾.

Atrophic (hypotrophic) scars: During the healing process, tissue remodeling gives rise to either atrophic or hypertrophic scar. The balance between metalloproteinase (MMPS) and their inhibitors controls this process. However, when there is an inadequate inhibitor response, this results in diminished deposition of collagen factors and subsequently forms an atrophic scar.

ATROPHIC SCAR REVISION

Atrophic scars result from the loss of underlying supporting tissues and contains less collagen and proteoglycan resulting in a thinner extracellular matrix than in the surrounding normal tissue. The process can take few weeks to few months, and is mainly due to enzymatic activity in the matrix remodeling. Atrophic scars can occur as a result of inflammation (e.g. acne), surgical and accidental trauma, iatrogenic factors (e.g. steroids), abnormality of collagen synthesis due to deficiency of oxygen, vitamin c and other cofactors, and connective tissue disorders (morphea, scleroderma), and genetic disorders (e.g. chromosome 10 anomalies, xeroderma).⁽⁶⁾ Atrophic scars are commonly faced. The common feature of these scars is their bottom, which is located below the level of the surrounding tissue. The skin on the top of atrophic scars is thin and flaccid, with cross striation inherent in linear scar. Often such scars have pigment deficit and look white. The characteristic look of these scars is stipulated by connective tissue deficit, notably the deficit of collagen and elastin proteins that form the skin frame⁽⁷⁾. Atrophic (hypotrophic) scars present clinically as depressed, and typically hypo-pigmented, plaques. They are wide, and in extreme cases may approach the width of original excision⁽⁸⁾. In this study dermal tube technique first used by Mallucci et al. has been applied for the treatment of atrophic tethered scars⁽⁹⁾.

PATIENTS AND METHODS:

Between January 2017 to April 2018, 16 patients presented to us with atrophic tethered scars. Patients details are shown on table (1). All of them were treated surgically by using dermal tube technique. The exclusion criteria was: (Scars that had previous failed surgical interventions, Acne scars, Post burn scars and Scars in hairy areas). Pre-operative routine investigations were done. Photographs were taken preoperatively, and an informed consent was obtained from every patient. Our results were assessed subjectively depending on the clinical assessment and comparison between pre and postoperative photographs. Our evaluation was based on analysis of patient satisfaction using the visual analogue scale (VAS).

Also our overall satisfaction was considered in assessing the postoperative results.

Operative technique: pre-operative routine preparation was conducted. Twelve patients were operated under local anesthesia, while the other four patients were operated under general anesthesia. After prepping and draping, our operation started by marking an ellipse around the scar, the margins of the ellipse were drawn at the point where the scar depression begins. 2% xylocaine with 1:100,000 of adrenaline were infiltrated around and below the scar. The procedure was started by de-epithelialization of the ellipse using a number 15 scalpel. The de-epithelialization should be done so that no epidermis is left, thus preventing the formation of a keratin cyst. After the de-epithelialization was completed, an incision was made through the full thickness of the dermis around the de-epithelialized ellipse down to the subcutaneous fat, so that the edges of the dermis were completely released from their surroundings. Only minimal undermining was needed around the scar. After that, the edges of the central dermal island were brought together by suturing them with a continuous 4/0 PDS suture to construct a dermal tube at the center of the scar. Hemostasis was secured, the skin layers were closed above the dermal tube, first by dermal closure with interrupted 4/0 polyglycolic acid suture, and then the skin was closed with running-subcuticular 4/0 nylon suture. The wound was covered with antibiotic ointment and a dressing was applied. All the patients were discharged home on the same day of the operation and received oral antibiotics for 3 to 5 days postoperatively. The subcuticular suture were removed two weeks later. The patients were kept on a follow-up period of at least six months. Photographs were taken immediately postoperatively, after 1 month, and then after 6 months. The photos were compared with the preoperative photographs.

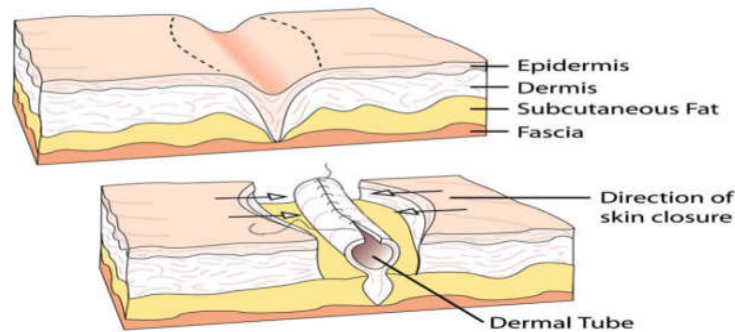


Figure (1) Schematic representation of the dermal tube ⁽¹³⁾

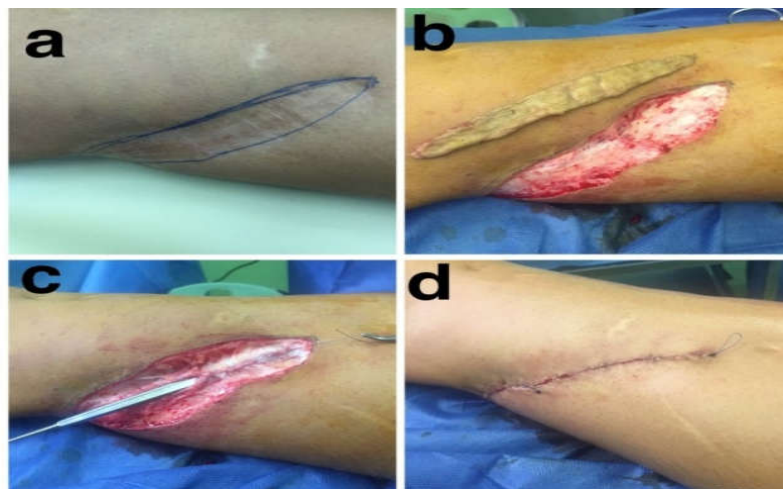

Figure (2): Operative steps in creating the dermal tube.

(a) Marking.

(b) Skin deepithelialization.

(c) The dermis is incised through its full thickness at the margins of the ellipse and the opposing dermal edges are sutured together to create the dermal tube.

(d) The skin is closed over the dermal tube.

RESULTS:

The patients' data are shown in table (1). The average value of the visual analogue scale was 7.8 as shown in table (2) with excellent improvement of the contour of the atrophic scar, and a near normal skin texture with no need for secondary revision or recurrence of the deformity during the follow up period. Three of our sixteen patients were unsatisfied with their results, and their (VAS) was 5.

Our assessment coincided with our patient judgment which was analysed using the (VAS) as mentioned above. No post-operative complications such as (wound infection, wound dehiscence, keloid scar formation at the site of the wound) were seen in all of our patients even in those who were not satisfied with their results.

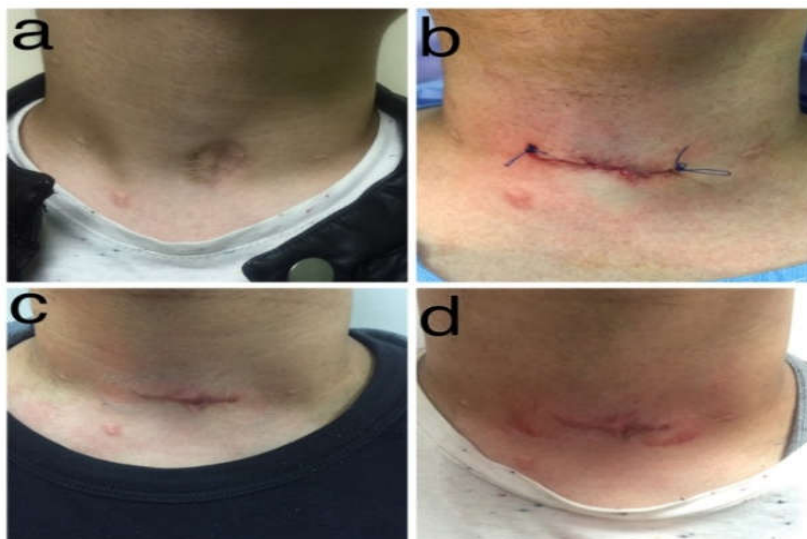ATROPHIC SCAR REVISION

Table (1) patients' data

Patient	Age	Sex	Site of scar	Cause of scar	Scar diameters Length/width
1	4 years	Female	Lt. lower abdomen	abdominal surgery	10 cm/4 cm
2	18 years	Female	Rt. buttock	Site of IM. Injection	8cm /3.4cm
3	24 years	Female	Lt. cheek	Poorly sutured wound	4 cm/ 1.4 cm
4	19 years	Female	Midline lower back	spinal surgery	14 cm/4 cm
5	17 years	Male	Rt. arm	Trauma	10/4cm
6	14 years	Male	Rt. leg	Trauma	11cm/3cm
7	25 years	Female	Lower abdomen	surgery	5cm/1.4cm
8	24 years	Male	Lt. forearm	Post fasciotomy	16/ 3cm
9	35 years	Male	Lt. lateral cheek	Trauma	6cm/ 1.3 cm
10	30 years	Male	Lt. distal forearm	surgical incision	5.5 cm/2.5 cm
11	40 years	Female	Anterior neck	Trauma	6cm/2.5 cm
12	16 years	Male	Anterior neck	tracheostomy scar	3cm/2.5cm
13	30 years	Male	Rt. cheek	leishmaniasis scar	3cm/1.8cm
14	25 years	Male	Rt. upper cheek	Trauma	3.2cm/1.7cm
15	30 years	Male	Rt. dorsal forearm	Trauma	4cm/2.4cm
16	23 years	Female	Lt. mandible line	leishmaniasis scar	4cm/2.1cm

Table (2): patients Satisfaction on Visual analogue scale.

Number of patients	Satisfaction on visual analogue scale
2 patients	10
4 patients	9
5 patients	8
2 patients	7
3 patients	5



Figure(3) :pre and post-operative photographs of a 16 years male patient with post tracheostomy scar of 4 years duration.

- (a) Pre-operative frontal view
- (b) Immediately post operatively.
- (c) After 3 months.
- (d) After 6 months'

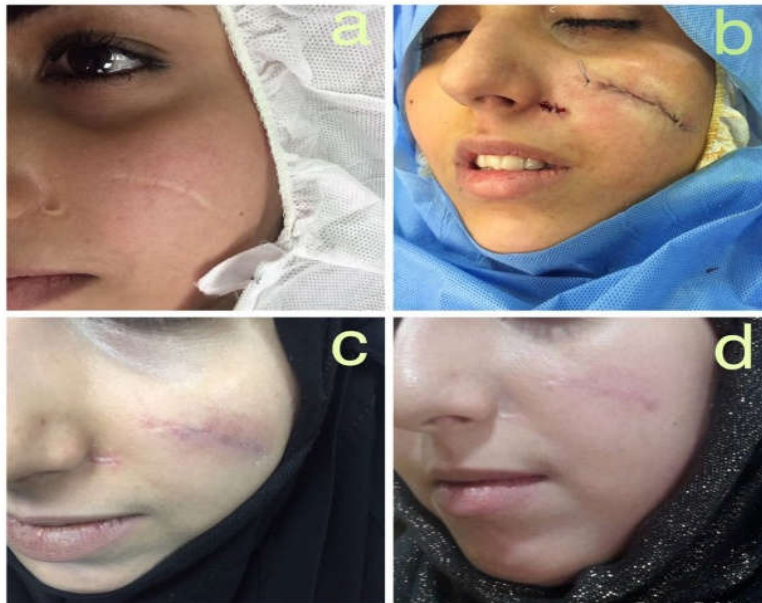

Figure (4): pre and post-operative photographs of a 24 years female patient with a facial scar of 5 years duration.

- (a) Pre-operative view.
- (b) Immediately post operatively.
- (c) After 3 months.
- (d) After 6 months

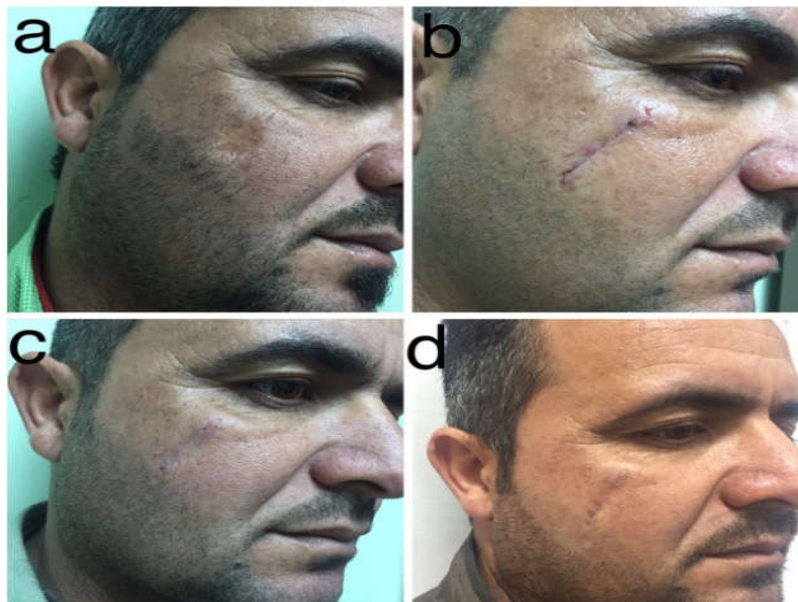


Figure (5): pre and post-operative photographs of a 30 years male patient with a facial scar of 2 years duration.

- (a) Pre-operative view.
- (b) 2 weeks post operatively.
- (c) After 3 months.
- (d) After 6 months'

DISCUSSION:

Scar formation is a consequent process to the healing of soft tissue after trauma. A cosmetically acceptable scar is often at the level of the surrounding skin, with good color match and narrow. Favorable lines of closure are usually within or parallel to the relaxed skin tension lines⁽¹⁰⁾. Changes in color, texture, elasticity, and uniformity of the skin surface, which occur in the presence of scars, affect the epidermis, dermis and hypodermis, in block or separately. These sites are therefore, the target for the proposed treatment⁽¹¹⁾. The most frequent cause of failure of scar revision lies in the unrealistic expectations on the part of the patient. Thus, each attempt at scar improvement must begin with an assessment of the patient's understanding and expectations of the likely results⁽¹²⁾. The overall results were satisfactory to us and to our patients in 13 cases as the scars have gained a good bulk with normal skin color and texture with no recurrence of the deformity during the follow up period which was 6 months. Three of our patients had unsatisfactory postoperative results with little improvement in the contour of the atrophic tethered scars. These patients had either a relatively deeper defect, which seemed that it was not possible to completely fill it by using the dermal tube or had a thin layer of subcutaneous fat in adequate to fill the defect completely others had developed stretching of the scar during the post-operative follow up period.

Those three patients were scheduled for other revision procedures together with our technique later on. Our results are generally in consistence with Mallucci et al.⁽⁹⁾. We used of the dermis of the scar as an auto-filler to the dead space and the depression of the atrophic scar, thus we obviating the need for grafting from another site. Releasing the dermis from its surrounding edges and keeping it attached to its base, this gave us a dual effect; one of these effects enabled us to release all the dermis tethered to the deep fascia; so, the tethered scar has been freed from its attachment, the other effect is to maintain vascularity. So, the volume has been restored and maintained to reduce the incidence of recurrence of tethered scar

Another advantage is that the fat on the under surface of the dermis was turned up so that it would form an intervening layer between the dermis of the closed skin edges and the base of the scar thus further preventing the re tethering and loss of volume. One of the causes of post-surgical incision atrophic scars is failure to approximate the subcutaneous tissue properly before suturing the skin. By using the dermal tube we also brought the two edges of the dermis together, with dermal tube that acts as interposition layer between the base of the scar and its overlying skin. Many of the scars have been re-orientated within or close to the skin lines which has been effective in improving the scar appearance. In this method minimal undermining was done, thus we reduced the incidence of dead space, hematoma, and possible infection. Various techniques have been used for the correction of atrophic tethered scars; among these techniques is the use of local flaps such as Z-plasty, W-plasty and M-plasty. Using these local flaps will necessitate additional incisions which is a drawback for the patient. Eliminating tethering and depression with minimal number of additional incisions should be aimed for in those patients⁽¹³⁾. In addition, the use of the aforementioned local flaps will not address the primary problem of atrophic scar which is volume deficiency and fibrous tethering to deep fascia. Dermal graft has been used for many years. In the past, surgeons have focused on its use in ophthalmology and defect correction in other organ systems⁽¹⁴⁾. The major drawback of the dermal graft is that it may not be a good solution to the treatment of large tethered atrophic scars in addition to the donor site morbidity, persistent epithelium, cyst formation and unpredictable behavior in addition to the technical difficulties that might be faced during the placement of the graft in the tunnel. De Benito et al. used autologous fat injection for the treatment of atrophic tethered scars⁽¹⁵⁾. The drawback of this method is related to the limited donor sites in slim patients, and the lower survival rates of fat graft which might require overcorrection or multiple sessions.

Using synthetic fillers have been found inappropriate for the management of large atrophic scars and it does not improve the skin texture in addition to the cost and the need for recurrent sessions. Subcutaneous incisions (subcision) surgery for the correction of depressed scars using Nokor needle is usually used for post acne scars, indrawn scars after deep destructive inflammation (chicken pox, furuncle, abscess), wrinkles of frontal and nasolabial areas and other retracted scars⁽¹⁰⁾. The aim of such method is to surgically release the skin from its under attachment and introduce a controlled trauma initiated wound healing with consequence formation of connective tissue that will augment the depressed site⁽¹⁶⁾. However this procedure cannot be applied to large scars and it carries a risk of complications such as, transection of vessels and nerves, pain in the interference area, inflammation and infection, post inflammatory hyper-pigmentation and even keloid formation. Thus the dermal tube technique is one of the effective options for the correction of atrophic and tethered scars in many patients either alone or combined with other techniques.

CONCLUSION AND RECOMMENDATION:

The dermal tube technique is a simple and single-stage operation that can be performed under local anesthesia, with optimal scar appearance and minimal recurrence of the deformity. However in deep scars other procedures might be needed together with this method for better scar improvement. Further studies are needed to establish the effectiveness of the dermal tube technique-for-deep-seated, tethered atrophic scars.

REFERENCES:

1. Shipa Garg ,Somesh Gupta . Surgical scars revision: An overview, *Journal of cutaneous and aesthetic surgery*,2014;7(1):3_13.
2. Stephen J. Mathes , Vincent R. Hentz . Mathes plastic surgery, 2nded. ,Saunders Elsevier, Philadelphia, vol. 1 ,2006; pp. 235.
3. Janine Ferguson. Scar revision roundtable . Available from: <http://www.plasticsurgerypractice.com/2010/07/scar-revision-round-table/>. [accessed 25 April]
4. Deepak M. Kalaskar, Peter E. Butler, Shadi Ghali . Textbook of plastic and reconstructive surgery, 1st.ed. ,UCL press ,London, 2016; pp.4.
5. Ross Dr. Farhadieh, Neil W. Bulstrode, Sabriana Cugno. Plastic and reconstructive surgery, 1st.ed. ,John Wiley and Sons ,Ltd. ,U.K.,2015; pp.4.
6. Alexander Chambers. Unified approach to the treatment of hypertrophic and atrophic scars: A pilot study. *The American journal of cosmetic surgery* ,2016;1-8
7. Igor Safonov. Atlas of scar treatment and correction, 1st.ed. , Springer, New York, 2012 ;pp.1.
8. Alexander Berlin. Mohs and Cutaneous surgery, 1st.ed. ,CRC press, New York, 2015;pp.91.
9. Patrick Malluci , Ahid Abood, Giovanni Bistoni. The dermal tube: a versatile tool in scar revision. *Journal of plastic, Reconstructive and aesthetic surgery*,2009;62:1223-1226.
10. Francesco Inchingolo et al. Surgical treatment of depressed scars: A simple technique, *Int. J. Med. Sci*, 2011; 8:377-379.
11. Emerson Vasconcelos de Andrade Lima .Dermal tunneling: a proposed treatment for depressed scar, *An Bras Dermatol* , 2016; 91(5) : 697-699.
12. Gregory S. Georgiade, Ronald Riefkohl, L. Scott Levin .Georgiade plastic , Maxillofacial and reconstructive surgery , 3rd ed. ,Williams and Wilkins , Philadelphia, 1997; pp. 114.
13. Ceran C, Aksam E, Cicek C, Tezcan S, Demirseren ME.A new technique for correction of tethered and depressed scars: layered dermal support , *Aesthetic plastic surgery*. Available from: www.springer.com/00266,2016.

14. Kanathur Shilpa et al. Outcome of dermal grafting in the management of atrophic facial scar. Journal of cutaneous and Aesthetic surgery , 2016;9: 244-248.
15. De Benito , Fernandez I , Nandu V . Treatment of depressed scars with dissenting cannula and an autologous fat graft, Aesthetic plastic surgery, 1999, 23: 367-379.
16. David S. Orentreich , Norman Orentreich. Subcutaneous incisions (subcision) surgery for the correction of depressed scars and wrinkles, Dermatol surgery, 1995;21: 543-549.