

Repair of Hypospadias Fistula Using a Penile Skin Advancement Flap with Penile Dartos Interposition

Ahmed Salam Ridha , Yasir Naif Qassim

ABSTRACT:

BACKGROUND:

Presence of various techniques in hypospadias repair is attributed to the relatively common complications following those repairs which shown as an immediate and long term complication. Urethrocuteaneous fistula is the commonest complication of the hypospadias repair , with a reported incidence of 4-25%. The incidence is varying with severity of hypospadias, surgical techniques, and experience of the operating surgeon.

OBJECTIVE:

To evaluate the efficacy of using a penile skin advancement flap with penile dartos Interposition to repair hypospadias fistula.

PATIENTS AND METHODS:

Between October 2017 and March 2018, eleven boys with urethrocuteaneous fistula were included in this study. Their age ranged between (3 years – 10 years) . All were repaired with penile skin advancement flap with dartos fascia as an interposed reinforcing layer in Al shaheed Ghazi Al- Hariri hospital and Alwasity teaching hospital .

RESULTS:

Most of the patients showed no recurrence of fistulae after repair during follow up period which extended for about 6 months postoperatively. Those pati-ents had good urine stream and straight penis on erection without any torsion or deviation. No major complications were seen in all of these patients.

CONCLUSION:

The penile skin advancement flap with interposition dartos is simple procedure which can be used for surgical treatment of primary posthypospadias fistula of any size, site provided that there is adequate pliable durable penile skin .

KEYWORDS: urethrocuteaneous fistula, dartos fascia, advancement

INTRODUCTION:

One of the most common congenital anomalies is hypospadias, it had concerns because of aesthetic deformities that are associated with it in addition to parent insecurity about the fertility of their child.^(1,2) There are various methods for hypospadias repair all of them are around to have cosmetically acceptable shaft with normally located meatus, together with straight penis and straight stream^(3,4) However, hypospadias surgery is associated with many complications, the commonest of these complications is urethra cutaneous fistula that has 4-25% incidence depending on the surgical technique and severity of the hypospadias and experiences of the surgeon^(5,6)

Many factors may play role in fistula formation post hypospadias repair these including

aggressive and rough tissue handling , using of poorly vascularized tissue, suture size and type, finally infection and stenosis had also role in fistula formation.⁷

There are many surgical steps that may reduce incidence of fistula formation those are using of coverage barrier flap to close the urethra , using of fibrin sealant over the urethra. ⁸

Urethrocuteaneous fistula can be spontaneously closed by itself in 30 % of cases when it is small size i.e. less than 2 mm. most of the small fistula can be treated with simple excision with using adjacent subcutaneous layer as intervening coverage , skin flap can be sued for large fistula provided that there is adequate and pliable tissue, in those cases where the local tissue are deficient or had no adequate blood supply, in such condition extra genital graft is usually required^{9,10,11,12}

Al Shaheed Ghazi Al-Hariri Hospital for Specialized Surgeries, Baghdad/ Iraq

REPAIR HYPOSPADIAS FISTULA

In this study penile skin advancement flap with penile dartos interposition had being used for management of the post hypospadias repair fistula.

PATIENTS AND METHODS:

Patients:

Between October 2017 and March 2018 eleven boys with urethrocutaneous fistula were included in this study. Their age ranged between (3 years – 10 years) . all were repaired with penile skin advancement flap with dartos fascia as an interposed reinforcing layer in Al shaheed Ghazi Al Hariri hospital and Alwasity teaching hospital .

All patient were subject to routine preoperative investigations and radiological evaluation.

Photographic documentation was adopted for all patients.

Ketoconazole (3.3-6.6)mg/kg was prescribed for all patients 5 days prior to the day of surgery and continued for 5 postoperative days to minimize the effect of erection.

Surgical technique

All patients were operated upon under general anesthesia in supine positing with endotracheal entubation , once sterilization and draping achieved fistula size was measured in anteroposterior length of the penis.

A traction suture was inserted to the glans using 3/0 silk suture, followed by urethral calibration with urethral sound rolling out any distal stenosis. Silicone foley's of (8 – 14 Fr) catheter inserted.

Using methylene blue all proposed markings were done, circum-ferentially around the fistula , laterally base rectangular flap of base width ranged(1.5 – 3) cm according to fistula size, a contralateral incision was made for better exposure of dartos fascia . flap is designed so its upper border is tangential with fistula. As shown in figure (1) A. 2%xylocain with 1:80000 adrenaline was infiltrated to the area to secure hemostasis ,circumferential incision around the fistula with no 15 blade was done, then the incision is deepened till the level of dartos fascia. A fine scissors then used to undermine the fistula edges dissecting them off the surrounding tissue down to the healthy urethral one.

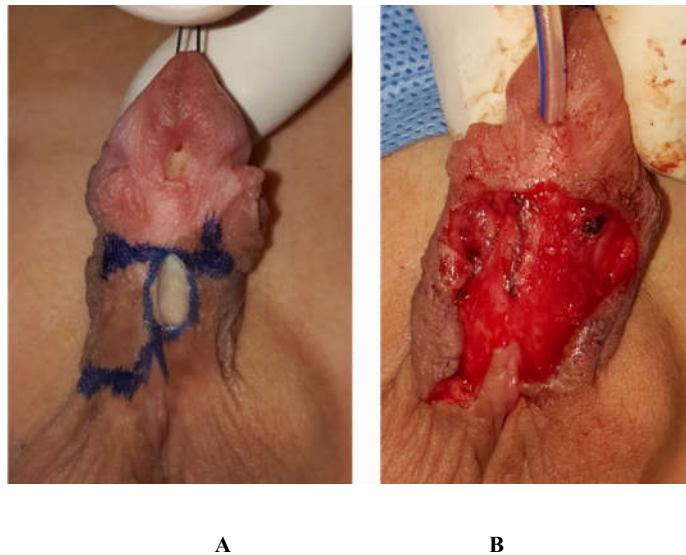


Figure (1) showing surgical technique; A: marking, B: fistula closure

REPAIR HYPOSPADIAS FISTULA

After trimming of the skin epithelium the edges inverted with continuous subepithelial suture closing the fistula as a first layer with 6/0 polygalctin suture material.as shown in figure (1) B. Hemostasis achieved using bipolar cautery.

A laterally based rectangular flap of penile skin then raised exposing the dartos fascia. As shown in figure (2) A. A blunt scissors used to raise penile dartos fascia flap off the inferolateral aspect of the penile shaft opposite to the site of the penile skin advancement flap. As shown in figure (2) B.

The penile dartos flap is sutured in place as a reinforcing intermediate layer (second layer) over the repaired fistula with 6/0 polyglactine suture in a simple interpreted manner. the penile skin flap then advanced covering penile dartos fascia so that the skin redrapped covering the repaired fistula site (third layer) with 4/0 polygalictine . No drain was used in all of our cases. As shown in figure (2) C.

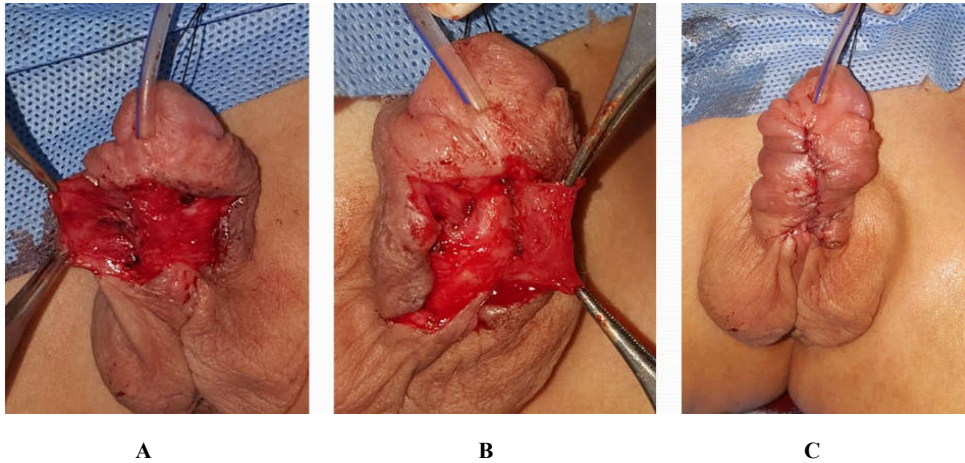


Figure (2) showing surgical technique continued ;A: rectangular flap raised, B: Dartos fascia flap raised from opposite site, C: immediate postoperative closure.

Antibiotic impregnated gauze was wrapped around the penile shaft as a first dressing layer. The second dressing layer was dry gauze fixed in place with adhesive surgical tape.

Postoperatively Patients were kept on injectable first generation cephalosprine antibiotics for the first 5 days and continued on oral antibiotic till the time of removal of catheter which was done 14 days postoperatively. Patient are discharged the next day after dressing change and wound being inspected.

All of the patients were kept on regular follow up visits weekly for the first month , every other week for the second month and once monthly up to 6 months postoperatively and they were all instructed to keep dilatation of urethra using a thermometer for 6 months follow up period with xylocain gel for lubrication .

REPAIR HYPOSPADIAS FISTULA

RESULTS:

In this study 11 patients aged (3 – 10) years whose data shown in table (1) were subjected to surgical treatment of their fistulae by using penile skin advancement flap with penile dartos interposition. Nine out of eleven patients showed no recurrence of fistulae after repair during follow up period which extended for about 6 months postoperatively. Those nine patients had good urine stream, and straight penis on erection without any torsion or deviation. Two of our patients developed recurrence that is noticed

at the time of removal of the urinary catheter those two patients were scheduled for another operation for fistula repair.

No major complications were seen in all of our successfully treated patients (nine patients) apart from mild skin infection which was seen in one patient and it was treated conservatively without affecting the final result. One of the patients had developed mild scrotal hematoma which then resolved spontaneously.

Table 1: patients data

Pt. no	Age	Site of fistula	Size of fistula	Type of previous hypospadias repair	Previous fistula repair
1	3 years	Midshaft	2 mm	Tubularized incised plate	First time
2	3.5 years	Midshaft	2mm	Tubularized incised plate	First time
3	4 years	Midshaft	3.5 mm	Tubularized incised plate	First time
4	3 years	Coronal	3 mm	Tubularized incised plate	First time
5	5 years	Coronal	4 mm	Tubularized incised plate	First time
6	3 years	Midshaft	3 mm	Unknown	First time
7	5 years	Penoscrotal	6 mm	Multistage repair with skin graft	2 times
8	6 years	Proximal shaft	6 mm	Multistage repair with skin graft	First time
9	8 years	Midshaft	3.5 mm	3 rd stage hypospadias fistula closure	First time
10	4.5 years	Penoscrotal	12 mm	3 rd stage hypospadias fistula closure	First time
11	10 years	Proximal shaft	6 mm	Multiple stage repair with buccal mucosa	2 times

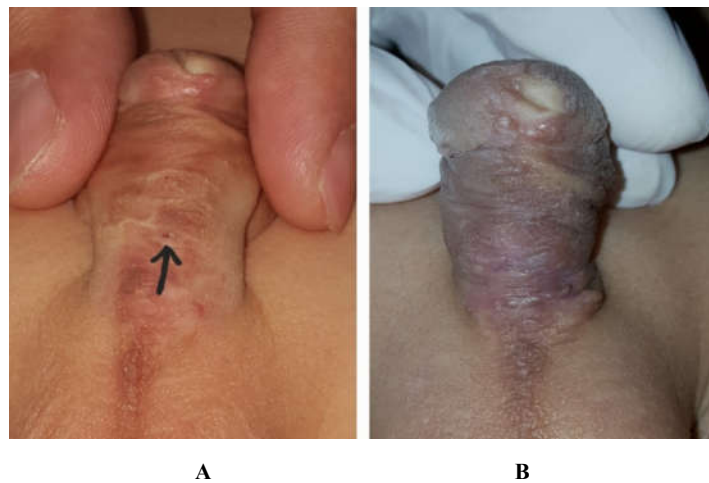


Figure (3) showing case number 2; A: preoperative picture and B: 3 months postoperative picture

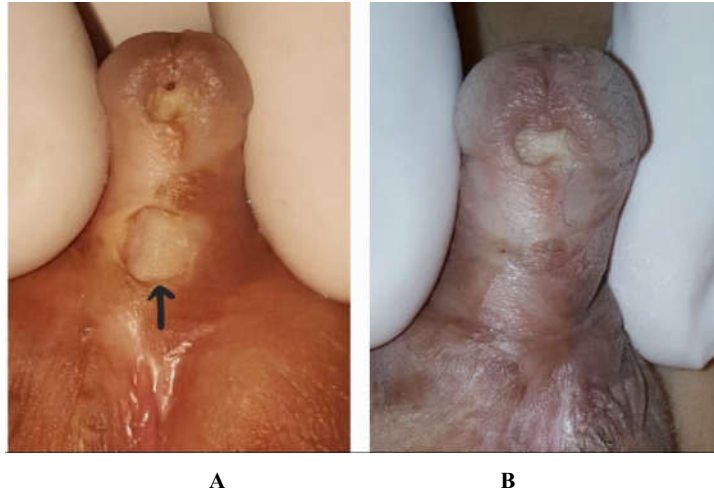


Figure (4) showing case number 8; A: preoperative picture B: 4 months postoperative picture

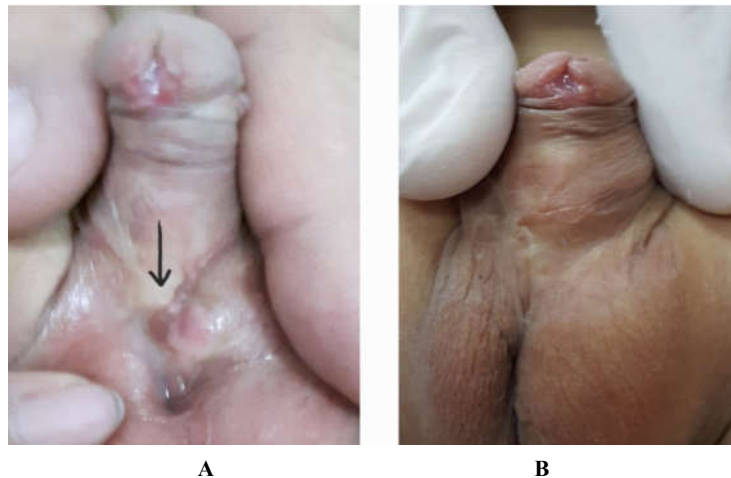


Figure (5) showing case number 10; A: preoperative picture B: 8 months postoperative picture

DISCUSSION:

Despite the advance in urethroplasty techniques, certain complications remain problematic in the modern hypospadiology namely, meatal stenosis, urethral stricture or diverticulum, wound dehiscence, and perhaps most important urethrocutaneous fistula.⁽¹³⁾

As with initial hypospadias repair, there is no perfect standards fom repairing urethrocutaneous fistula due to the influence of many factors like the size, site, and number of these fistulae, hence no matter how well designed the initial hypospadias repair procedure, how gently tissue are handled and how expertly the procedure is done.

Urethrocutaneous fistula remains a first rating problem to the reconstructive surgery. However, with the improvement of surgical techniques and suture materials, this complication is diminishing.⁽⁹⁾

Repair of fistula by excision and simple closure is one of simple surgical modalities that can be adopted in small sized fistula (≤ 2 mm)⁽⁹⁾. Although the success rate is acceptable, Holland et al reported that the risk of recurrence is still high.⁽¹⁴⁾ This risk is noted even in small sized fistulae.⁽¹⁵⁾

Hence, it can be stated that repairing a urethrocutaneous fistula by simple closure is strictly limited to those patients with small fistula size and those who have pliable tissues otherwise using multilayered repair technique is mandatory.

In clinical practice, multilayered repair using tissue interposition between neourethra (first layer) and skin is effective in decreasing the incidence of urethrocutaneous fistula⁽¹⁶⁾

Dartos flap has the widest application as an interposing reinforcing layer^(17,18,19)

A.G. Nelson et al used penile skin advancement flap with penile dartos interposition for repairing urethrocutaneous fistula in 20 patients with median follow up period of 4 months; all of their patients were successfully repaired. Our results go with these results although we have two patients with unsuccessful repair.⁽²⁰⁾

Deepithelialized turnover flap (dermal dartos flap) was used by Ahuja to repair ten patients with urethrocutaneous fistula. Nine of them healed without complications and only one patient suffered pin point fistula that was closed spontaneously.

These results were promising apart from a problem of hair being buried when dealing with fistulae at the penoscrotal area while our technique does not have this problem.⁽¹¹⁾

Similarly tunica vaginalis flap^(21,22) provide additional layer of repair, but its use has some limitations, its proximal extent provides some difficulty to obtain long pedicle to address distal shaft fistula and this shortage in length can provide secondary chordee. Besides that, if cremasteric fibers are included with the flap, penile torque can occur.^(17,22)

Hence we can state that this technique of using the dartos fascia as interposing reinforcing layer seems to be acceptable and effective. However, larger series of patients and longer period of follow up are required to accurately prove these results.

CONCLUSION AND RECOMMENDATIONS:

The penile skin advancement flap with interposition dartos is simple procedure which can be used for surgical treatment of primary post-hypo-spadias fistula of any size, site provided that there is adequate pliable durable penile skin i.e. it is not suitable for crippled hypospadias patient. It is recommended that larger series of patients and longer period of follow up are required to accurately prove these results.

REFERENCES:

1. Stephen J Mathes. Mathes plastic surgery, 2nd ed. , vol 6, Saunders Elsevier, USA, 2006; pp 1259.
2. Charles H. Thorne. Grabb and Smith's plastic surgery , 5th ed. . Lippincott. Raven . Philadelphia, New York , USA, 1997; pp. 1101.
3. Daneil Yachia. Text Atals of penile surgery, 1st ed., informa healthcare , UK . 2007 ; pp. 84.
4. Donald Serafin, Nicholas G. Georgiade. Pediatric plastic surgery , 1st ed. , vol 2 , C. V. mosby company , st. Louis , USA , 1984; PP 950.
5. Belman AB. The de-epithelialized flap and its influence on hypospadias repair. J. Urol, 1994; 152 : 2332 – 4.
6. Dodson L. et al. outcomes of delayed hypospadias repair. Implication for decision making. urology, 2007; 11 (178); 278 – 281.
7. A. T. Hadidi , A F. Azmy . Hypospadias surgery: An illustrated Guide , 1st ed., springer , New York, USA , 2004; pp 63, 277, 278.
8. Louis R. Kavoussi , Andrew C. Novick, Alan W. Partin, and Craig A Peters. Campell – Walsh urology, Tenth ed., Elsevier Saunders, Philadelphia , USA . 2012; pp. 65 , 3526.
9. Rajat Kumar Srivatava, Manges S tandale, Nikhil Panse, Anubhav Gupta, Pawan Sahane. Management of urethrocutaneous fistula after hypospadias surgery: An experience of thirty-five cases, indian j plast surg. 2011; 44(1): 98-103.
10. Alan B. Retik, Anthony Atala. Complications of hypospadias repair, Urol clin N Am, 2002; 29: 329-339.

11. Kiss A , Pivot L. Karszal L. , Merks M. use of buccal mucosa patch graft for recurrent large urethrocaneous fistula after hypospadias repair, *urologia internatinlis*, 2004 ; 4(72): 329 -331
12. Kvopfi D, Tucak A, Prolic D. and Vermegen, A suing buccal mucosa for urethral reconstruction in primary and reoperative surgery , *Eur UROL*, 1998; 34: 216.
13. Ashutosh Soni , San Jay Sheoran . Repair of large urethrocutaneous fistula with dartos based flip flap : A study of 23 case , *Indian J . Plastic surgery* , 2007 ; 40: 34 – 38
14. Kaliyaperumal Muruganndham et al, urethrocutaneous fistula after hypospadias repair : outcome of three type of closure technique *pediatr surg Int*, 2010; 26: 305 – 308.
15. Jalil Hosseini et al , fistula repair after hypospadias surgery using buccal mucaosal graft , *urology journal* 2009; 6 (1) : 19 – 22.
16. Yasir S, Mazen o, Sbah S. Management of small urethrocutaneous fistula by tight ligation with fulguration of external epithelium of tract, *Annals of pediatric surgery*, 2010; 6: 150- 153.
17. Shogo S , Takanori O , Yuta Y , Manabu D, Go M , Hiroyuki K , Geofferey J , Astuyuki Y. Soft tissue interposition is effective for protecting the neourethra during hypospadias surgery and preventing postoperative urethrocutaneous fistula: a single surgeon's experience of 243 cases. *Pediatr surg Int* 2015.
18. Bernard M , John G , Antoin E , Gordon A. The dartos flap as an adjunct in prevention urethrocutaneous fistula in hypospadias surgery. *TJU* 1996;156:2047-2049.
19. Vedat B , Abdulla Y. Dorsal double layer dartos flap for preventing fistulae formation in the Snodgrass technique. *Urol Int* 2007;78:241-244.
20. A. G. Neilson , G. Nicholls . Repair of hypospadias fistula using penile skin advancement flap with penile dartos interposition , *journal of pediatric urology* , 2013; 9: 890- 984.
21. Kamyar T , Shabnam M. Tunica vaginalis flap as a second layer for tabularized incised plate urethroplasty. *URol J* 2010;7254-257.
22. Jonathan C. Routh, James J. Wolpert and Yuri Reinberg. Tunneled tunica vaginalis flap for recurrent urethrocutaneous fistula . *Advances in urology*, 2008, pp 1-3.