

## The significance of neutral zone technique on complete denture retention

Nadira A HATIM\*

### ABSTRACT

The aims of this study are to evaluate retention, differences between the level of occlusal plane, and patient's response to esthetic, speech, and masticatory efficiency, in patients using two sets of complete dentures [blind treatment] for one month, one was constructed in natural zone (neutral zone technique), and the other in conventional technique.

Twenty-five completely edentulous patients, with age range (55-70) years were selected clinically with special criteria.

Measurements of load required to dislodge (100) dentures were done using load apparatus. The levels of occlusal plane of (50) mandibular dentures were measured by using digital vernea.

Results of mean square analysis of the neutral zone technique showed highly significant differences at (1%) level, the load required to dislodge mandibular denture done by the neutral zone technique was higher than that done by conventional technique (415.32gm).

The differences between the level of occlusal plane done in both techniques ranged between (2.22mm and 2.47mm).

The blind trial of treatment done showed (92-100%) acceptance with complete dentures done by neutral zone technique.

This technique helps dentists, patients, and technicians to solve problems of sever resorption of alveolar bone, by increasing retention, stability, masticatory function, esthetic value, simplicity of construction, and time saving.

**Key Words:** Neutral zone, retention, impression technique.

### الخلاصة

الهدف من هذه الدراسة هو تقييم نسبة الثبات، الدروقات بين مستوى الإطباق، استجابة المريض للناحية الجمالية، النطق، كفاءة المصنع، والفترة القياسية لإنجاز طقم الأسنان التي تم صنعها بطريقتين، الأولى بالطريقة التقليدية، والثانية بطريقة المنطقة المحايدة.

تم اختيار (٢٥) مريضاً تتراوح أعمارهم بين (٥٥-٧٠) سنة و بمواصفات خاصة لهذه الدراسة. إن قياس القوة المطلوبة لبيان نسبة ثبات مائة طقم أسنان قد تمت باستخدام جهاز خاص لقياس القوة. حيث كانت القوة المطلوبة لإزاحة الطقم المصنع بطريقة المنطقة المحايدة أكبر من القوة المطلوبة لإزاحة الطقم المصنع بالطريقة التقليدية بمقدار (٤١٥,٣٢ غم).

تبين من الدراسة الإحصائية وجود فرق معنوي عند مستوى (١%) بين الطقم المصنعة بطريقة المنطقة المحايدة والمصنعة بالطريقة التقليدية. كما أظهرت النتائج بأن ارتفاع مستوى الإطباق يتراوح بين (٢,٢٢-٢,٤٧ ملم) في منطقة الأسنان الخلفية. بعد استخدام الطقم لمدة شهر واحد أبدى المرضى ارتياحهم بنسبة (٩٢-١٠٠%) للطقم المصنعة بطريقة المنطقة المحايدة.

\*Nadira Abdul-Ridha HATIM; BDS, MSc: Assistant Prof. Department of Prosthetic Dentistry, College of Dentistry, University of Mosul, Mosul, IRAQ.



إن تصنيع الطقم بطريقة المنطق المحايدة تساعد طبيب الأسنان، المريض، وتقني صناعة الأسنان، للتغلب على مشكلة الضمور الشديد لعظم الفك بزيادة الثبات، الاستقرار، كفاءة المضغ، القيمة الجمالية، وتبسيط خطوات تصنيع الطقم، وأخيرا وليس آخرا تقليص الزمن.

## INTRODUCTION

One of the important objectives of complete denture is to give a retentive stable denture that meets the esthetic requirements and provides sufficient masticatory efficiency.

In order to achieve these points, the stability and retention of complete denture should be properly established, especially in severe residual maxillary and mandibular ridge resorption that ends with reduced denture-bearing area. So we must consider the followings<sup>(1,2,3)</sup>: -

### 1. Denture space:

Is the space between and around the residual ridges that is available for dentures<sup>(4)</sup>. This space has the possibility to decrease due to increase in tongue size in edentulous patient without prosthesis.

### 2. Denture surfaces are: -

- A-Occlusal surface.
- B-Impression or tissue surface.
- C-Polished surface.

The anatomy and physiology of the soft tissue boundaries will affect the form, and shape of the polished surfaces.

### 3. The influence of muscle force on denture surfaces<sup>(5)</sup>.

### 4. Orientation of the occlusal plane.

### 5. Leverage and posterior teeth position.

So when the patient is edentulous, it is not always easy to determine where the natural teeth were in relation to the partially or totally resorbed alveolar ridge<sup>(6,7)</sup>. In order to apply these points clinically, we should construct complete dentures for severe resorbed residual ridges in natural zone (The potential space between the lips and cheeks on one side and the tongue on the other. Natural or artificial teeth in this zone are subject to equal and opposite forces from the surrounding musculature).

The aims of this study are:

- To construct two set of complete dentures, one by natural zone (neutral zone technique) and the other by conventional method to evaluate the followings:
- The retention of complete dentures constructed in neutral zone and conventional technique.
- The differences between the level of occlusal plane done according to ala tragus line and that done according to the line drawn on the mounting stone in the neutral zone.
- Patient's response to the esthetic, speech, and masticatory efficiency.



following criteria: -

1. Advanced maxillary and mandibular ridge resorption (figure 1).
2. No complain of any systemic disease.
3. Patients were wearing complete dentures for at least (5) years.
4. Absence of temporo-mandibular joint symptoms, and have a neutral joint relation.

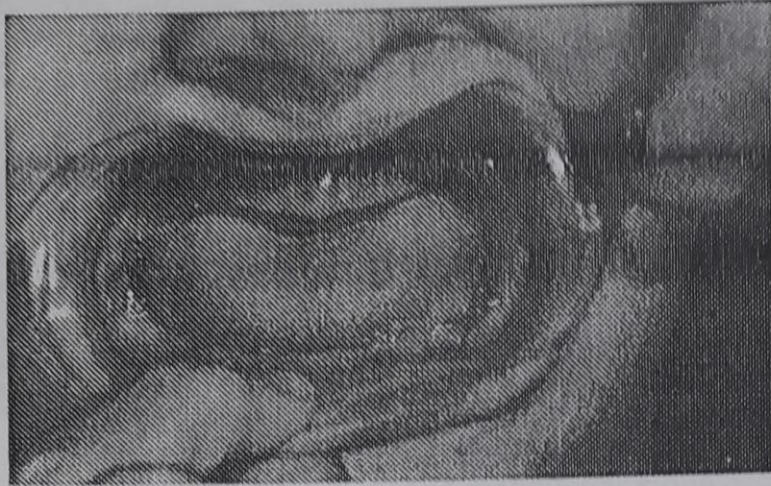


Figure (1): Severe resorption of maxillary and mandibular arches

A total of (100) complete maxillary and mandibular dentures were constructed, (for each patient one set of complete denture done by conventional technique, and the other by neutral zone technique using the same shade and mold set of teeth).

### Procedure

Diagnostic casts were prepared for each patient to construct maxillary and mandibular closely fitted record bases.

Final impressions of the maxillary and mandibular arches were taken in open mouth technique using light body silicone (Dorisil) impression material.

Vertical and horizontal relations were recorded in the conventional method after preparing the bite rim on the same record bases, then the anterior labio-lingual width of bite rim was reduced to (2) mm, while posteriorly bucco-lingual width to (3) mm. A notch of (V) shape was prepared at the premolar region on both sides of the bite rim, for injection of material and escapement of the excess of impression material. The surfaces of the bite rims were coated with an adhesive, after which a thin layer of alginate impression material was applied to the labial, buccal, and lingual surfaces.

Record bases with the materials were replaced in patient's mouth, and an alginate impression material was injected to the lingual, buccal, and labial sides respectively by dental syringe to produce impression in neutral zone.

The patient was instructed to exercise movements of the lip, cheeks, and tongue. The tongue was raised to touch the anterior part of the palatal area. The patient was instructed to do a sucking action in order to apply maximum pressure from the lip, cheek, and tongue (figure 2).



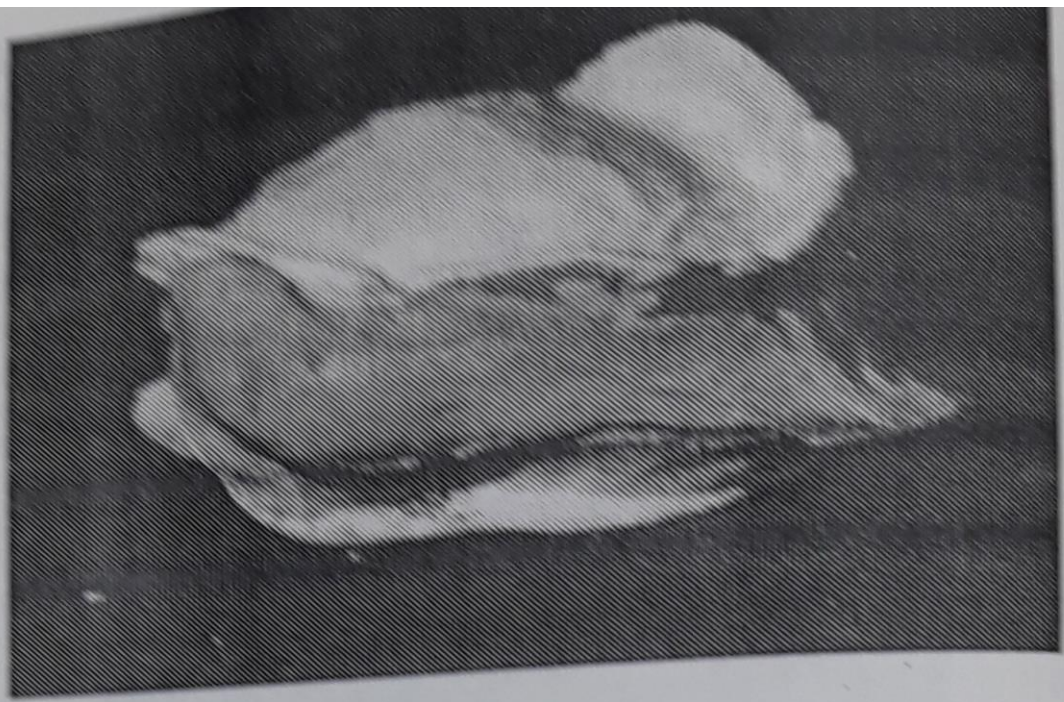


Figure (2): Impression of the upper and lower arches with impression in neutral zone

The upper and lower impressions were poured with stone material (Silky rock stone material). The impression of the neutral zone was cast in sections (Lingual right and left, buccal side right and left, and labial parts) by using stone gypsum material to fabricate guide stone parts (figure 3). The maxillary and mandibular stone casts, and the guide stone cast parts of neutral zone impression were mounted on semi-adjustable articulator.

For each patient, two sets of complete dentures were made, one by the conventional technique and the other by neutral zone technique after duplication of the maxillary and mandibular stone casts, and construction of special guide of maxillo-mandibular records was made from auto-polymerizing acrylic resin. The duplicated casts, the guide of vertical and horizontal relation were mounted on another articulator to construct maxillary and mandibular dentures in the conventional method.





Figure (3): A-Maxillary and mandibular stone casts with the guide parts of the impression in neutral zone

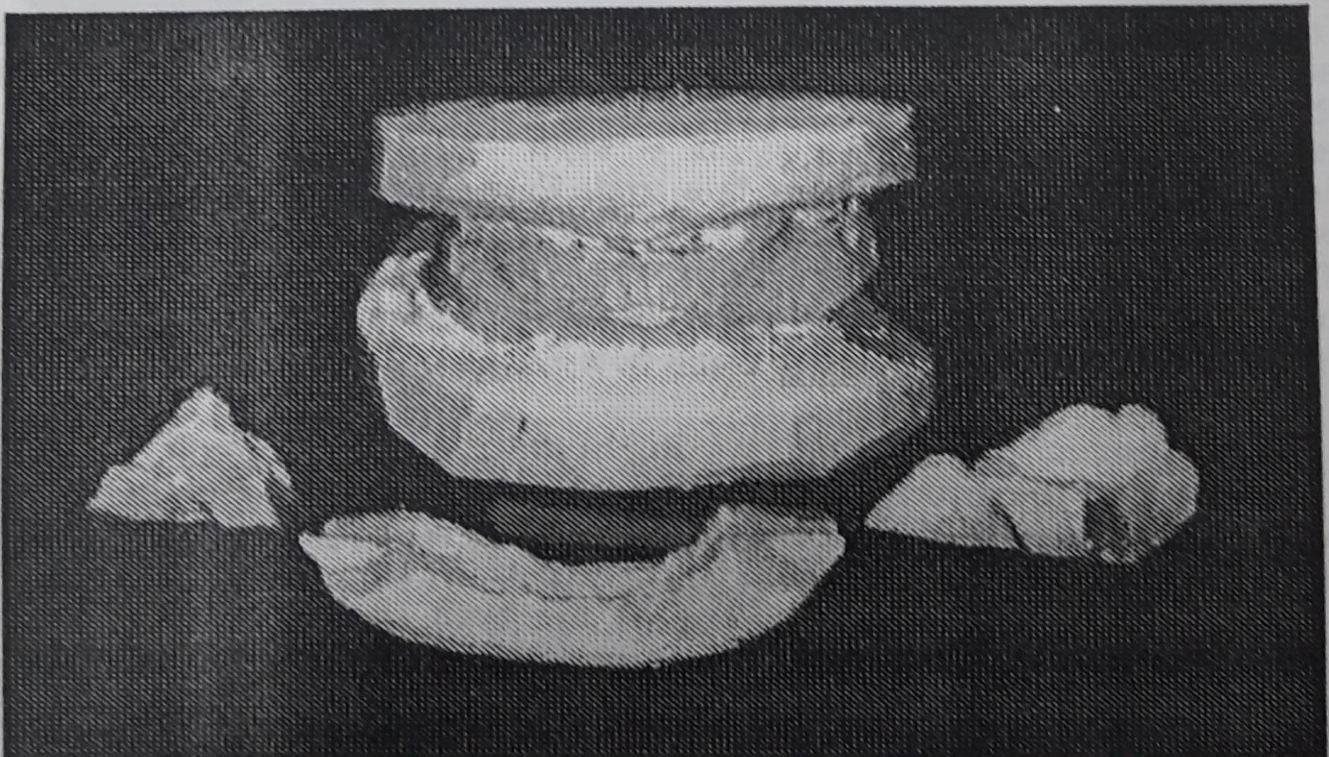


Figure (3): B-Guide stone parts of impression in neutral zone were opened.



A black automatic pencil with (0.3) mm tip was used to demarcate the level of the occlusal plane shown on the stone cast guide parts (buccal and lingual), which represents the medial fibers of buccinator muscle and lateral border of the tongue<sup>(8)</sup>. Then arrangement of mandibular teeth was done in neutral zone according to this line. Then the maxillary teeth were arranged according to the mandibular teeth (figure 4).

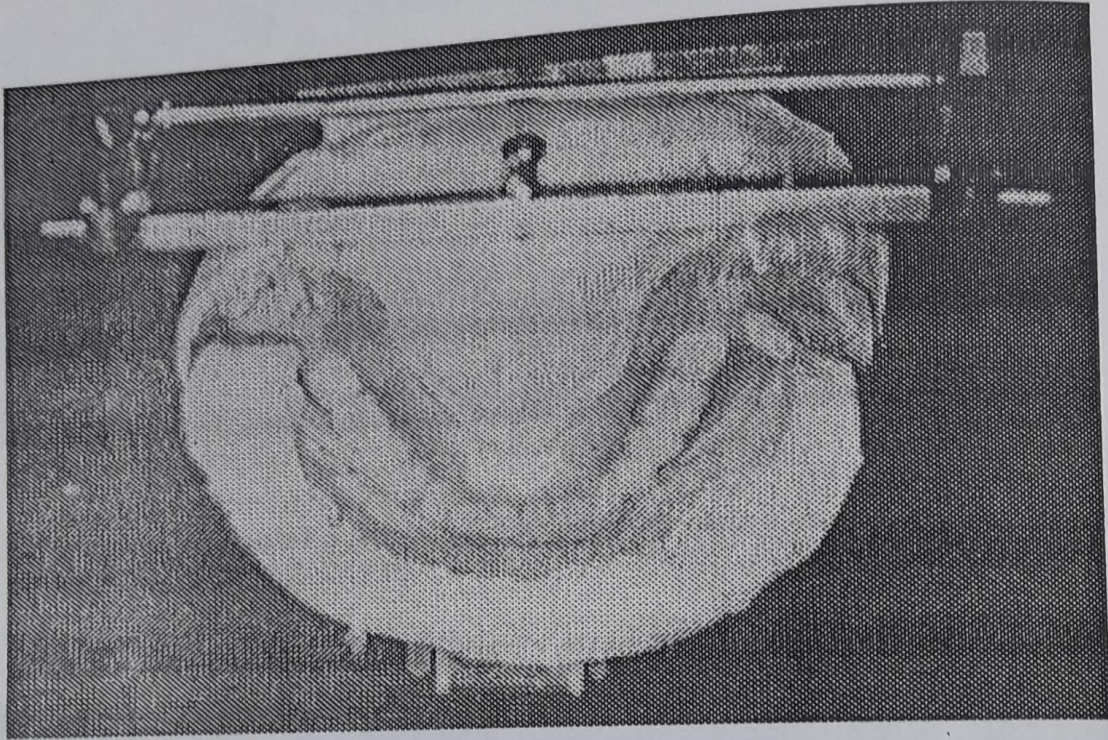


Figure (4): Arrangement of lower set of teeth in the neutral zone

Arrangement of teeth and waxing of the other set of complete dentures were done according to the principles<sup>(9)</sup>. Thickness of labial, buccal, and lingual flanges of denture done in the neutral zone impression method was adjusted with wax according to the space available for this purpose by guide parts of stone cast.

The level of the occlusal plane of the both sets of complete dentures was examined by using the mandibular dentures, and the guide stone cast pieces (buccal and lingual parts) to find the coincidence between the level of the plane done in the neutral zone in relation to that done in the conventional technique.

The vertical distance from cusp tip of first premolar, and mesio-buccal cusp tip of first molar to the periphery of the buccal flange of both mandibular dentures was measured by using digital vernia to (0.01) mm.



## Retention Measurements

Denture retention measurements of (100) complete maxillary and mandibular dentures were made (1) week after denture placement by using steel arc, denture attachment, and retention apparatus <sup>(10)</sup>, small metal pieces (0.25 +/-0.05gm) were used to measure the load required to dislodge the dentures.

The retention measurements of the mandibular dentures were made using steel arc denture attachment apparatus, and the load applied directly without using loading apparatus. The weight of metal pieces was calculated using electronic balance (Mettler, West Germany) to (0.001) gm.

For each denture, six trials were made to measure the dislodging force.

Each patient used two sets of maxillary and mandibular complete dentures in single blind trial for one month to evaluate the efficiency of the prosthesis in speech, mastication, deglutition and esthetic acceptance through the answers by yes or no <sup>(11)</sup>.

## RESULTS AND DISCUSSION

The results of this study were calculated and statistically analyzed, mean and standard deviation were tabulated in tables (1 and 2).

The results of retention measurement showed that there was a difference between retention of the maxillary denture done by neutral zone in relation to that done in the conventional technique (264.56 gm.), while in the mandibular dentures the differences in the load required to dislodge dentures was higher than that of maxillary arch about (415.32 gm.) in sever alveolar bone resorption cases. This is due to fullness of vestibule, stability of denture, and sealed periphery <sup>(1,7,12)</sup> (figure 5).

In order to test whether there is any significant differences between these variables (sex, technique, and maxillary and mandibular dentures), the analysis of variance procedure at (1%) and (5%) were done, and mean square analyses were listed in tables (3 and 4), and figure (6), which showed highly significant differences at levels of (1%) and (5%). This is due to construction of dentures in neutral zone concept, that help to have denture molded into a physiologic tooth arrangement <sup>(13, 14)</sup>.

Table (1): Mean and standard deviation of retention of denture in conventional technique

Prosthesis	Sample	Conventional Technique			
		Mean (gm.)	S.D.	Minimum (gm.)	Maximum (gm.)
Maxillary	25	902.52	71.7519	760.02	1000.5
Mandibular	25	674.72	133.110	431.25	900.22



Table (2): Mean and standard deviation of retention of denture in neutral zone technique

Prosthesis	Sample	Neutral Zone Technique			
		Mean (gm.)	SD	Minimum (gm.)	Maximum (gm.)
Maxillary	25	1167.16	137.857	955	1332.25
Mandibular	25	1090.04	144.2436	871.2	1321.5

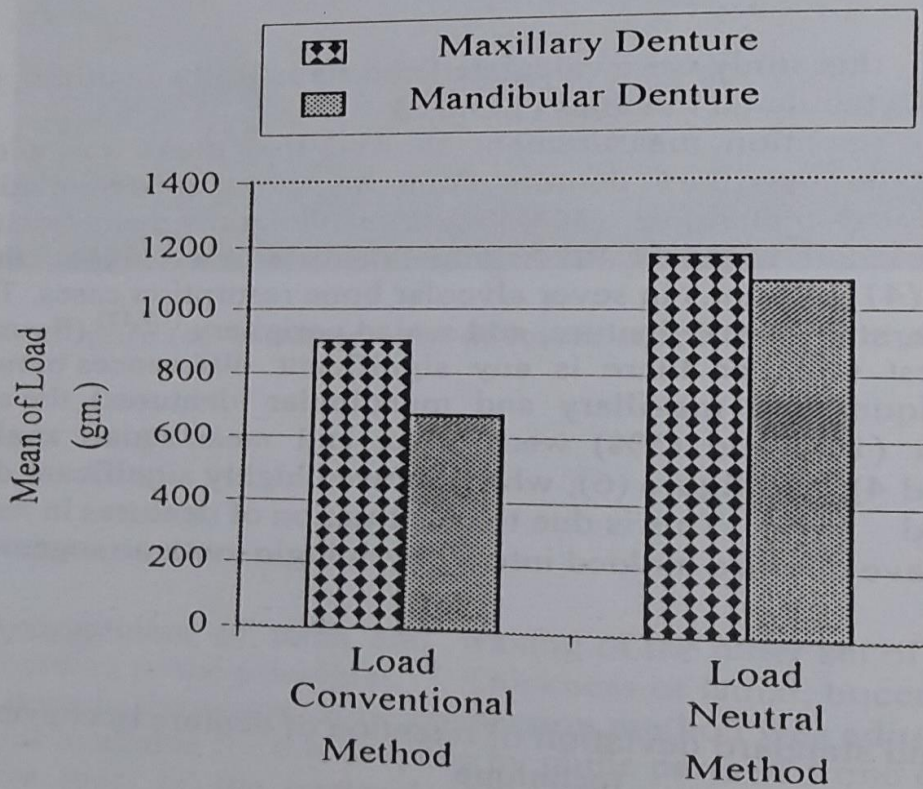


Figure (5): Load required to dislodge dentures constructed in neutral zone and conventional methods



The results showed that there was no coincidence between the two lines which represent the level of occlusal plane of the mandibular teeth drawn on the buccal and lingual mounting stone pieces. The line of the occlusal plane of conventional technique was higher than that of neutral zone technique in premolar region (2.22mm.), and molar region about (2.47mm.) (table 5).

Table (3): Mean square analysis of measurements of load required to dislodge maxillary denture according to sex, and technique

S.O.V.	d.f.	M.S.	F	p value	
Between load required to dislodge denture of conventional and neutral zone techniques	Female (Maxillary Denture)	20	171072.7	38.22831	HS
	Male (Maxillary Denture)	26	7808902	294.1432	HS
	Female (Mandibular Denture)	20	1084470	107.115	HS
	Male (Mandibular Denture)	26	1160154	147.5726	HS

HS: Highly Significance  $p < 0.001$

S.O.V.: Source of variance

d.f.: Degree of freedom

M.S.: Mean square

Table (4): Mean square analysis for measurements of load according to prosthesis and technique

S.O.V.	d.f.	M.S.	F	p value	
Between maxillary and mandibular dentures of conventional and neutral zone techniques	Conventional and Neutral Zone (Maxillary Denture)	48	875429.1	72.4906	HS
	Conventional and Neutral Zone (Mandibular Denture)	48	2156134	111.9357	HS
	Conventional (Max. & Man.)	48	648660	56.73428	HS
	Neutral Zone (Max. and Man.)	48	74343.68	3.734851	S

HS: Highly Significance  $p < 0.001$

S: Significance  $p < 0.01$

S.O.V.: Source of variance

d.f.: Degree of freedom

M.S.: Mean square



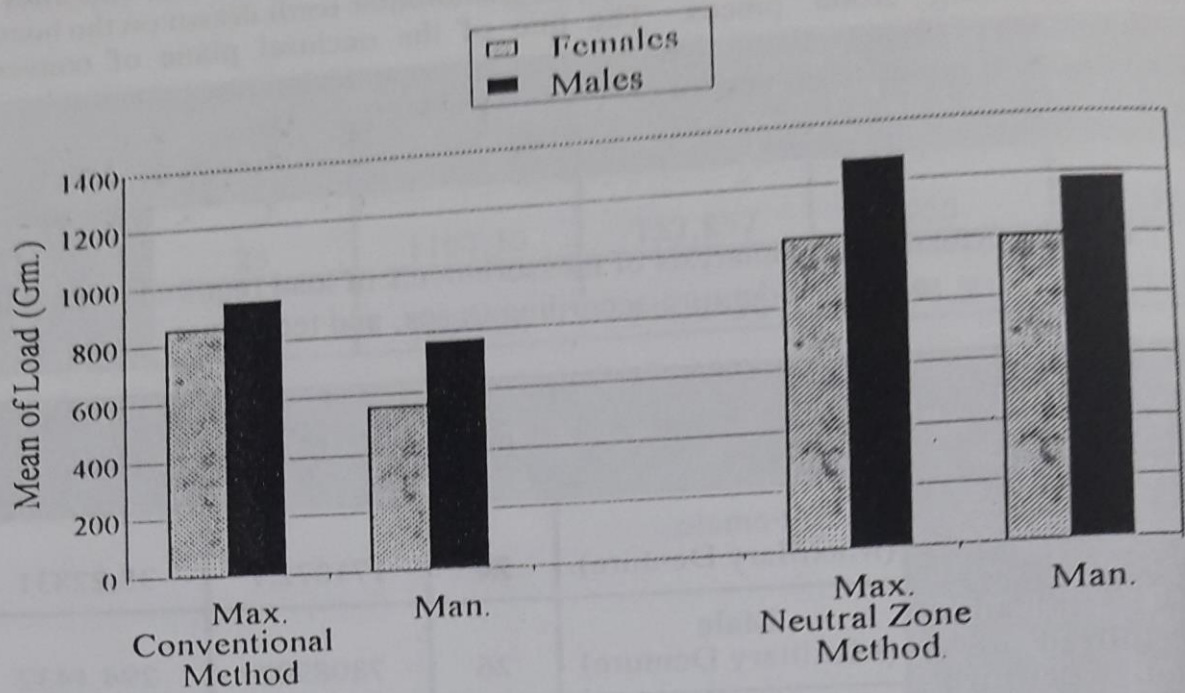


Figure (6): Mean of load required to dislodge dentures according to the sex

Table (5): Mean of differences between the level of occlusal plane of the two techniques

Impression Technique	Premolar Region (mm.)	Molar Region (mm.)
Conventional	16.67	18.69
Neutral Zone	14.45	16.22

The result of using two sets of maxillary and mandibular complete dentures in single blind trial for one month showed that (92-100%) of total patients documented their acceptance of the prostheses done in neutral zone to that done in the conventional technique (table 6).

The height of occlusal surfaces of denture teeth from the dental ridge is an important factor in permitting the tongue and medial roll of buccinator muscle to function efficiently. The occlusal surface of the mandibular first bicuspid should never be superior to the corner of the mouth, and the medial fibers of buccinator muscle form a fixative point with the first bicuspid at the corner of the mouth <sup>(12,14,15)</sup>.



Table (6): Patient responses to conventional and neutral zone dentures "patient, denture satisfaction questionnaire"

Question	Answers							
	Conventional				Neutral zone			
	Yes	%	No	%	Yes	%	No	%
1- Are you satisfied with your denture?	21	84	4	16	25	100	0	0
2- Are you satisfied with the appearance of your denture?	9	36	16	64	23	92	2	8
3- Are you satisfied with how well your upper denture stays in place?	23	92	2	8	25	100	0	0
4- Are you satisfied with how well your lower denture stays in place?	7	28	18	72	25	100	0	0
5- Are you satisfied with how well you chew food with your denture?	5	20	20	80	25	100	0	0
6- Are you satisfied with how well you speak with your denture?	7	28	18	72	24	96	1	4
7- Are you satisfied with comfort of your upper denture?	7	28	18	72	24	96	1	4
8- Are you satisfied with comfort of your lower denture?	5	20	20	80	25	100	0	0
9- Are you satisfied with how well other people (such as wife, husband, children, etc.) like your denture?	9	36	16	64	23	92	2	8

## CONCLUSION

1. The analysis of variance procedure of using two techniques showed high significance to 1% of neutral zone than that done in a conventional technique.
2. The load required to dislodge mandibular denture done in the neutral zone technique was higher than that done in conventional technique. (415.32 gm.).
3. The differences between the level of occlusal plane done in two methods were ranging between (2.22 mm.) of premolar region, and molar region about (2.47mm.).
4. The blind trail of treatment and the distribution of the response of patient to prostheses showed high percentage acceptance to the efficiency of speech, mastication and esthetic of neutral zone technique prostheses with range between (92) and (100%).



## REFERENCES

1. Wee AG, Cwynar RB, Cheng AC. Utilization of the neutral zone technique for maxillofacial patients. *J Prosthodont*. 2000; 9(1): 2-7.
2. Beresin VE, Schiesser FJ. *The Neutral Zone in Complete and Partial Dentures*. 2<sup>nd</sup> Edn. St Louis Mosby- Yearbook. 1978.
3. Neill DJ, Glaysher JKL. Identifying the denture space. *J Oral Rehabil*. 1982; 9: 259-277.
4. Academy of Prosthodontics. Glossary of prosthodontic terms. *J Prosthet Dent*. 1994; 71(1): 87.
5. Sato M. Influence of various impression procedures for mandibular distal extension removable partial denture on displacement of residual ridge. *Kokubyo-Gakkai-Zasshi*. 1996; 63(1): 88-107.
6. Zarb GA, Bolender CL, Carlsson GE. *Boucher's Prosthodontic treatment for Edentulous Patients*. 11<sup>th</sup> Edn. Mosby Co. 1997; Pp: 187-106.
7. Karlsson S, Hedegard B. Study of the reproducibility of the functional denture space with a dynamic impression technique. *J Prosthet Dent*. 1979; 41:21-25.
8. Wright CR, Swartz WH, Gogwin WC. *Mandibular denture stability. (A new concept)*. The Overbeck Company Publishers Ann Arbor Michigan. 1961; Pp: 4-14.
9. Cathy GM, Taylor DF. *Dental Laboratory Technology*. 1968. Copyright University of North Carolina. Pp: 11-99.
10. Hatim NA. Volumetric changes in acrylic denture base material. MSc thesis submitted to the College of Dentistry, University of Baghdad. 1988.
11. Farhood IK. The impact of psychoneurotic status of complete denture wearers and some other factors on patient satisfaction. MSc thesis submitted to the College of Dentistry, University of Baghdad. 2000; Pp: 85.
12. Hatim NA. Retention of maxillary complete denture using different impression materials (A comparative study). *Iraqi Dent J*. 1993; 16: 55-61.
13. Ohkubo C, Hantani S, Hosoi T, Mizuno Y. Neutral zone approaches for denture fabrication for a partial glossectomy patient: A clinical report. *J Prosthet Dent*. 2000; 84(4): 390-393.
14. Kois JC, Fan PP. Complete denture impressioning technique. *Compend Contin Educ Dent*. 1997; 18(7): 699-704.
15. Hyde TP, McCord JF. Survey of prosthodontic Impression procedures for complete denture in general dental practice in the United Kingdom. *J Prosthet Dent*. 1999; 81:295-299.