

Histological Assessment for Healing of Intraoral Surgical Wounds Produced by Diode Laser 940 nm Versus Surgical Scalpel Blade (An in Vivo study)

Mohamed Sabah Abdul Wahab
BDS, (Master student)

Department of Oral and Maxillofacial Surgery
College of Dentistry, University of Mosul

Abdulhameed N. Aldabagh
BDS., MSc , PhD (Lec.)

Department of Oral and Maxillofacial Surgery
College of Dentistry, University of Mosul

Abdulsattar Salim Mahmood
BDS, MSc, PhD, (Lec.)

Department of Oral and Maxillofacial Surgery
College of Dentistry, University of Mosul

الخلاصة

الأهداف: تهدف الدراسة الى مقارنة التئام الجروح بين عمليتين جراحيتين مختلفتين وتقييم كفاءة الدايبود ليزر (ليزر الدايبود) على التئام الجروح .
المواد وطرائق العمل: تم استخدام ١٦ من أرانب نيوزيلندا. تم عمل نوعين من شق الجرح في الغشاء الفموي لكل مجموعة، كل شق يتم باستخدام شفرة مشرط جراحي من الفولاذ المقاوم للصدأ رقم ١٥ وليزر الدايبود. تمت التضحية بأرانبين من كل مجموعة في اليوم الأول والثالث والسابع والرابع عشر بعد الإجراءات. **النتائج:** كشفت النتائج النسيجية لهذه الدراسة أنه كان هناك اختلاف كبير في ارتشاح الخلايا الالتهابية في اليوم الأول والثالث والسابع في جميع المجموعات، في حين لم يكن هناك فرق كبير في فترة ١٤ يوم. ظهر تكوين النسيج الحبيبي أعلى في مجموعة الدايبود ليزر، في حين أظهر الشق باستخدام المشرط كمية أقل من تكوين أنسجة التحبيب. لم يكن هناك إعادة في نسيج الظهارة لكل المجموعات خلال اليوم الأول، وأظهرت إعادة الظهارة للغشاء المخاطي للفم اختلافاً كبيراً بعد ثلاثة أيام، وتختلف الدلالة أيضاً في اليوم السابع بين ليزر الدايبود والمشرط، ولا توجد اختلافات في الأهمية في ١٤ يوماً في كلا المجموعتين. **الاستنتاجات:** ليزر الدايبود له العديد من المزايا للاستخدام خاصة في جراحة الفم، بسبب قدرته على إيقاف النزيف، ولكن يحدث تلف للأنسجة أكثر وارتشاح الخلايا الالتهابية أكثر من المجموعة التي تستخدم شفرة المشرط الجراحي.

ABSTRACT

Aims: The objectives of this study were to compare the wounds healing between two different surgical procedures and to evaluate the efficiency of the diode laser on wound healing after intra-oral incision.
Materials and Methods: Experimental study were done on 16 New Zealand rabbits. Two types of wound incision were made in buccal mucosa of each group, each incision was made by using stainless steel scalpel blade NO.15 and other was made by Epic X diode laser. Two rabbits sacrificed of each group at 1st, 3rd, 7th and 14th days after procedures. **Results:** The histological findings of this study revealed that there was a significant difference for inflammatory cell infiltration in 1st, 3rd, 7th days in two groups, while there was no significant difference at 14th days period. Granulation tissue formation appeared higher in diode group, while scalpel showed less amount of granulation tissue formation. In re-epithelialization of present study at 1st day all section showed nil scores, re-epithelization of oral mucosa appeared significant difference after three days, and significant difference also at 7th day between diode and scalpel, no significance differences at 14 days in two groups. **Conclusions:** Diode laser has many advantages for use particularly in oral surgery, due to a better hemostatic ability, but more tissue damage occurs and more inflammatory cell infiltration in site of incision if compared with group that used of surgical scalpel blade.

Keywords: Diode laser, Scalpel Blade, Histometric analysis, Wound healing

Abdul Wahab MS., Aldabaghan AN., Mahmood AS. Histological Assessment for Healing of Intraoral Surgical Wounds Produced by Diode Laser 940 nm Versus Surgical Scalpel Blade (An in Vivo study). Al-Rafidain Dent J. 2020;20(2):233-243.

DOI: [10.33899/rden.2020.127185.1037](https://doi.org/10.33899/rden.2020.127185.1037) ©2020, College of Dentistry, University of Mosul

Received: 23/5/2020 Sent to Referees: 30/5/2020 Accepted for Publication: 5/7/2020

This is an [open access](https://creativecommons.org/licenses/by/4.0/) article under the [CCBY4.0](https://creativecommons.org/licenses/by/4.0/) license (<http://creativecommons.org/licenses/by/4.0/>).

INTRODUCTION

Wound can be defined as an abnormal condition of cellular structure or function of the human body, wound occurred due to the external injury with or without disruption of connective tissue ⁽¹⁾. The healing process of wound is a complicated pathophysiological mechanism that contains inflammatory and proliferative events⁽²⁾.

Surgical scalpels are major tools to make surgical incision⁽³⁾. The negative effects of using scalpel blade are bleeding, pain, especially in highly vascular oral lesion and in a patient complaint of bleeding diseases ⁽⁴⁾. Laser units are the alternative to surgical blade on surgeries involving hard and soft operations ⁽⁵⁾.

Laser is classified into a different type according to the material of active medium that made from. Within the diode laser, the active medium that used is a semi-conductor type in which a diode pumped directly with electrical current to create a laser beam, diode laser energy can cut soft tissue ⁽⁶⁾. The performance of the laser is based on peak absorption rates of each laser wavelength. Certain wavelengths of the laser like Diode laser have an affinity for red pigmented structures, which makes them particularly effective for soft tissue surgery⁽⁷⁾. Diode laser wavelengths ranging from 635nm (red region of the visible spectrum) to 980 nm (infrared portion of the light spectrum)⁽⁸⁾.

Aims of Study: the aims of the study were to estimation of wound healing with various

surgical techniques, and to measure up the efficiency of diode laser device on wound healing post-surgery.

MATERIALS AND METHODS

Sixteen male New Zealand rabbits aged between 3 to 4 months and weight between 1.25 and 1.5 kg, were used. They were kept in animal house at standard environment, and the animals were kept at environmental temperature of 30 ± 5 C° and all they received same amount of nutrition.

Animal grouping :

After 3 weeks of vaccination by Ivermectin for killing parasites and kept in animal's house, rabbits were randomly assigned into two experimental groups according to the types of incision. Each group consisted of 8 animals; two animals were euthanized at 1Day,3Days,7Daysand 14 Days' time intervals. Group 1: Stainless steel surgical blade wound incision. In this ,group incision was made by scalpel on buccal surface in oral mucosa of the rabbits.

Group 2: Diode laser wound incision (Epic™ X). In this group incision was made by diode laser on buccal surface in oral mucosa of the rabbits.

Surgical procedure

The performed surgical procedures followed a standardized protocol that used in Mosul University / College of

Dentistry/Department of Oral and Maxillofacial Surgery so as not to influence the surgical trauma during operation.

Anesthetized each rabbit by slowly administered of (0.6 CC) Ketamine with Xylazine Hydrochloride per one kilogram. The surgical site in the oral cavity was disinfected by Chlorhexidine Gluconate %0.2 pre-incision.

Similar depth and size of incisions (0.5cm length and 0.2 cm depth by using Vernia) were made on buccal surfaces of oral mucosa on each rabbit that included in this experiment, we selected oral mucosa of rabbits because oral histology of New Zealand rabbit resemble lining mucosa of human. The incision was performed using either a stainless-steel scalpel blade No. 15, or diode laser (Epic™ X diode laser). All wounds were left opened.

Parameter for Diode laser

The setting of diode laser device and laser tip selected according to manufacturer

recommendation. The diode laser wavelength was (940 ± 10nm), Mode (CP1) Peak Power (2.7 W) Avg. Power (0.9 W) Pulse Interval (0.2 ms) Pulse Length (0.1 ms) Duty Cycle (30%) Tip Type (E4). The Pre-initiated tips diameter were 400µm and 4mm length (in contact mode, pulse modulation 100 microseconds (on) pulse duration 200 microseconds (off) pulse interval) was used.

Histological analysis

After euthanasia was confirmed , the tissue in the area of incision was immediately dissected from buccal mucosa and introduced in a solution of 10% Neutral Buffered Formalin (NBF). The specimens were harvested, and sections of 5 microns in thickness and stained with hematoxylin/eosin (H&E) stain for histological analysis. The histometric measurements were done under a light microscope connected to a digital camera at magnification of x10and x40. depending on Criteria in (Tables 1, 2 and 3).

Table (1) : Criteria of inflammatory cells infiltration (scoring): (15, 16)

1	Nil No inflammatory cells seen in the field of operation (X10).
2	Mild When inflammatory cells present in few numbers, less than ½ of the field (X10).
3	Moderate inflammatory cells could be seen in more than ½ of the field (X10).
4	Severe or abundant when inflammatory cells present in huge numbers, more than ¾ of the field (X10).

Table (2): Criteria for granulation tissue formation (Scoring):(15, 16)

1	Absent of granulation tissue formation in wound.
2	Quantity of granulation tissue formation in the wound gap is scanty.
3	Amount of granulation tissue formation is moderate in tissues.
4	Total amount of granulation tissue formation in the wound is profound.

Table (3): Criteria of re-epithelization (Scoring):(17)

0	Re- epithelization at the edge of the wound.
1	Re- epithelization covering less than half of the wound.
2	Re- epithelization covering more than half of the wound.
3	Re- epithelization covering the entire wound, irregular thickness
4	Re- epithelization covering the entire wound, normal thickness.

These slides sections obtain from mesial, middle and distal region of 1 cm incision in order to exam complete sits of incision.

Statistical analysis

The study used non-parametric u-test (Mann-Whitney), because its comparative study between two groups and data not followed specific disruption.

RESULTS

All rabbits tolerated this procedure well and

recovered after surgery without any serious complications.

Histological findings

At The First Day

At 24 hours the inflammatory cells infiltration showed the mean of scores were high in both groups (Figure.1 , Table 4 and Table 5). Granulation tissue formation was recorded low at first day in scalpel and diode groups (Figure.2 , Table 4 and Table 5) . Mean of the re-epithelization criteria also recorded lowest in both groups at this period (Figures 3, 4 and 5).

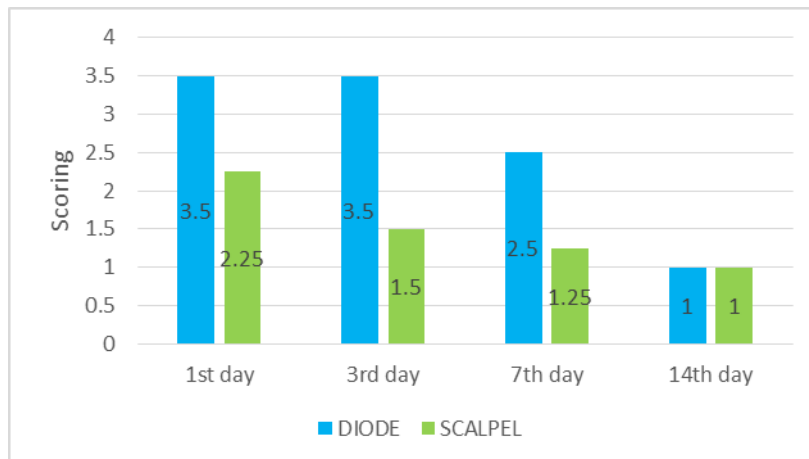


Figure (1): Inflammatory Cells Infiltration Scoring at 1st ,3rd ,7th ,and 14th Days after Incisions

Table (4) : Mean of scores of Inflammatory cells infiltration, Granulation tissue formation and Re-epithelialization for scalpel blade incision groups.

Euthanized day for scalpel group	I.C.I.* means of scores	G.T.F.* means of scores	Re-epithelization means of scores
1 st	2.5	1.5	0
3 rd	1.5	2	0.5
7 th	1.25	1.5	2.75
14 th	1	1.5	4

Table (5): Mean of scores of inflammatory cells infiltration, granulation tissue formation and re-epithelialization for Diode laser (Epic™ X diode laser) incision groups.

Euthanized day of diode group	I.C.I.* means of scores	G.T.F.* means of scores	Re-epithelization means of scores
1 st	3.5	1.25	0
3 rd	3.5	3	0.25
7 th	2.5	2.75	1.75
14 th	1	3	3

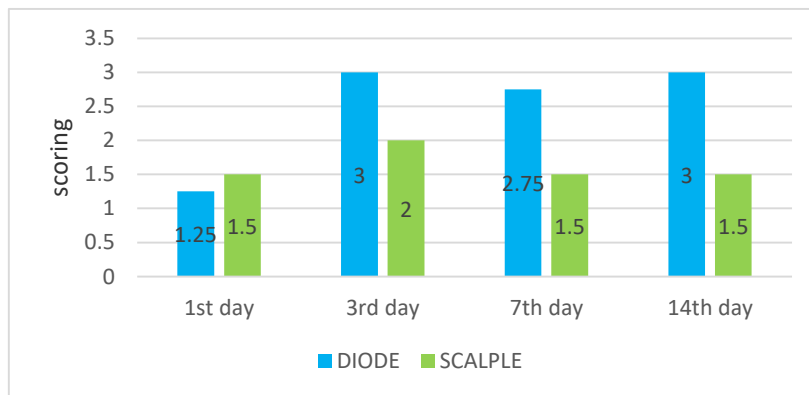


Figure (2): Granulation Tissues Formation Scoring at 1st ,3rd ,7th ,and 14th Days after Incisions

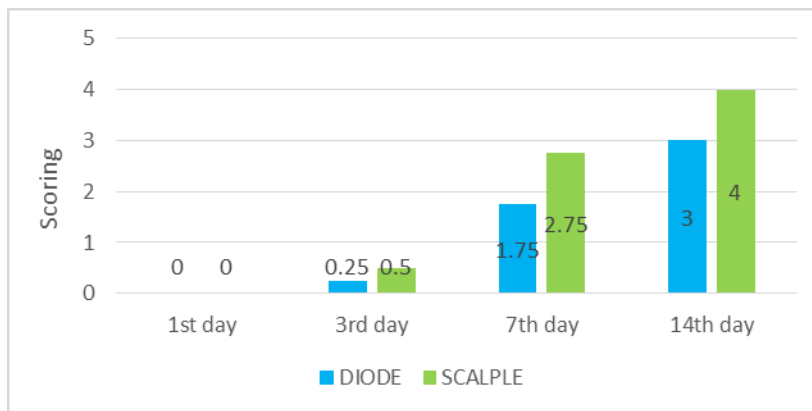


Figure (3): Re-epithelization of oral mucosa Scoring at 1st ,3rd ,7th ,and 14th Days after Incisions

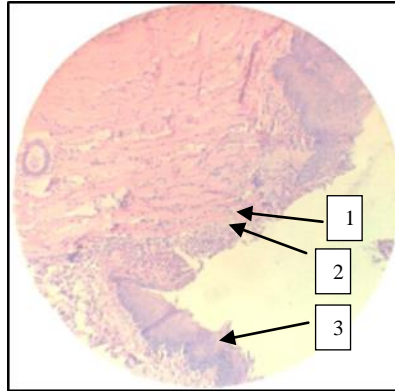


Figure (4): Histological section of scalpel blade incision at 1st day 1,infalmmatoroty cells.2, granulation tissue 3, Re-epithelization.

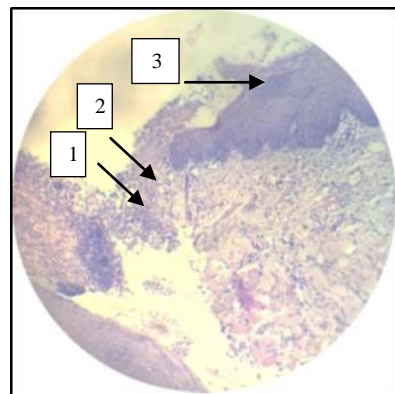


Figure (5): Histological section of diode laser incision at 1st day 1,infalmmatoroty cells.2, granulation tissue 3, Re-epithelization.

At The Third Day

According to our results and histological analysis at 3rd day after procedure, we found a high number of inflammatory cells infiltration present in diode laser incision. While, the scalpel group showed lowest count of inflammatory cells infiltration (Figure 1). In granulation tissue formation criteria, our result showed that the quantity of granulation tissue

formation higher in the diode followed by scalpel group incision at 3rd daytime period (Figure.2,Table 4 and Table 5). Depending on histometric analysis, re-epithelization of the wound at 3rd day seem the diode and scalpel showed close records in two groups, that are the re-epithelialization only on the edges of the wound (Figures .3, 6,and 7).

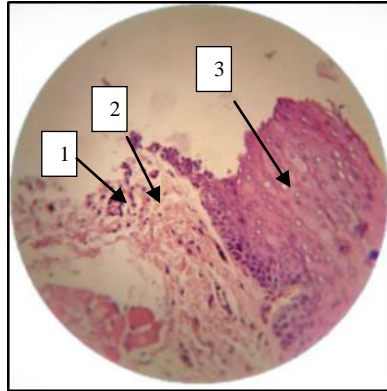


Figure (6): Histological section of scalpel blade incision at 3rd day 1, inflammatory cells. 2, granulation tissue 3, Re-epithelization.

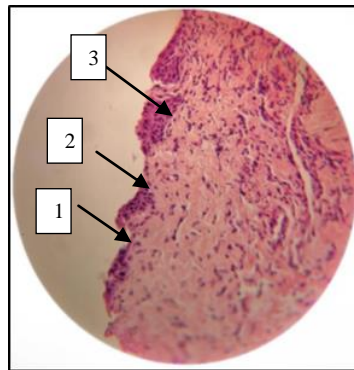


Figure (7): Histological section of diode laser incision at 3rd day. 1, inflammatory cells. 2, granulation tissue 3, Re-epithelization.

At The Seventh Day

At day seven, the inflammatory cells infiltration scores were minimum in scalpel group, while, the mean of inflammatory cells infiltration was highest in the diode group (Figure 1). Granulation tissue formation scores

were highest in the diode, intermediate in the scalpel (Figure 2). Re-epithelization of wound was highest in the scalpel, whereas, diode group showed the lowest record in compared with scalpel incision (Figures 3, 8, and 9).

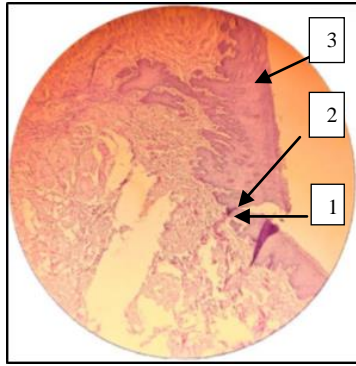


Figure (8): Histological section of scalpel blade incision at 7th day 1, inflammatory cells. 2, granulation tissue 3, Re-epithelization.

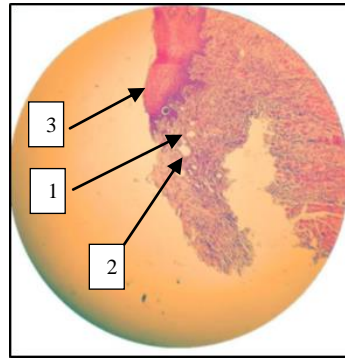


Figure (9): Histological section of diode incision at 7th day 1, inflammatory cells. 2, granulation tissue 3, Re-epithelization.

At The Fourteenth Day

Inflammatory cells infiltration disappeared completely in both groups (Figure 1). The quantity of granulation tissue formation higher in the diode. They were followed by scalpel group incision at 14th day (Figure 2). According

to the slides sections and histometric analysis, re-epithelization of the wound at 14th day seem completed in both groups with irregular thickness of epithelium in diode groups (Figures 3, 10, and 11).

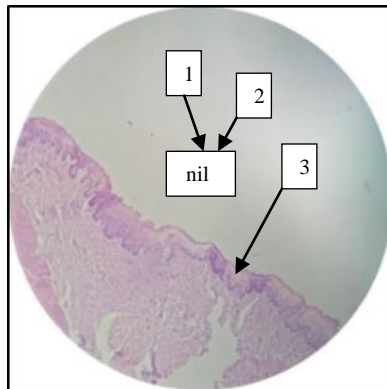


Figure (10): Histological section of scalpel blade incision at 14th day 1, inflammatory cells. 2, granulation tissue 3, Re-epithelization.

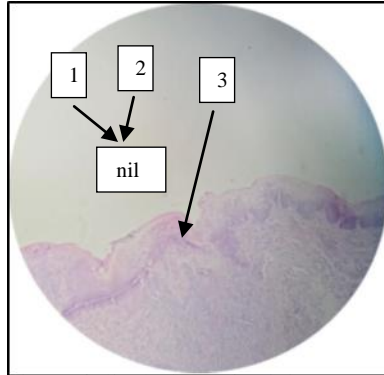


Figure (11): Histological section of diode laser incision at 14th day 1, inflammatory cells. 2, granulation tissue 3, Re-epithelization.

DISCUSSION

At the beginning of 21st century many researches have been achieved on laser technology. The clinical observation of incisions that's made by laser device showed many advantages on soft tissue surgery, which includes: precision, a relatively great coagulation of blood, with minimum swelling and scarring in surgical site, and no need for suture, these benefits were accepted with many researches⁽⁹⁻¹¹⁾.

Monteiro, Delgado et al. 2019 found best tools that caused less tissues damage on both epithelial and connective tissue was cold scalpel blade because no thermal burn occurred, and this came parallel with current study⁽¹²⁾.

Amaral, de Avila et al. 2015 in their study discovered wound healing will be fastest when surgical scalpel blade is used for removing of oral lesions. And Azevedo, Monteiro et al. 2016 Found that the scalpel blade create smallest amount of tissue damage in comparison with other equipment's that used in their study. In addition, Cayan, Hasanoglu Erbasar et al. 2019

discovered when scalpel blade used, and the clinical pictures taken of surgical site for judgment. Post-surgery showed the wound healing occurred faster in scalpel blade in compared with diode group when remove the same class of oral lesion. In histological part and clinical observation of wound in present study showed healing of incisions produced by scalpel much faster than other groups, came parallel with Amaral, Azevedo, et al. founds^(5, 7, 13).

Monteiro, Delgado et al. 2019 in their study for histological evolution by using different instruments, they discovered that the epithelial and sub-epithelial damage were biggest and deepest in diode laser group, diode laser caused huge damage and thermal tissues artifacts on both layers of oral mucosa. In present study histological assessment totally agree with what Monteiro et al. 2019 established⁽¹²⁾.

Romeo et al. 2014 in their clinical study performed on patient suffered from benign oral lesion, they found in histological part of their study. The lesion removed by diode laser have

huge inflammatory cells infiltration with tissue artifacts which is due to higher thermal damage to the tissue and this came equal with an existing experimental study in incisions made by diode laser on buccal mucosa of rabbits. Satisfactory histological analysis can be achieved, but need to enlarge safe margin of biopsy about 0.5 mm to avoid these negative effects of diode laser. these measures taken especially in inflammatory lesions such as oral lichen planus diagnosis⁽¹⁴⁾.

CONCLUSIONS

Although the diode laser has better hemostatic ability, but more tissue damage occurred and extra inflammatory cell infiltration in site of incisions if compared with the scalpel group . Scalpel Blade (No.15) even though has better healing process and decent cutting of tissue without effect on histological analysis of specimen ,but scalpel blade was unable to produced sufficient hemostasis that specially needed in highly vascular lesion. All tools have efficient re-epithelization and good wound prognosis.

REFERENCES

- 1.Kang MH, Kim BH. Oral Wound Healing Effects of Acai Berry Water Extracts in Rat Oral Mucosa. Toxicological research. 2018;34(2):97-102.
- 2.Iqbal A, Jan A, Wajid MA, Tariq S. Management of Chronic Non-healing Wounds by Hirudotherapy. World J Plast Surg. 2017;6(1):9-17.
- 3.Giovannini M, Ehmann K. Vibrational Cutting of Soft Tissue with Micro-serrated Surgical Scalpels. Procedia CIRP. 2016;45:199-202.
- 4.Ji Y, Yang K, Peng S, Chen S, Xiang B, Xu Z, et al. Kaposiform haemangioendothelioma: clinical features, complications and risk factors for Kasabach-Merritt phenomenon. The British journal of dermatology. 2018;179(2):457-63.
- 5.Amaral MB, de Avila JM, Abreu MH, Mesquita RA. Diode laser surgery versus scalpel surgery in the treatment of fibrous hyperplasia: a randomized clinical trial. International journal of oral and maxillofacial surgery. 2015;44(11):1383-9.
- 6.Coluzzi DJ, Convissar RA, Roshkind DM. 2 - Laser Fundamentals. In: Convissar RA, editor. Principles and Practice of Laser Dentistry (Second Edition). St. Louis: Mosby; 2016. p. 12-26.
- 7.Azevedo A-S, Monteiro L-S, Ferreira F, Delgado M-L, Garcês F, Carreira S, et al. In vitro histological evaluation of the surgical margins made by different laser wavelengths in tongue tissues. Journal of clinical and experimental dentistry. 2016;8(4):e388-e96.
- 8.Yammine S, Jabbour E, El Toum S, Cassia A. Histological Study of Induced Incisions on Rabbits' Tongues with Three Diode Lasers with Different Wavelengths in Continuous Mode. Scientifica. 2018;2018:2691942.
- 9.Protasio ACR, Galvao EL, Falci SGM. Laser Techniques or Scalpel Incision for Labial

- Frenectomy: A Meta-analysis. Journal of maxillofacial and oral surgery. 2019;18(4):490-9.
10. Eroglu CN, Tunc SK, Elasan S. Removal of epulis fissuratum by Er,Cr:YSGG laser in comparison with the conventional method. Photomedicine and laser surgery. 2015;33(11):533-9.
11. Chandel V, Jangra B, Khurana N, Garg A, Devashish. Venous malformations management by Er,Cr:YSGG laser: An Alternative approach. Laser therapy. 2017;26(4):305-10.
12. Monteiro L, Delgado ML, Garces F, Machado M, Ferreira F, Martins M, et al. A histological evaluation of the surgical margins from human oral fibrous-epithelial lesions excised with CO2 laser, Diode laser, Er:YAG laser, Nd:YAG laser, electrosurgical scalpel and cold scalpel. Medicina oral, patologia oral y cirugia bucal. 2019;24(2):e271-e80.
13. Cayan T, Hasanoglu Erbasar GN, Akca G, Kahraman S. Comparative Evaluation of Diode Laser and Scalpel Surgery in the Treatment of Inflammatory Fibrous Hyperplasia: A Split-Mouth Study. Photobiomodulation, photomedicine, and laser surgery. 2019;37(2):91-8.
14. Romeo U, Russo C, Palaia G, Lo Giudice R, Del Vecchio A, Visca P, et al. Biopsy of different oral soft tissues lesions by KTP and diode laser: histological evaluation. TheScientificWorldJournal. 2014;2014:761704.
15. Gupta A, Kumar P. Assessment of the histological state of the healing wound. Plast Aesthet Res. 2015;2:239-42.
16. Sultana J, Molla M, Kamal M, Shahidullah M, Begum F, Bashar A. Histological differences in wound healing in Maxillofacial region in patients with or without risk factors. Bangladesh Journal of Pathology. 2009;24.
17. Sinha UK, Gallagher LA. Effects of steel scalpel, ultrasonic scalpel, CO2 laser, and monopolar and bipolar electrosurgery on wound healing in guinea pig oral mucosa. The Laryngoscope. 2003;113(2):228-36.