

Healing Assessment of Oral Mucosal Wounds Using Erbium, Chromium: Yttrium-Scandium-Gallium-Garnet Laser Versus Scalpel Blades

Mohamed Sabah Abdul Wahab
BDS, (Master student)

Department of Oral and Maxillofacial Surgery
College of Dentistry, University of Mosul

Abdulhameed N. Aldabagh
BDS., MSc , PhD (Lec.)

Department of Oral and Maxillofacial Surgery
College of Dentistry, University of Mosul

Abdulsattar Salim Mahmood
BDS, MSc, PhD, (Lec.)

Department of Oral and Maxillofacial Surgery
College of Dentistry, University of Mosul

الخلاصة

الأهداف: تهدف الدراسة الى مقارنة التئام الجروح باستخدام إجراءين جراحيين مختلفين وتقييم كفاءة ليزر الإربيوم على التئام الجروح بعد العمليات الجراحية. **المواد وطرائق العمل:** تم استخدام ١٦ من الأرانب النيوزيلندية كحيوانات تجريبية، ٨ أرانب لكل نوع من الشق في هذه الدراسة، شق مشروط الفولاذ المقاوم للصدأ رقم ١٥، ليزر الإربيوم Erbium, Chromium: Yttrium-Scandium-Gallium-Garnet Laser. أتم التضحية بأرانب من كل مجموعة في اليوم الأول والثالث والسابع والرابع عشر بعد الإجراءات، وأيضاً في يوم التضحية، يجمع الدم من كل أرنب من أجل المصل والتحليل المصلي لتحديد مستوى TNF- α **النتائج:** ١: كشفت النتائج النسيجية لهذه الدراسة أنه كان هناك اختلاف في ارتشاح الخلايا الالتهابية في اليوم الأول بين مجموعتين، في حين لم يكن هناك اختلاف كبير في فترة ٣ و٧ و١٤ يوماً. ظهر تكوين أنسجة حبيبية أعلى في مجموعة الإربيوم Er,Cr:YSGG، بينما أظهر المشروط كمية أقل من تكوين أنسجة الحبيبي. في إعادة نسيج الظهارة في اليوم الأول، يظهر درجة الصفر في كلتا المجموعتين، في اليوم الثالث، ظهرت إعادة نسيج الظهارة اختلافاً واضحاً، ولا يوجد فرق معنوي في اليومين السابع والرابع عشر بين الإربيوم والمشروط. تظهر النتائج المصلية لهذه الدراسة أن مستوى TNF- α في المصل لا يظهر اختلافات كبيرة بين مجموعتين في فترة زمنية مختلفة. **الاستنتاجات:** ليزر الإربيوم Er,Cr:YSGG له العديد من المزايا للاستخدام خاصة في جراحة الفم، بسبب الاستجابة الالتهابية المنخفضة وتقرحات أقل وأقل ضرر للأنسجة المخاطية الفموية، ولكن يحدث تلف أكثر للأنسجة وارتشاح أكثر للخلايا الالتهابية مقارنة بالمجموعة التي تستخدم شفرة مشروط جراحي.

ABSTRACT

Aims : The study aims to compare wound healing histologically and serologically by using two different surgical procedures and to evaluate the efficiency of the Er,Cr:YSGG laser on wound healing after surgical procedures. **Materials and Methods :** Sixteen New Zealand rabbits were used as experimental animals. The animals were divided into two groups: group I and group II, each group consisted of 8 rabbits. In group I; stainless steel scalpel blade NO.15 was used for making the incision, in group II Er, Cr: YSGG laser was used for making the incision. Two rabbits were sacrificed from each group at the 1st ,3rd ,7th and 14th days after procedures. On the day of sacrificial blood was collected from each rabbit for serum and serological analysis to determine serum level of TNF- α . **Results :** 1:Histological findings of this study revealed that there was a significant difference in inflammatory cells infiltration at 1st day between the two groups, while there was no significant difference at 3rd , 7th and 14th day periods. Granulation tissue formation appeared higher in erbium group, while scalpel blade incision showed less amount of granulation tissue formation. In re-epithelialization at 1st day all section shows nil score in both groups, at 3rd day re-epithelialization appeared significant difference, and no significance difference at 7th and 14th days between erbium and scalpel blade. 2: Serological findings of this study shows that TNF- α level in serum have no significant differences between two groups at different time periods. **Conclusions :** Er,Cr:YSGG laser has numerous benefits for use particularly in oral surgery , due to low inflammatory reaction and less ulceration and smallest damage of the oral mucosal tissue, while more inflammatory cell infiltration occurs in comparison with group that used surgical scalpel blade.

Keywords: Er,Cr:YSGG laser, scalpel Blade, Tumor necrosis factor- α , Histometric analysis .

Abdul Wahab MS., Aldabaghan AN., Mahmood AS. Healing Assessment of Oral Mucosal Wounds Using Erbium, Chromium: Yttrium-Scandium-Gallium-Garnet Laser Versus Scalpel blades. *Al-Rafidain Dent J.* 2020;20(2):244-256.

DOI: [10.33899/rden.2020.127183.1036](https://doi.org/10.33899/rden.2020.127183.1036) ©2020, College of Dentistry, University of Mosul

Received: 23/5/2020 Sent to Referees: 30/5/2020 Accepted for Publication: 5/7/2020

This is an [open access](https://creativecommons.org/licenses/by/4.0/) article under the [CCBY4.0](https://creativecommons.org/licenses/by/4.0/) license (<http://creativecommons.org/licenses/by/4.0/>).

INTRODUCTION

Wound define as breakdown in the normal continuity of the covering skin and/or mucosa; the loss of epithelial barrier, with or without disruption of underlying connective tissue (dermis, fascia and muscles) ,wounds occurred due to external damage⁽¹⁻⁵⁾. The wound healing process is a complex pathophysiological mechanism that includes a cascade of coordinated inflammatory and proliferative events⁽⁶⁾.

Surgical scalpels are fundamental tools to make soft tissue incisions⁽⁷⁾. The problems of using scalpel blade are pain, bleeding specially in highly vascular lesion and in a patient with bleeding disorders⁽⁸⁾. Many laser systems units are alternative to surgical knife blade on surgeries involving oral soft and hard tissues⁽⁹⁾.

The erbium laser first developed in 1990 and then came to the dental market and get approval from the Food and Drug Administration (FDA) to use on human being in 1997⁽¹⁰⁾. The performance of the laser is based on peak absorption rates of each laser wavelength. With erbium laser has an affinity for (H₂O) particles , which makes them able to cut hard tissue as well as soft tissue⁽¹¹⁾.

The biomarkers are biological indicator substances, the specific biomarkers can be identified by diagnostic tests, imaging technologies and other measurement devices of an individual's health status⁽¹²⁾. Researches have shown many mediators and cellular events happened within the wound healing that can be served as biomarkers. Neutrophils, Natural Killer Cell ,Macrophages, platelets and fibroblasts release cytokines molecules including Tumor necrosis factor- α (TNF- α)⁽¹³⁾.

Aims of Study

- Is to compare wound healing under two different surgical procedures.
- To evaluate the efficiency of the erbium laser device on wound healing after surgical procedures.

MATERIALS AND METHODS

Sixteen healthy male New Zealand rabbits aged between 3 and 4 months and weight between 1.25 and 1.5 kg were used. They were retained in animal house at standard environment, and the animals were kept at a temperature of 30 ± 5 °C and all they received same amount of nutrition, so the outcome of wound healing be same in all rabbits .

All experimental procedures operating on rabbits followed the animal care protocol to

prevent any health problems and to promote efficiency.

Animal grouping

The animals were randomly assigned into two experimental groups according to the types of incision. Each group consisted of 8 animals; two animals were euthanized at 1st day, 3rd Days, 7th Days, and 14th Days' time intervals.

Experimental Group I: Stainless steel surgical blade(No.15) wound incision. In this group incision was made by scalpel blade on buccal mucosa of the rabbits.

Experimental Group II: Er, Cr: YSGG laser wound incision (Waterlase MD, Biolase Technology, SanRamon, CA) in this group incision was made by Er, Cr: YSGG laser on buccal mucosa of the rabbits.

Surgical procedure

All surgical procedures were performed under supervision of two experienced surgeons, one in Oral and maxillofacial (Laser Specialist) and other in *Veterinary Surgery and they followed* a standardized protocol that used in Mosul University/ College of Dentistry/Department of Oral and Maxillofacial Surgery so as not to induce the surgical trauma during operation.

The rabbits were subjected to dissociative anesthesia by intramuscular administration of Ketamine with Xylazine Hydrochloride (0.6 ml) per one kilogram. After anesthesia, the surgical field in the oral cavity was disinfected by Chlorhexidine Gluconate %0.2 as a topical antiseptic.

Each incision had made with size of 5 mm length and 2 mm depth. The position of each incision was in a mid-space of diastema area between the angle of a mouth and mesial surface of posterior teeth.

All wounds were left opened.

All experimental animals did not take any type of analgesics or antibiotics postoperative.

Erbium, Chromium: Yttrium-Scandium-Gallium-Garnet laser parameter:

The Er, Cr:YSGG laser apparatus (Fig.1) wavelength was 2780 nm, power 1.5 W, 9% water, 12% air spray, pulse duration (140 ms), repetition rate (30 Hz), energy density of (300 mJ/cm²) with a contact mode (S-mode), tip type (MT-4), and hand-piece type (MD Gold Handpiece).

The setting of laser device was according to manufacturer recommendation. The laser device calibrated by the dealer (**BIOLASE Service-ERBIL**) before the study.




Figure (1): Er, Cr:YSGG laser apparatus

Serological test

After the rabbit had been sacrificed by using a sharp knife, the first few drops left to prevent hemolysis. Blood collection tubes are disposable and non-endotoxin (Purified E.coli endotoxin, Gram negative bacteria and Gram-positive bacteria induce cytokines secretion by whole blood cultures (WBC's) and this will affect on level of TNF- α). The tube put in a holder in upright position for serum preparation which allows samples to clot for 2 hours at room temperature before centrifugation for 15 mins at 3000 \times g at (25 $^{\circ}$ C). The serum collected by micropipette and gathering in Eppendorf

tube, labeling each tube and freeze it in (-20 $^{\circ}$ C) for assaying the level of TNF- α by ELISA test.

Histological analysis

The tissue was immediately dissected from buccal mucosa and introduced in a solution of 10% Neutral Buffered Formalin. The specimens were harvested, and sections of five microns in series were sliced and stained by hematoxylin and eosin for histological analysis. The histometric measurements depending on criteria in (Tables 1,2, and 3) were done under a light microscope connected to a digital camera at magnification of x10 and x40.

Table (1) : Criteria of inflammatory cells infiltration (scoring):^(24, 25)

1	Nil :No inflammatory cells seen in the field of operation (X10).
2	Mild : inflammatory cells present in few numbers, less than $\frac{1}{2}$ of the field (X10).
3	Moderate: inflammatory cells could be seen in more than $\frac{1}{2}$ of the field (X10).
4	Severe or abundant : inflammatory cells present in huge numbers, more than $\frac{3}{4}$ of the field (X10).

Table (2): Criteria for amount granulation tissue formation (Scoring):^(24, 25)

1	Absent of granulation tissue formation in wound
2	Quantity of granulation tissue formation in the wound gap is scanty
3	Amount of granulation tissue formation is moderate in t tissue.
4	Total amount of granulation tissue formation in the wound is profound.

Table (3): Criteria of Re-epithelization (Scoring):⁽²⁶⁾

0	Re-epithelization at the edge of the wound.
1	Re-epithelization n covering less than half of the wound.
2	Re-epithelization covering more than half of the wound.
3	Re-epithelization covering the entire wound, irregular thickness .
4	Re-epithelization covering the entire wound, normal thickness.

Statistical analysis

The current study used non-parametric u-test (Mann-Whitney), because its comparative study between two groups and data not followed specific disruption.

RESULTS

All the rabbits survived during experimental procedures.

Histological findings

At Day one after procedure

The scalpel group appeared moderate

number of inflammatory cells infiltration present in slides section, see (Figures 2, 3, and Table 4). While ,the Er,Cr:YSGG laser incision shows huge number of inflammatory cells infiltration seen in the field of incision see (Figures 4 ,10, and Table 5). Granulation Tissue Formation mainly absent in both the scalpel Er,Cr:YSGG laser incision. Re-epithelialization evaluation in the scalpel and Er,Cr:YSGG groups we noticed that re-epithelialization presents only at the edge of wound in both groups, see (Figures 2 , 3, and 5).

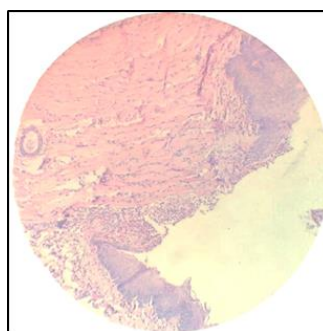


Figure (2): Histological section of scalpel incision at 1st day.

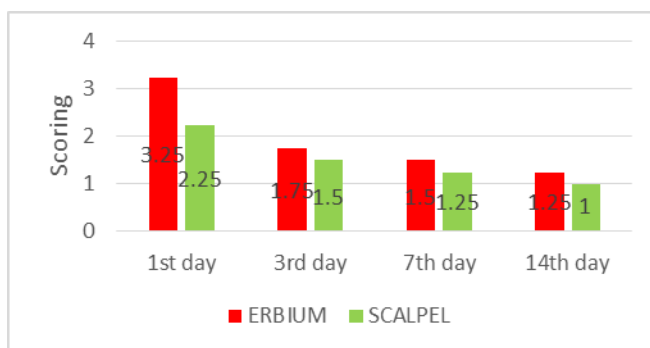


Figure (3): Inflammatory Cells Infiltration Scoring at 1st ,3rd ,7th ,and 14th Days after Incisions

Table (4): Mean of scores of inflammatory cells infiltration, granulation tissue formation and re-epithelialization for scalpel blade incision groups.

Euthanized day of scalpel group	I.C.I. means of scores	G.T.F. means of scores	Epithelization means of scores
1 st	2.25	1.5	0
3 rd	1.5	2	0.5
7 th	1.25	1.5	2.75
14 th	1	1.5	4

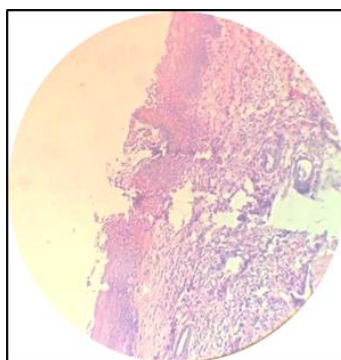


Figure (4): Histological section of erbium laser incision at 1st day

Table (5): Mean of scores of inflammatory cells infiltration, granulation tissue formation and re-epithelialization for Erbium laser (Waterlaser MD; BIOLASE, SanRamon, CA) incision groups.

Euthanized day of erbium group	I.C.I. means of scores	G.T.F. means of scores	Epithelization means of scores
1 st	3.25	1.5	0
3 rd	1.75	1.5	1.5
7 th	1.5	1.75	2.75
14 th	1.25	2	3.5

* I.C.I. = Inflammatory cells infiltration

* G.T.F. = Granulation Tissue Formation

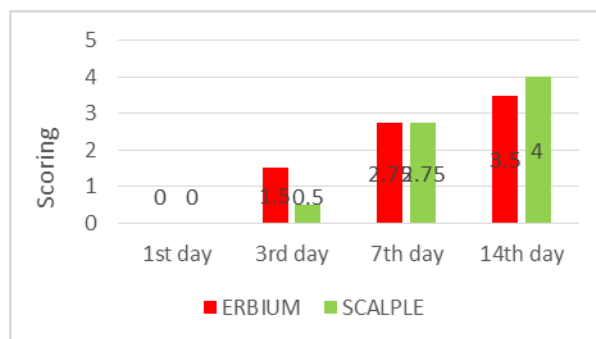


Figure (5): Re-epithelization of oral mucosa Scoring at 1st ,3rd ,7th ,and 14th Days after Incisions

At Third Day after procedure

In scalpel slides display the number of inflammatory cells infiltration present in few quantities, see (Figures 6 , 10, and Table 4). While ,the Er,Cr:YSGG laser incision group section reveled moderate amount of Inflammatory cells infiltration present in tissue section (Figures 7, 10, and Table 5). Granulation Tissue Formation for scalpel group showed small amount of granulation tissue formation (Figures 4, and 9).In Er,Cr:YSGG

laser incision group in some sections was absent ,while on other side of section appear scanty. Re-epithelialization evaluation of wound in scalpel groups present only at the edge of the wound (Figures 4, and 8). Half slides of the Er,Cr:YSGG laser group show us the re-epithelialization covering less than half of the wound. On the other half of slides display re-epithelialization covering more than half of the wound.

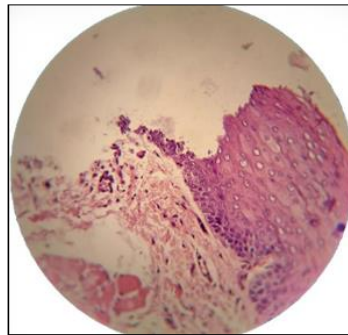


Figure (6): Histological section of scalpel incision at 3rd day.

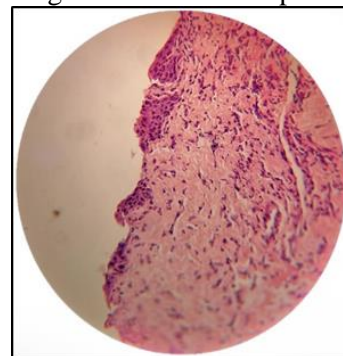


Figure (7): Histological section of erbium laser incision at 3rd day.

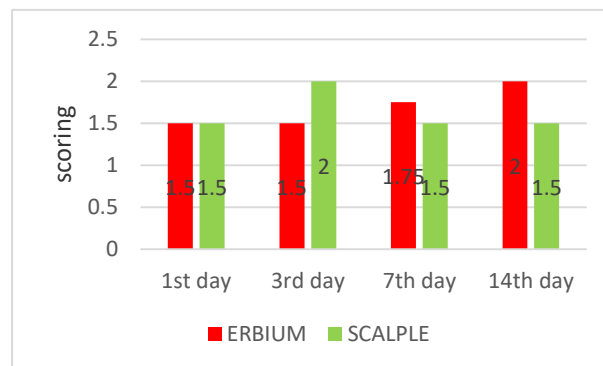


Figure (8): Granulation Tissues Formation Scoring at 1st ,3rd ,7th ,and 14th Days after Incisions.

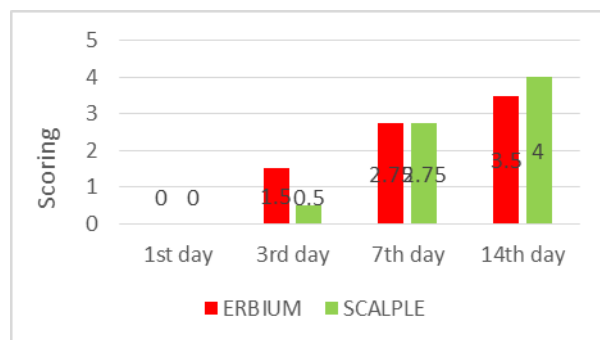


Figure (9): Re-epithelialization of oral mucosa Scoring at 1st ,3rd ,7th ,and 14th Days after Incisions

At One Week after procedure

In scalpel group appear inflammatory cells infiltration present in few numbers and in some section appeared Nil ,see (Figures 10 ,9 and Table 4). While, Er,Cr:YSGG laser section that tell us few number inflammatory cells infiltration see (Figures 7,10, and Table 5). Granulation Tissue Formation in both groups is little. Re-epithelialization in scalpel and Er,Cr:YSGG groups we noticed that re-epithelialization covering the entire wound, with irregular thickness after seven days, see (Figures 6, and 7).

At Fourteen days later

The scalpel slides display no inflammatory cells infiltration present in slide section(Figures 8, and 10). While , Er,Cr:YSGG laser incision group section reveled scores between mild to nil Inflammatory cells infiltration present in tissue section. Granulation tissue formation scored small amount in scalpel and scanty in

erbium . Re-epithelialization scalpel groups showed re-epithelialization covering the entire wound with normal thickness of epithelium(Figures 8, and 12).

Half slides of the Er,Cr:YSGG laser group showed the re-epithelialization covering the entire wound, some slide appeared with regular thickness other histological section display irregular thickness of epithelium (Figures 9 and 12).

Serological findings

Serological test is performed under supervision of Biochemistry Specialist in RNA lab at Mosul city by Using ELISA .The mean of each group according to the score's was recorded by Microplate reader at 450 nm wavelength for serum that collected at first day and at 3, 7, and 14 days' time periods. TNF- α level appeared no significant differences between two groups at different time interval (Tables 6, 7) .

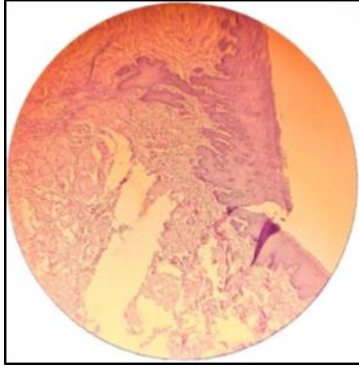


Figure (10): Histological section of scalpel incision at 7th day.

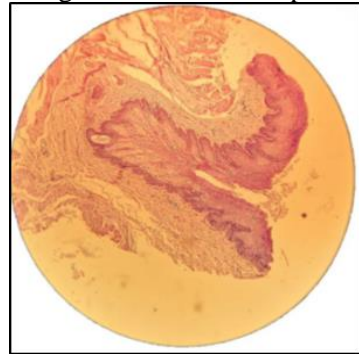


Figure (11): Histological section of erbium laser incision at 7th day

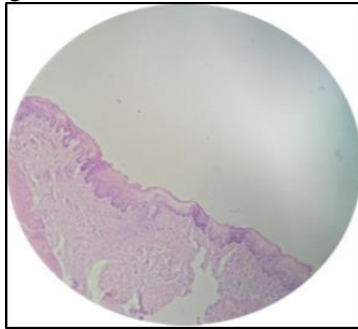


Figure (12): Histological section of scalpel incision at 14th day

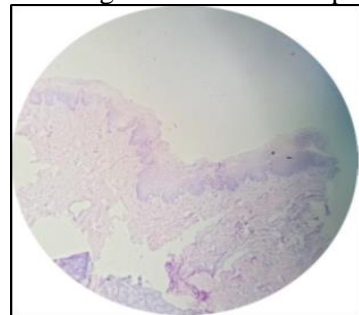


Figure (13): Histological section of erbium laser incision at 14th day.

Table (6): P-value for inflammatory cells infiltration, granulation tissue formation and re-epithelialization at different period.

Euthanized day	Inflammatory Cells Infiltration p-value	Granulation tissue formation P-value	Re-epithelialization P-value
1 st day	0.040*	1.000	1.000
3 rd day	0.495	0.127	0.61
7 th day	0.495	0.495	1.000
14 th day	.0317	0.127	0.127

P-value ≤ 0.05 / (*) Significant different

Table (7):Mean of score for Level of TNF-α at different time interval

Time interval	TNF-α Level for Scalpel group	TNF-α Level for Erbium group
1 st Day	0.052	0.0515
3 rd Day	0.0515	0.0575
7 th Day	0.0515	0.058
14 th Day	0.0545	0.0565

DISCUSSION

During current research the clinical observation of incisions that was made by laser device showed many advantages on soft tissue surgery which included: precision, a relatively great coagulation of blood, with minimum swelling and no need for suture, these benefits were accepted with Protasio, Galvao (14) on their findings.

The histological part of this study found minimal histological damage and cell injury occurred with scalpel, less epithelial damage ,minimal wound gap and less collagen denaturation when surgical scalpel blade used if we compared it with wounds produced by laser

and these come parallel with result of Azevedo, Delgado et al. found on their researches^(15, 16)

Despite the fact that, the erbium laser induces less thermal damage because of water and air spray coolant, minimal epithelial edge damage and tissue artifacts. For this reason, decent and quick re-epithelization of wound margin at site of incision in compared with other types of laser that do not use water during incision .This is accepted with Cercadillo-Ibarguren, España-Tost (17), but scalpel still gave us better re-epithelization this totally agreement with Perussi, Pavone (18). The energy from erbium laser beam was converted into local thermal energy, and this thermal energy generates a massive expansion in the

target water chromophore . The energy causes the water molecules to be heated into steam, causing micro explosions in soft tissue resulted ablation of thin layers of soft tissue which cause strains and fractures the surrounding extracellular collagen matrix⁽¹⁹⁾.

Amaral, de Avila et al. 2015 in their study discovered that wound healing will be faster when surgical scalpel blade is used for removing the oral lesions. And Azevedo, Monteiro et al.2016 found the scalpel blade creates smallest amount of tissue damage in comparison with other equipment's that used in their study. In addition ,Cayan, Hasanoglu Erbasar et al.2019 discovered that when scalpel blade used . Post-surgery showed the wound healing occurred faster in scalpel blade in compared with diode group when remove the same type of oral lesion. In histological part and clinical observation of wounds in present study showed healing of incisions produced by scalpel much faster than other groups and these come match with Amaral, Azevedo, et al. founds^(9, 15, 20).

Serological test

Cytokines level like TNF-alpha will be much higher in non-healing wound and wound with high inflammatory response due to these cytokines released be inflammatory cells like what Patel, Maheshwari⁽¹³⁾, Shah, Omar⁽²¹⁾ found in their researches.

Gohel, Windhaber⁽²²⁾ found in his study, that performed on chronic ulcer to analysis the

relationship between level of cytokines like TNF- alpha and wound healing process ,when blood sample is collected from patients suffered of chronic ulcer, found was poor relationship between cytokines and ulcer healing is consequential remains unknown.

El Ayadi, Herndon⁽²³⁾ Observed the appearance of pro-inflammatory cytokines is significantly changed after burn injury, and the concentration of these cytokines alone or with respect to each other can be used to predict septic condition during healing.

CONCLUSIONS

Depending on results and statistical analysis in (Table 6), the scalpel blade has better healing process and decent cutting of tissue without effect on histological analysis of specimen , Histopathologic artifactual changes induced by Er,Cr:YSGG laser are insignificant but inflammation still here higher than scalpel incisions.This indicates that this laser system could be used for diagnostic as well as therapeutic applications if correct laser parameters and specific laser tip were used.

REFERENCES

1. Businaro R, Corsi M, Di Raimo T, Marasco S, Laskin DL, Salvati B, et al. Multidisciplinary approaches to stimulate wound healing. *Ann N Y Acad Sci.* 2016;1378(1):137-42.
2. Eming SA, Martin P, Tomic-Canic M. Wound repair and regeneration: mechanisms, signaling,

- and translation. *Science translational medicine*. 2014;6(265):265sr6.
3. Trott AT. Chapter 2 - Patient Evaluation and Wound Assessment. In: Trott AT, editor. *Wounds and Lacerations (Fourth Edition)*. Philadelphia: W.B. Saunders; 2012. p. 4-9.
4. Lazarus GS, Cooper DM, Knighton DR, Margolis DJ, Pecoraro RE, Rodeheaver G, et al. Definitions and guidelines for assessment of wounds and evaluation of healing. *Archives of dermatology*. 1994;130(4):489-93.
5. Kang MH, Kim BH. Oral Wound Healing Effects of Acai Berry Water Extracts in Rat Oral Mucosa. *Toxicological research*. 2018;34(2):97-102.
6. Iqbal A, Jan A, Wajid MA, Tariq S. Management of Chronic Non-healing Wounds by Hirudotherapy. *World J Plast Surg*. 2017;6(1):9-17.
7. Giovannini M, Ehmann K. Vibrational Cutting of Soft Tissue with Micro-serrated Surgical Scalpels. *Procedia CIRP*. 2016;45:199-202.
8. Ji Y, Yang K, Peng S, Chen S, Xiang B, Xu Z, et al. Kaposiform haemangi endothelioma: clinical features, complications and risk factors for Kasabach-Merritt phenomenon. *The British journal of dermatology*. 2018;179(2):457-63.
9. Amaral MB, de Avila JM, Abreu MH, Mesquita RA. Diode laser surgery versus scalpel surgery in the treatment of fibrous hyperplasia: a randomized clinical trial. *International journal of oral and maxillofacial surgery*. 2015;44(11):1383-9.
10. Tao S, Li L, Yuan H, Tao S, Cheng Y, He L, et al. Erbium Laser Technology vs Traditional Drilling for Caries Removal: A Systematic Review with Meta-Analysis. *The journal of evidence-based dental practice*. 2017;17(4):324-34.
11. Dionysopoulos D, Strakas D, Koliniotou-Koumpia E, Koumpia E. Effect of Er,Cr:YSGG laser irradiation on bovine enamel surface during in-office tooth bleaching ex vivo. *Odontology*. 2017;105(3):320-8.
12. Kumar M, Sarin, S. K. . Biomarkers of diseases in medicine. *Current Trends in Science*. 2009;Platinum Jubilee Special 403–17.
13. Patel S, Maheshwari A, Chandra A. Biomarkers for wound healing and their evaluation. *Journal of wound care*. 2016;25(1):46-55.
14. Protasio ACR, Galvao EL, Falci SGM. Laser Techniques or Scalpel Incision for Labial Frenectomy: A Meta-analysis. *Journal of maxillofacial and oral surgery*. 2019;18(4):490-9.
15. Azevedo A-S, Monteiro L-S, Ferreira F, Delgado M-L, Garcês F, Carreira S, et al. In vitro histological evaluation of the surgical margins made by different laser wavelengths in tongue tissues. *Journal of clinical and experimental dentistry*. 2016;8(4):e388-e96.
16. Monteiro L, Delgado ML, Garces F, Machado M, Ferreira F, Martins M, et al. A histological evaluation of the surgical margins from human oral fibrous-epithelial lesions excised with CO2

- laser, Diode laser, Er:YAG laser, Nd:YAG laser, electrosurgical scalpel and cold scalpel. *Medicina oral, patologia oral y cirugia bucal.* 2019;24(2):e271-e80.
17. Cercadillo-Ibarguren I, España-Tost A, Arnabat-Domínguez J, Valmaseda-Castellón E, Berini-Aytés L, Gay-Escoda C. Histologic evaluation of thermal damage produced on soft tissues by CO₂, Er,Cr:YSGG and diode lasers. *Medicina oral, patologia oral y cirugia bucal.* 2010;15(6):e912-8.
18. Perussi LR, Pavone C, de Oliveira GJ, Cerri PS, Marcantonio RA. Effects of the Er,Cr:YSGG laser on bone and soft tissue in a rat model. *Lasers in medical science.* 2012;27(1):95-102.
19. Giannelli M, Formigli L, Bani D. Comparative evaluation of photoablative efficacy of erbium: yttrium-aluminium-garnet and diode laser for the treatment of gingival hyperpigmentation. A randomized split-mouth clinical trial. *Journal of periodontology.* 2014;85(4):554-61.
20. Cayan T, Hasanoglu Erbasar GN, Akca G, Kahraman S. Comparative Evaluation of Diode Laser and Scalpel Surgery in the Treatment of Inflammatory Fibrous Hyperplasia: A Split-Mouth Study. *Photobiomodulation, photomedicine, and laser surgery.* 2019;37(2):91-8.
21. Shah JM, Omar E, Pai DR, Sood S. Cellular events and biomarkers of wound healing. *Indian journal of plastic surgery : official publication of the Association of Plastic Surgeons of India.* 2012;45(2):220-8.
22. Gohel MS, Windhaber RAJ, Tarlton JF, Whyman MR, Poskitt KR. The relationship between cytokine concentrations and wound healing in chronic venous ulceration. *Journal of Vascular Surgery.* 2008;48(5):1272-7.
23. El Ayadi A, Herndon DN, Finnerty CC. 21 - Biomarkers in Burn Patient Care. In: Herndon DN, editor. *Total Burn Care (Fifth Edition): Elsevier;* 2018. p. 232-5.e2.
24. Gupta A, Kumar P. Assessment of the histological state of the healing wound. *Plast Aesthet Res.* 2015;2:239-42.
25. Sultana J, Molla M, Kamal M, Shahidullah M, Begum F, Bashar A. Histological differences in wound healing in Maxillofacial region in patients with or without risk factors. *Bangladesh Journal of Pathology.* 2009;24.
26. Sinha UK, Gallagher LA. Effects of steel scalpel, ultrasonic scalpel, CO₂ laser, and monopolar and bipolar electrosurgery on wound healing in guinea pig oral mucosa. *The Laryngoscope.* 2003;113(2):228-36.