

## New technique for microscopical examination of the powdered dental materials with transmitted light microscope by using "Taha Indicator"

Lamia T REJAB\*

### ABSTRACT

The aim of this study is to examine the physical form of the powder particles of the dental materials by microscopical examination.

Dried powder can't be examined microscopically with ordinary transmitted light microscope, but need special microscope like reflected light microscope or electron microscope

In this study a new technique for microscopical examination of the powder particles was performed with transmitted light microscope by using a special indicator named "Taha Indicator"

The technique is easy, cheap and give clear and accurate image of the powder particles, so it can be used in studies and researches as a method for evaluation, comparison and differentiation between the different types of the material, it has a great benefit for the industration and in discovering the industrial deceit of dental materials.

**Key Words:** Microscopical examination, light microscope, powder particles, Taha Indicator.

### الخلاصة

هدف البحث هو دراسة وفحص الشكل الفيزيائي لباوورات او جزيئات مساحيق المواد السنية الجافة بواسطة الفحص المجهرى وحيث انه لا يمكن اجراء الفحص المجهرى للمسحوق الجاف بواسطة مجهر الضوء النافذ الاعتيادي فانه يحتاج الى مجهر خاص مثل مجهر الضوء المنعكس او المجهر الالكتروني. ففي هذه الدراسة تم اتباع طريقة جديدة للفحص المجهرى غير معان عنها مسبقا باستخدام مجهر الضوء النافذ الاعتيادي مع استعمال كاشف سمي (كاشف تاه).  
تمتاز هذه الطريقة بكونها جديدة ، سهلة ، بسيطة التنفيذ وغير مكلفة واعطت نتائج وصور واضحة ودقيقة للشكل الفيزيائي لجزيئات المساحيق الجافة.  
ولهذه الطريقة فوائد في مجالات البحث والدراسة وفي عمليات التقييم والمقارنة والتفريق بين انواع المواد والتي يمكن الاستفادة منها في عملية التصنيع والكشف عن الغش الصناعي لهذه المواد.

---

\*Lamia Taha REJAB; BDS, MSc: Assistant Lecturer. Department of Prosthetic Dentistry, College of Dentistry, University of Mosul, Mosul, IRAQ.

## INTRODUCTION

It is important to the dentist and dental technician to be protected from unsuitable products or materials, which have not been thoroughly evaluated. There are many tests used to evaluate the chemical composition and physical properties of dental materials, which have been shown to correlate with clinical performance<sup>(1,2)</sup>.

The physical forms of the powder particles of the dental materials affect the physical and mechanical properties of the materials<sup>(3,4)</sup>. A microscopical examination is performed to examine the physical form of the powder particles.

Dried powder can not be examined with ordinary transmitted light microscope since in practice with axial illumination, two points any closer together than about half the wave length of the light can not be resolved, so microscopical examination of the dried powder particles need special microscope like reflected light microscope or electron microscope and this with necessity for photographic recording makes the examination procedure expensive and complicated<sup>(5)</sup>.

In this study a new technique of the microscopical examination of the dried powder particles was performed with ordinary transmitted light microscope by using a special indicator named "Taha Indicator".

"Taha Indicator" is a transparent fluid oil, it is an available Iraqi petroleum products, ordinarily it is used as a lubricant oil for sewing machine.

## MATERIALS AND METHODS

Different powdered dental materials were examined in this study which were gypsum product dental stone (Selenor, Italy), hot care acrylic resin polymer powder (Quayle-Dental, England), alginate impression powder (Alginmax, Italy), Pumice (Whipmix, Corp, USA) and Zinc cement base (Dori Don't, Austria).

The specimens were prepared by mixing about (1) mg of dried powder with drop of "Taha Indicator" on glass slide, the mixture should not be too dense, otherwise there is excessive number of the particles scatter the light, the mixture was covered with coverslip, then examined and photographed with transmitted light microscope (Olympus BH<sub>2</sub>, Microphotograph-Japan) at (X 400).

## RESULTS AND DISCUSSION

The results of the microscopical examination of the dried powdered dental materials in this study are shown in figure (1) through figure (6).

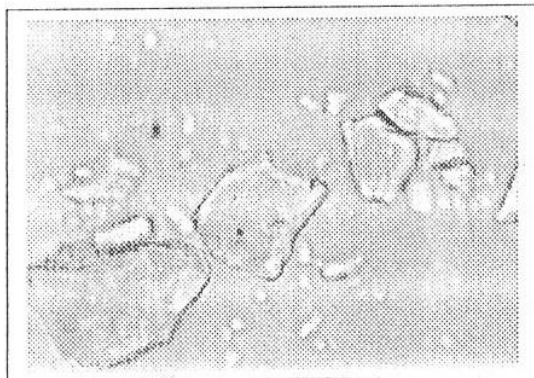


Figure (1): Dental stone particles (X 400)

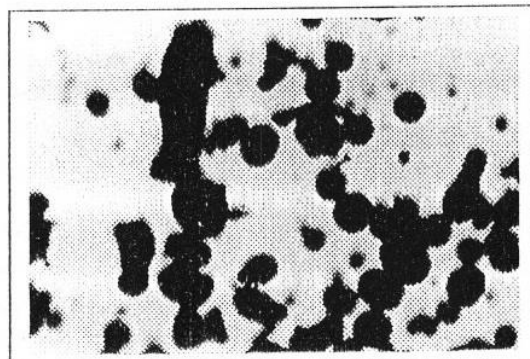


Figure (2): Amalgam alloy particles (X 400)

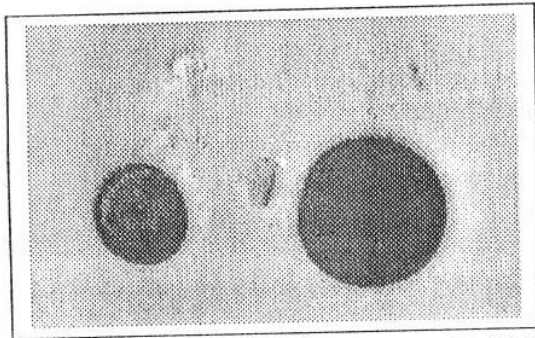


Figure (3): Acrylic resin polymer (X 400)

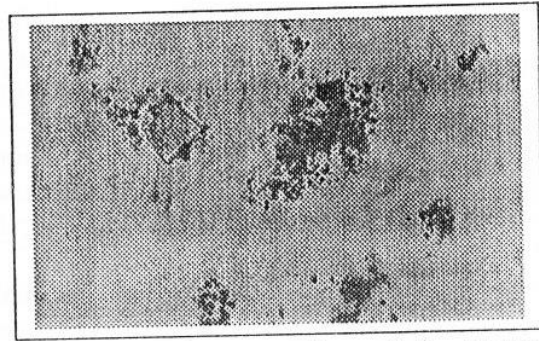


Figure (4): Alginate powder particles (X 400)

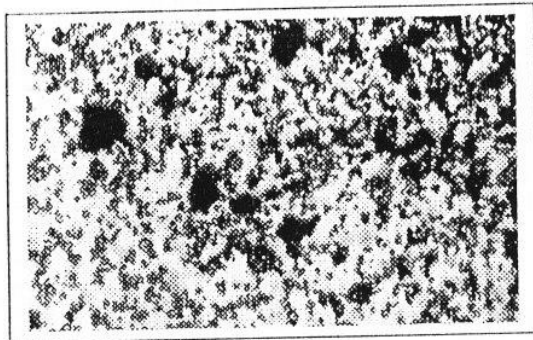


Figure (5): Zinc cement powder (X 400)

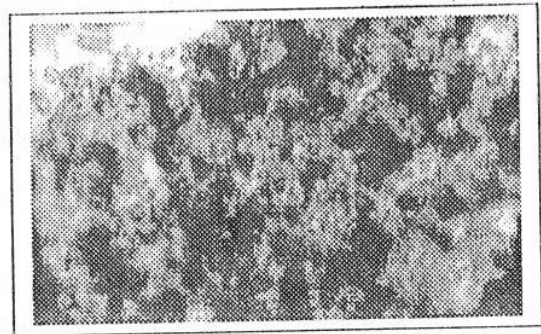


Figure (6): Pumice powder (X 400)

Figure (1) shows the typical form of the dental stone particles ( $\alpha$ -calcium sulphate hemihydrate) which are dense regular and prismatic shape<sup>(2,3,6)</sup>.

Figure (2) shows the spheroidal and lath-cut shape particles of the amalgam alloy powder<sup>(2,4)</sup>.

Figure (3) shows the spherical shape of the hot cure acrylic resin polymer powder peals<sup>(4,7)</sup>.

Figure (4) shows the crystals of the gypsum (calcium sulfate dihydrate) that represent one constituent of the alginate impression powder mixed with amorphous mass that represent other constituents of the powder<sup>(2,4)</sup>.

Figure (5) shows mixture of the ting crystals and amorphous mass that represents the ingredients of the zinc cement base.

Figure (6) shows ting crystals among amorphous mass which represent the elements of the pumice.

From the results of this study we can state that the new technique of the microscopical examination of the dried powder with transmitted light microscope by using "Taha Indicator" give clear and accurate image of the physical form of the powder particles.

The explanation of the action of "Taha Indicators" is that, the indicator chemically is one type of saturated cyclic hydrocarbones known as alkanes or cycloalkanes, which are relatively inert, ordinarily do not react with most common acids, bases or oxidizing or reducing agents<sup>(8)</sup>. So when the indicator mixed with dried powder it dose not react with it, but it act as medium for the powder particles aids them to separate from each other and helps them to spread a way by its flow character, so by this way, and because it is a transparent fluid, it permits the light of

the transmitted light microscope to pass through and between the particles of the powder, this aids to give clear and accurate image of the powder particles.

From experimental trials in this study other transparent fluids can be used with some variation and limitation, examples of these fluids are:

- 1-Cedar oil that used with oil immersion objective, this oil when dried it becomes difficult to remove from the lens, and it is more expensive<sup>(5)</sup>.
- 2-Cooking vegetable fluid oil, like olive oil or sunflower oil, but it is more expensive.
- 3-Water can be used with some dental materials like amalgam alloy and acrylic resin polymer powders but can not be used with other materials like gypsum products (dental plaster and stone), alginate impression powder, and cement base powder since water chemically react with them, also when water mixed with pumice it dose not react with it but the mixture becomes muddy like mass so it can not be examined microscopically.
- 4-Alcohol, although it is not react with some dental materials powder like amalgam alleys powder and acrylic resin polymer we can not used it for this examination since the cement that unites the component lenses may be soluble in alcohol and consequence the lens system may become disorganize and the objective spoiles<sup>(5)</sup>.

## CONCLUSION AND SUGGESTION

In this study a new technique for microscopical examination of the physical form of the dried powdered particles of the dental materials was performed with transmitted light microscope by using "Taha Indicator". This technique characterized by the following:

- 1-It is simple, easy and not expensive.
- 2-Give accurate and precise results.
- 3-Can be used in the studies and researches as a method of evaluation, comparison and differentiation between the types of the dental materials and or any other dried powdered materials.
- 4-Has great useful in the procedures of the industration and also in the discovering the industrial deceit of the materials.

## REFERENCES

- 1-American Dental Association Specification. Guide to Dental Materials and Devices. 1974-1975.
- 2-McGabe JF. Anderson's Applied Dental Materials. 6<sup>th</sup> Edn. Blackwell Scientific Publication. 1985.
- 3-Combe EC, Smith DC. Some properties of gypsum plasters. *Br Dent J.* 1964; 117 (6): 237-242.
- 4-Skinner EW. Science of Dental Materials. 8<sup>th</sup> Edn. WB Saunder Co. 1982.
- 5-Duguid JP. Medical Microbiology. 12<sup>th</sup> Edn. Vol 2. The Practice of Medical Microbiology. Churchill Livingston, 1975.
- 6-Carig RG Restorative Materials. 10<sup>th</sup> Edn. Mosby Co. 1997.
- 7-Anusavice KJ Philip's Science of Dental Materials. 10<sup>th</sup> Edn. WB Saunder Co. 1996.
- 8-Hart H. Organic Chemistry. 7<sup>th</sup> Edn. Houghton Mifflin Co. 1987.

## Anterior and middle superior alveolar block anesthesia as a supplementary new anesthetic technique during endodontic surgery for upper anterior teeth

Fa'iz A AL-SULTAN\*

### ABSTRACT

In this study, a total of (36) patients who need endodontic surgery for upper anterior teeth were participated. Patients divided randomly into (2) groups; group "A" in which each patient received a supplementary anterior and middle superior alveolar nerve block injection (AMSA) and infiltration anesthetic (supra-periosteal) injection of total (4.25) ml of anesthetic solution; and group "B" in which each patient received infiltration anesthesia alone of the same amount and the same anesthetic solution used for group "A".

The results of the study showed a significantly less pain grade assessed during surgery in group "A" compared to group "B". The difference in pain grade when estimated in relation to the number of teeth treated or in relation to the duration of surgery showed to be not significantly differed from each other. Although good hemostasis was achieved in group "B" in higher percentage comparing to group "A", this difference was not statistically significant.

In conclusion, anterior and middle superior alveolar nerve block injection showed to produce good pain reduction as a supplementary anesthetic technique during endodontic surgery.

**Key Words:** Endodontic surgery, anterior and middle superior alveolar nerve block.

### الخلاصة

شارك في هذه الدراسة (36) مريض يحتاجون إلى عمليات معالجة لبيبة جراحية لأسنان علوية أمامية. قُسم المرضى إلى مجموعتين، المجموعة "أ" وكل مريض فيها أعطي تخدير حاجز للعصبين الأمامي والوسطي العلوي السنخي إضافة للتخدير بالارتشاح موضعياً بكمية مخدر هي (4,25) مل زاييلوكالين (2%) مع أدريبالين (1:80000). أما المجموعة "ب" فأعطي كل مريض فيها تخدير بالارتشاح حول الأسنان بنفس كمية المخدر ونفس النوع.

أظهرت النتائج ملاحظة شدة ألم خلال العمل الجراحي أقل عند المجموعة "أ" من المجموعة "ب"، وكان هذا الاختلاف معنوياً عند ( $p < 0.05$ ). كان الفرق بدرجات الألم بين المجموعتين عند مقارنته بعدد الأسنان المعالجة لبيبة وكذلك حسب طول فترة العملية الجراحية غير معنوياً عند المجموعتين. كانت السيطرة على النزوح الدموي جيدة بنسبة أعلى عند المجموعة "ب" منها في المجموعة "أ" لكن هذا الفرق لم يكن معنوياً.

نستنتج من هذه الدراسة أن استخدام طريقة التخدير الحاجز للعصب الأمامي والوسطي السنخي العلوي هي طريقة فعالة لتقليل شدة الألم وللحصول على تخدير جيد كطريقة إضافية لطريقة الارتشاح خلال العمل الجراحي اللبي.

\* Fa'iz Abdul-Razzak AL-SULTAN; BDS, MSc: Assistant Lecturer. Department of Oral and Maxillofacial Surgery, College of Dentistry, University of Mosul, Mosul, IRAQ.

## INTRODUCTION

During endodontic surgery, it is essential that anesthesia being profound and for prolonged period of time to facilitate surgical procedure and minimize post-operative sequelae <sup>(1)</sup>. Supra-periosteal infiltration anesthetic technique is the recommended anesthetic technique for endodontic surgery to provide anesthesia as well as hemostasis in the upper anterior region <sup>(2)</sup>. Sometimes, this technique prove to be inadequate due to presence of infection that increase acidity at injection site which inhibit intra-neuronal passage of local anesthetic solution <sup>(3,4)</sup>. It also may fail due to long root or dens cortical bone <sup>(5)</sup>. Also, infiltration technique may fail on re-injection to re-establish surgical anesthetic in prolonged procedure due to release of inflammatory mediator at operation site which reduce pain threshold and produce vasodilation that increase blood flow to the site and increase systemic absorption of local anesthesia and the end result reduce the duration of local anesthesia at site of re-injection <sup>(2)</sup>.

Studies focused to use block technique to overcome these problems and infra-orbital technique estimated <sup>(6)</sup>. On the other hand, this technique has limited uses because of poor dentist experience, fear of ocular complications and high percentage of failure <sup>(7)</sup>. Therefore, it becomes necessary to search for a block technique during endodontic surgery for maxillary anterior teeth that is serve as a supplementary technique to infiltration (since hemostasis can not achieved by block technique) <sup>(2)</sup>.

A technique for block anesthesia of anterior and middle superior alveolar (AMSA) nerve through palatal approach was developed in (1997). Although it was recommended to be used by special electronic system called (The Wand), this technique proved to be successful in conservative dentistry as primary injection technique utilizing ordinary dental syringe and ultra-short dental needle <sup>(8)</sup>. This technique based on the fact that the bone of palate at premolar region represents nearest point to the anterior wall of maxillary sinus through which anterior and middle superior alveolar nerve pass. Injection of adequate amount of anesthetic solution at that site supra-periosteally will penetrate deeply to cause anesthesia for both nerves. The landmark for the injection therefore is not an exact foramen, but rather a region located midway between maxillary premolars and approximately midway between palatal suture and free gingival margin (figure 1).

The basic component is to make injection of anaesthetic solution maintained regularly with slow rate and (1.8) ml of solution used. Since palatal mucosa has adequate elasticity to maintain solution in contact with bone deeply. This ensures penetration of solution through palatal bone to reach neural tissue and blood vessel without being absorbed by soft tissue of the palate. So it is clinically as intra osseous injection <sup>(9)</sup>.

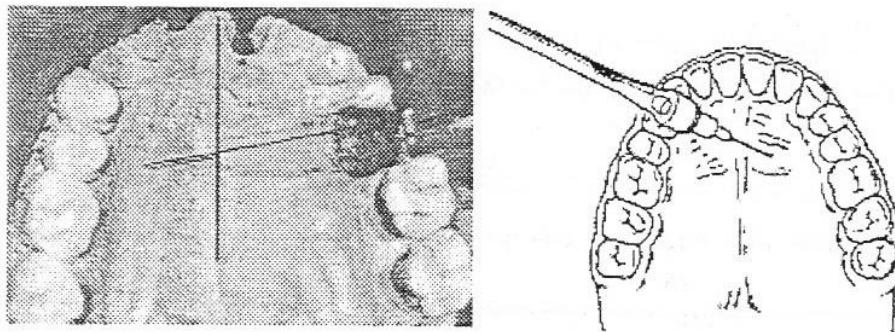


Figure (1): Anatomical landmarks for AMSA injection



Grade A: No pain completely during operation.

Grade B: Mild to moderate pain that is tolerable by patient.

Grade C: Severe pain that is intolerable and additional anesthesia needed.

In this case, intra-lesional infiltration or additional AMSA block was administered according to the same initial injection utilized.

- ⊕ Degree of Hemostasis Obtained during Operation assessed by operator subjectively who gave one of either statements: poor or good hemostasis.
- ⊕ Immediate and Late Complication that is related to the local anesthesia.

All the surgical procedures and anesthetic administration were performed by the same operator to avoid inter-operator variance.

Statistical analysis performed utilizing Chi-square test to determine the significance of difference between groups at ( $p < 0.05$ ) level.

## RESULTS

In this study (36) patients were participated. The mean age of patients was ( $24.6 \pm 8.7$ ) years (range = 10–45). Ratio of male : female was (1 : 1.57). Of patients participated (12) had (2) teeth to be treated and (24) patients had only single tooth. The indication of surgery includes: large apical radiolucency with limited treatment time available in (19) patients, large apical radiolucency with well circumscribed border raising the suspect of apical radicular cyst that need enucleation in (10) patients whereas in the remaining (7) patients re-treatment of failed conventional non-surgical endodontic therapy was performed surgically. Table (1) shows the number and percentage of different age groups.

Table (1): Number and percentage of different age groups in the study

Age (Years)	Number	%
<15	9	25
15–25	21	58
>25	6	17

The onset of anesthesia recorded in group “A” was ( $2:36 \pm 94$ ) seconds compared to ( $2:05 \pm 87$ ) seconds for group “B” with no statistical significant difference between both groups ( $t = 1.86$ ;  $d.f = 30$ ).

Pain grade recorded during surgery for both groups were as follow:

Grade A: Pain score reported in (61%) of patients in group “A” and (45%) of patients in Group “B”.

Grade B: Pain score reported in (28%) of patients in group “A” and (33%) of patients in group “B”.

Grade C: Pain score reported in (11%) of patients in group “A” and (22%) of patients in group “B” (table 2 and figure 2).



Table (2): Number and percentage of patients in both groups according to different pain grades

Pain Grade		AMSA	Infiltration	Total
A	No.	11	8	19
	%	61	45	52
B	No.	5	6	11
	%	28	33	31
C	No.	2	4	6
	%	11	22	17
Total		18	18	36

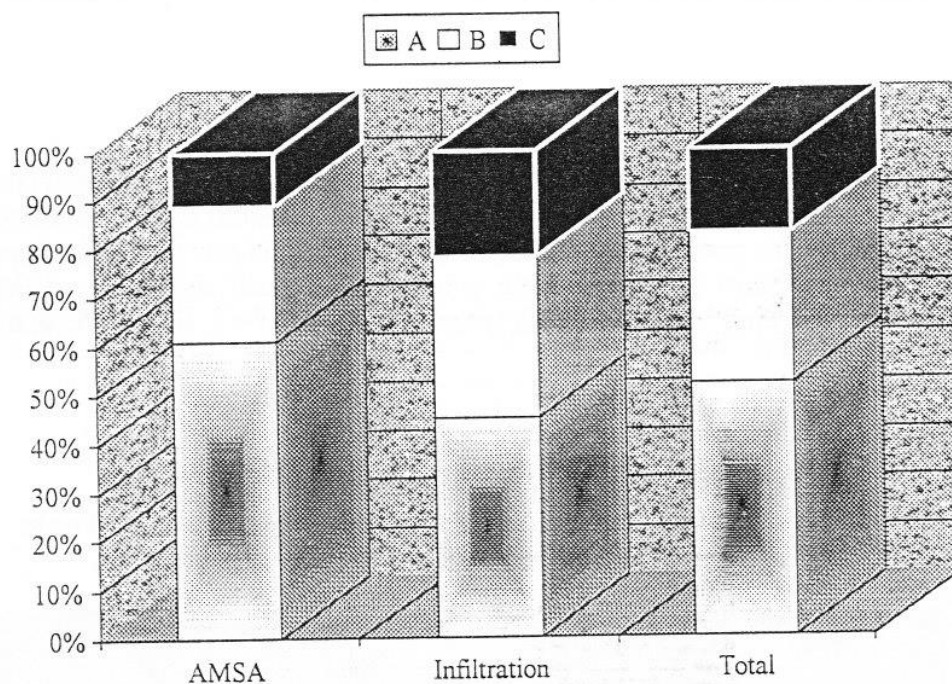


Figure (2): Percentage of patients in both groups according to different pain grades

These differences in pain scale recorded in both groups showed to be statistically significant at ( $p < 0.05$ ) using Chi-square test ( $\chi^2 = 6.157$ ; d.f = 2).

Pain grade assessment in both groups comparing single tooth treatment with (2) teeth showed no statistical significant difference (table 3). Also, no statistical significant difference noticed in pain grade assessment in operations performed on single tooth in both groups as well as no such significance showed in operation performed on (2) teeth in both groups ( $\chi^2 = 2.62$ ; d.f = 2; and  $\chi^2 = 4.8$ ; d.f = 2 respectively).

Table (3): Number and percentage of patients in both groups according to number of teeth treated and different pain grades

Pain Grade	AMSA		Infiltration		Total		
	1 Tooth	2 Teeth	1 Tooth	2 Teeth	1 Tooth	2 Teeth	
A	No.	7	4	5	3	12	7
	%	54	80	46	42	50	58
B	No.	4	1	4	2	8	3
	%	31	20	36	29	33	25
C	No.	2	/	2	2	4	2
	%	15	0	18	29	17	17
Total		13	5	11	7	24	12
$\chi^2$		2.29		0.311		1.71	

Pain grade assessment in both groups comparing duration of operation (shorter than 30 minutes or 30 minutes and longer) showed no statistical significant difference (table 4). Also, no statistical significant difference noticed in pain grade assessment in operation with short duration in both groups and no such significance noticed in operation with long duration in both groups ( $\chi^2 = 2.19$ ; d.f = 2; and  $\chi^2 = 5.16$ ; d.f = 2 respectively).

Table (4): Number and percentage of patients in both groups according to duration of surgical operation and different pain grades

Pain Grade	AMSA		Infiltration		Total		
	<30	>30	<30	>30	<30	>30	
A	No.	5	6	4	4	9	10
	%	50	75	58	36	53	53
B	No.	4	1	2	4	6	5
	%	40	12.5	28	36	35	26
C	No.	1	1	1	3	2	4
	%	10	12.5	14	28	12	21
Total		10	8	7	11	17	19
$\chi^2$		2.93		2.6		5.67	

Concerning hemostasis, good records were achieved in (55%) of patients in group "A" compared to (72%) of patients in group "B". However, this difference is of no statistical significance ( $\chi^2 = 0.48$ ; d.f = 1) (table 5).

Table (5): Number and percentage of patients for both injection techniques according to hemostasis achieved during operation

Hemostasis		AMSA	Infiltration	Total
Good	No.	10	13	23
	%	55	72	63.89
Poor	No.	8	5	13
	%	45	28	36.11
Total		18	18	36

The complications recorded in both groups were as follows (table 6).

Table (6): Post-operative complications of anesthesia

Complication	Group "A"	Group "B"
Pain During Injection	8	5
Swelling	2	10
Ecchymosis	1	1
Bleeding at Injection Site	2	3
Failure to Achieve Anesthesia	2	4
Pain at Injection Site	2	5

## DISCUSSION

A higher success rate of local anesthesia was achieved in group of patients received supplementary AMSA technique compared to group received infiltration technique alone. This may reflect the value of remote block technique that did not affected or minimally affected by inflammatory mediator produced by surgery at injection site. This result agree with Malamed who stated that injection at inflamed site may fail due to hypernatremia, acidic pH and inflammatory mediator that may reduce pain threshold <sup>(2)</sup>. However, other studies showed that the effect of inflammation not limited to the infection site but may extend to involve entire nerve trunk so that nerve block fail to provide additional anesthesia for inflamed site <sup>(3, 12, 13)</sup>.

The enhancement of the effectiveness of local anesthesia by remote block in this study may be explained as that the inflammatory mediator at operation site still not exert a change on the entire nerve trunk as short time elapsed for such reaction. Also, slow rate of diffusion of local anesthesia in this technique may play a role on its successfulness in providing profound anesthesia in endodontic surgery as recommended by Harrison <sup>(2)</sup>.

Although no significant difference in onset for achieving anesthesia in both groups noticed but it could be stated that delayed onset obtained in group received block injection compared to group received infiltration anesthesia alone <sup>(8)</sup>. However, in group injected by AMSA block the delayed onset fastened by additional infiltration technique that mask the results.

For determination of the effects of different variables on the efficacy of anesthetic technique performed, two factors were observed including number of teeth treated and duration of operation (other factors such as type of operation and size of lesion were not considered but they were indirectly estimated as their effect on duration of operation is clear) <sup>(2)</sup>.

Although no statistical significant difference was noticed among different groups according to the duration of operation and number of teeth treated for both groups, however we can observe a higher percentage of successful anesthesia in patient having (2) teeth who received AMSA block (80%) compared to (42%) success rate recorded in patients having (2) teeth and received infiltration anesthesia with same amount of anesthetic solution. Also high success rate observed in prolonged procedure lasting more than (30) minutes when patients received AMSA block (75%) compared to (36%) success rate recorded in patients received infiltration anesthesia alone and on whom the operation also lasts for more than (30) minutes. Such observation may raise the suspect that the summation effects of duration of operation and number of teeth may be the dependent variable affected by the different injection technique and increasing successfulness of anesthesia in patients receiving AMSA block technique.

Other important point in endodontic surgery is the need for good hemostasis for good control of operation site and performance of root end filling <sup>(1)</sup>. Since block anesthesia does not offer any hemostatic effect <sup>(15)</sup>, one expect that the group injected with AMSA technique had lower percentage of good hemostasis (55%) compared to group received infiltration anesthesia of the same amount of solution in which good hemostasis recorded in (72%). Although this result was not statistically significant but small sample size may be the cause for such observation. To overcome this problem we can recommended to increase the amount of solution injected for operation in which AMSA block performed. This is not problem in adult since a wide margin between injected dose (4.25) ml and maximum recommended dose which is about (15) ml of (2%) Lidocaine solution <sup>(2,7)</sup>. However, in child and patients with cardiac problem, this dose is closest to the maximum recommended dose for those with (25) Kg weight and therefore increasing the dose to achieve hemostasis which is poorly achieved after AMSA block may bring a patient to the risk of developing systemic reaction and side effect of toxicity <sup>(15)</sup>. Since child represent a large group of our patients requiring endodontic surgery it produces a large limitation to this injection technique since about (25%) of our patients in this study were below (15) years of age (table 1).

For the complications recorded, it is of interest to notice the reduction in percentage of pain during injection noticed comparing to previous study. This reduction may be attributed to the use of topical anesthetic gel (1) minute before injection that may reduce pain of injection. Other recorded complications are of no significant difference between both groups and presence of pain and swelling at injection site post-operatively especially in group received infiltration anesthesia may be due to the effect of surgery itself and not to the injection whereas in group received AMSA injection side effect at injection site for AMSA -i.e., palatally- were only recorded.

In conclusion, this injection technique proves to be effective as a supplementary injection technique for endodontic surgery in upper anterior teeth especially when prolonged procedure or multiple teeth involved. However, it is not recommended to be used for children and patients with cardiac problem to avoid the need for exceeding the maximum recommended dose of local anesthetic solutions.

## REFERENCES

- 1) Gutmann JL, Harrison JW. Surgical Endodontics. 1<sup>st</sup> Edn. All Indian Publisher and Distributer. 1999: 63-66, 154-162.
- 2) Malamed SF. Handbook of Local Anesthesia. 4<sup>th</sup> Edn. CV Mosby Co. 1997: 15-17, 232-235.
- 3) Brown RD. The failure of local anesthesia in acute inflammation. Some recent concepts. *Br Dent J*. 1981; 151: 47-51.
- 4) Ritchie JM, Ritchie B, Greengard P. The active structure of local anesthetics. *J Pharmacol Exp Ther*. 1965; 150: 152-159.
- 5) Kaufman E, Weinstein P, Milgrom P. Difficulties in achieving local anesthesia. *J Am Dent Assoc*. 1984; 108: 205-208.
- 6) Fathie WKh. A comparative evaluation on the effectiveness of infiltration and infraorbital nerve block technique of local anesthesia in periapical surgery on maxillary anterior and premolar teeth. *Al-Rafidain Dent J*. 2002; 2(1): 120-127.
- 7) Jastak JT, Yagiela JA, Donaldson D. Local Anesthesia of the Oral Cavity. 1<sup>st</sup> Edn. WB Saunders Co. 1995.
- 8) Al-Assaf QH, Abdul-Mawjood AA, Al-Sultan FA. Anterior and middle superior alveolar block anesthesia: A new technique estimated. *Al-Rafidain Dent J*. 2002; 2(1): 56-64.
- 9) Friedman MJ, Hochman MN. The AMSA injection. A new concept for local anesthesia of maxillary teeth using a computer controlled injection system. *Quintessence Int*. 1998; 29(5): 297-303.
- 10) Agren E, Danelson K. Conduction block analgesia in the mandible. A comparative investigation of the technique of Fischer and Gow Gates. *Swed Dent J*. 1981; 5: 81-84.
- 11) Dobb EC, Devier CL. Arterenol as vasoconstrictor in local anesthesia. *J Am Dent Assoc*. 1950; 40(4): 433-434.
- 12) Wallace JA, Michanowice AE, Mundell RD, Wilso EG. A pilot study of the clinical problem of regionally anesthetizing the pulp of an acutely inflamed mandibular molar. *Oral Surg*. 1985; 59: 517-521.
- 13) Najjar TA. Why can't you achieve adequate regional anesthesia in the presence of infection? *Oral Surg*. 1977; 44: 7-13.
- 14) McDonald RE, Avery DR. Dentistry for the Child and Adolescent. 6<sup>th</sup> Edn. CV Mosby Co. 1997: 294-306.
- 15) Bennett CR. Monheims Local Anesthesia and Pain Control in Dental Practice. 7<sup>th</sup> Edn. St Louis. CV Mosby Co. 1984: 181-182.