

Laparoscopic and open varicocelectomies advantages and disadvantages with subsequent Fertility recovery results



Ass. Prof. Dr. Suhel M. Najjar¹

Abstract

Background and Objectives:

With laparoscopic varicocelectomy (LVV) invention, controversial ideas are developed regarding choosing the preferable method for surgical management of varicocele; accordingly, various comparative studies are required to evaluate safer and more productive technique. This study is aimed in observation of validity of both laparoscopic and inguinal open methods and their efficiency in producing fruitful male fertility progression.

Cases and methods:

This study is performed in a period of one-year (2017-2018), during which (60) cases of infertility due to varicocele pathophysiological consequences collected by simple random method. Of these (32) cases were laparoscopically managed (Group 1) and the other (28) cases managed by open inguinal method (Group 2). In these patients the basal spermatoc analysis performed the parameters were below normal values. The presences of varicoceles were proved clinically and by ultrasound Doppler studies. The varicocelectomy operations for non-fertile purposes were excluded from study. The follow up carried on two monthly intervals for next (6) months by clinical examinations, US and BSA. Statistically SPSS version package 24 is used; presented data are used.

Results:

The included ages were (24 to 43) years. In (51) cases only left side and in (9) cases were bilateral (VV). Postoperative follow up showed an acute rising of motility and quality of sperms after 4-8 weeks period among laparoscopic group and reached minimum normal level at the end of 24 weeks and 9 (28.13%) cases achieved conception in the first year. In the

¹ **Consultant Surgeon, Surgical Anatomist.** M. B. Ch. B., DGS (Consultant Surgeon), M. Sc. Anatomy, Ph.D. in Surgical Anatomy. Hawler Medical University, College of Medicine, Department of Basic Sciences, Erbil & Department of Surgery Rizgary teaching hospital. Email: suhelnajjar6063@gmail.com

opened group the changes were slow and remained for 24 weeks to achieve wanted normal parameters and 11 (39.3%) cases achieved conception. Laparoscopic group operative duration was (42±5) minutes for unilateral and (60±8) minutes for bilateral, while in open group operation duration was (35± 5) minutes for unilateral and (50±5) minutes in bilateral. Regarding postoperative complications in laparoscopic group were; less painful, less disabling, least trauma, scars and complications.

Conclusions:

The laparoscopic varicocelectomy is promising method of treating varicocele for abnormal sperm parameters, uni or bilateral same ports approachability for especially in subclinical varicoceles. LVV was safer than open method from various points of but longer operation duration. However open group conceptive outcomes observed more beneficial than LVV.

Key words; varicocelectomy- inguinal - Laparoscopic. Fertility.

Introduction:

Infertility is one of the main health problems, supposed to attack (15%) of the couples in reproductive age. The male factor is involved in (40 – 50) % of infertility cases. Varicocele (VV) is a tortious enlargement or dilatation of the testicular veins in the scrotum. (VV) is a common cause of male infertility, which in a European study was found to affect (16.6%) of men referred for infertility (Kantartzi et al., 2007). Incidence of varicoceles in vast majority (60-70) % occurs in the left side more than right (Bebars et al., 2000; Ding et al., 2012).

Varicocelectomy is a surgery performed to ligate that worm like enlarged veins, It's by far the most commonly performed surgery for the treatment of male infertility (Ding et al., 2012). The goal of treatment of the varicocele is to obstruct the refluxing venous drainage to the testis while maintaining arterial and lymphatic

supplies, or to restore normal physiological blood flow to testes (Kantartzi et al., 2007; Ding et al., 2012). Accordingly, it was found that at least 50% of patients return to be fertile (Bebars et al., 2000; Ding et al., 2012).

Minimum normal basal sperm (BSA) analysis memorandum according WHO is 20/40/60 where 20 million is for sperms count, 40 percent is for minimum sperms motility and 60% for normal sperms percentage (Bebars et al., 2000; Ding et al., 2012). Clinically varicoceles are divided into three grades (I, II & III) depending on the prominence of dilated veins.

The three grades of VV are: Grade 1: The smallest type, this is not visible, but a physician can feel it if they use a Valsalva maneuver. Grade 2: This is not visible, but it can be felt without a Valsalva maneuver. Grade 3: The varicocele is visible. Another type is detected by radiography, called subclinical varicoceles, but not appreciated

on physical examination and no pathophysiological consequences observe on seminal fluid parameters (Eisenberg & Lipshultz, 2011; Vieira, 2013; Belay et al., 2016).

Pathological consequences of varicocele on the testis and the contained sperms quality are due to hyperemic and hyperthermic media which will be yielded after tortious dilation of testicular veins (Kantartzi et al., 2007; Eisenberg & Lipshultz, 2011; Belay et al., 2016; Flannigan et al., 2017).

The higher incidence of left varicocele and subfertility claimed to be due to anatomical, some pathophysiological and genetic factors (Eisenberg & Lipshultz, 2011; Vieira, 2013; Chiba & Fujisawa, 2016).

Not all the cases of varicoceles are symptomatic. Patients who search the treatment are mainly those who are complaining of primary or secondary infertility (Bebars et al., 2000; Flannigan et al., 2017). Not always the consequences of varicocele resulted in subfertility, as had been observed the frequent pregnancies of a couple with even grade II-III varicoceles male partners, anyhow the correction of varicoceles resulted in progression in the results of conceives (Eisenberg & Lipshultz, 2011; Vieira, 2013; Belay et al., 2016; Chiba & Fujisawa, 2016).

The pathophysiological causes of infertility caused by VV and mainly left

one explained on basis of hyperemic hyperthermia and toxic oxidants radicals to which faced the testicular tissues and consequently resulted in spermopathies (Eisenberg & Lipshultz, 2011; Chiba & Fujisawa, 2016; Belay et al., 2016; Wang et al., 2020).

Laparoscopic varicocelectomy was first introduced as an efficient treatment for male infertility in 1992 and within more than 2 decades of its invention, this laparoscopic technology is in controversial up and down fluctuation pattern of advantages on the other available techniques (Marte, 2018; Wang et al., 2020).

Aim of the study

This study is aimed to evaluate and draw a correct balance in between (LVV) and classical sub inguinal open varicocelectomy in views of better surgical advances and fertility improvement.

Cases and methods:

This retrospective study of operative and post-operative follow-up of varicocelectomies (Open sub-inguinal (OVV) and (LVV) for infertile male patients carried out from the period of 11 February 2017 to the end of 11 February 2018. The study included clinical examination, BSA, US for the abdomen and superadded by scrotal Doppler vascular study confirming, and another ultrasonography had been done after 2 months after operation as a follow up. For all the cases three different intervals basal

sperm analysis (BSA) performed according to WHO 2010 guidelines preoperatively and consequently as a follow up post operatively in 2-3 every two months.

Laparoscopic varicocelectomy was performed under general anesthesia with the patient in the supine position (20 degrees/Trendelenburg). Urinary bladder evacuated preoperatively. A direct laparoscope trocar inserted through transverse supra-umbilical (1 cm) incision and in (6 obese) cases this step was done by a Veress needle for the creation of pneumo-peritoneum. Carbon dioxide insufflation was maintained and the intra-abdominal pressure was kept between 11-13 mm³.

A 10-mm trocar was inserted through the umbilical incision, connected to the carbon dioxide insufflator, and a (0- angle) laparoscope was introduced into the peritoneal cavity. In all cases, the abdominal and pelvic viscera were examined in addition to the spermatic vessels and internal inguinal rings mainly on left side and superadded at the end to examination of right side in clinically significant cases. For unilateral varicoceles, the working ports consisted of two 5-mm ports were introduced through bilateral para-rectal area medial and inferior to mid McBurney's line. Surgeon on positioned the contralateral side of the (VV) using the working ports, while the

assistant camera- man was standing on the same side and behind, controlling the laparoscope. Lateral pelvic peritoneum excised and spermatic vessels identified. External testicular mild grasping pressure applied nearly in all cases to prove the varicoceles and to confirm the involved vessels moreover this step helped to distinguish the testicular artery. The vascular bundle was then carefully grasped after dissection of testicular artery in almost all of the cases. The (VV) bisected after application of (3-4) stainless steel clippers and endoscopic scissors. Small caliber collateral veins were observed parallel with main spermatic vein in few cases and ligated individually. At the end the abdominal cavity was evacuated, and the trocars were removed under vision. In most of the cases the sigmoid colon was the most problematic for disturbing of visualization field and interfering manipulating procedures especially in obese and adhesions of previously operated cases.

In the open cases we used old high inguinal approach a technique described by Palomo in 1969. In all the cases approximation of the tissues and the skin sutured by 2/0 vicryls. For statistical analysis paired sample t-test / SPSS version package 24 is used; presented data are used as Mean \pm STD. (P-value < 0.05) regarded significant.

Results:

This study planned for including subfertile cases mainly. The ages were (24 to 43) years and mean age was (33.5) years age. In nearly 51(85%) cases only left testis affected, while the remnant 9 (15%) cases were bilateral testes. Types of infertility divided into (26) cases of 2ary infertility and (34) cases of 1ary infertility. Grades of varicocele were distributed as the followings: 28 (46.6%) Grade III, 25 (41.6%) were GII and 7 (11.8%) cases were of GI. Duration of infertility arranged between 2-6 years. The mean duration of laparoscopic operation of unilateral varicocelectomy was 42 ± 5 minutes and 60 ± 8 minutes for bilateral cases. For open inguinal approach time duration was (35-50) minutes. As postoperative follow up; 3 patients had immediate per-abdominal

pain and restricted difficulty of respiration due to diaphragmatic peritoneal irritation by CO₂ for more than 2-3 hours which were relieved by muscle relaxants and analgesia, otherwise all the other cases were relaxed and comfortable. The rate of incisional pain was low in both groups as all had been injected by 5-10 ml Marcaine 0.75% at the end of the operation. Post-operative hematoma and hydrocele following open sub-inguinal method were significantly higher than the (LVV). The other details located in Table (1). Hernia sac and big lipoma observed in 2 cases of the open group, and sigmoid colon adhesion over lateral pelvic peritoneum observed by LVV. From the graph (Figure 1) most common grade presentation were grade III.

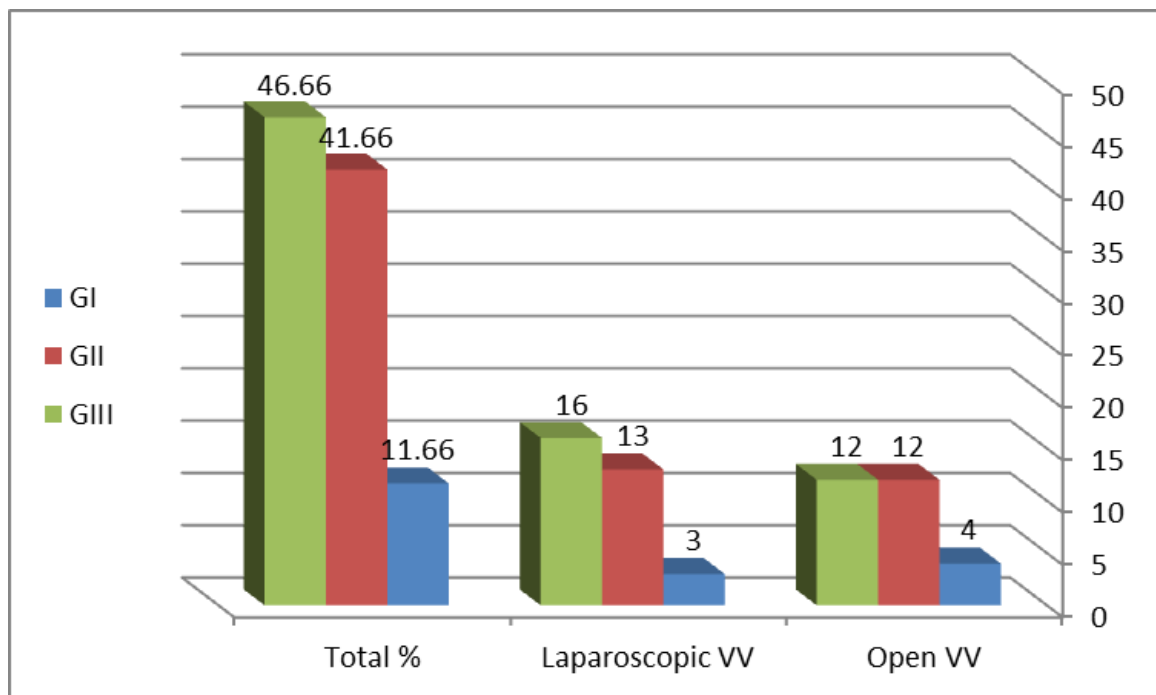


Figure 1: Distribution of the cases according grades of VV

Table 1: Duration of operation and recovery

Type of operation	Duration of operation by minutes		Recovery duration by days
Both	Unilateral	Bilateral	2-8
LVV	42±5	60±8	2-3
OVV	35± 5	50±5	5-6

From the Table 1 the longer operation time significantly observed in LVV group

Table 2: Both Laparoscope (GI) and open inguinal (GII) operative findings

Subjects	LVV	OVV	P-Value
Ages	(33.5)	(33.5)	Not fit
Side	(20) left (10) bilateral	(25) left (3) bilateral	0.0467
Wound infection	1 (3.2%)	4 (14.3)%	0.0492
Early hematoma	0	7 (25%)	0.0462
Latent hydrocele	1 (3.12%)	8 (28.6%)	0.0466
Testes atrophy	0	0	0
Additional findings	(2-3) Sigmoid adhesions with veins	(1) big lipoma and (1) hernia	Not fit
Pregnancy rate	9 (28.13%)	11 (39.3%)	0.0436

Postoperative significant collection of hematomata is observed in the scrotum and ended by hydrocele subsequently in (OVV) group which was nearly not present in (LVV) group (Table 2). Also, the BSA parameter changes were slow and more stable for producing better conceiving rate significantly in the OVV group, but faster and less stable and productive for (LVV) and the (P-Value was less than 0.05) (Table 3).

Table 3: sequences of BSA changes after operation

BSA	LVV	OVV	Comments
Type of Subfertility	14 /1ary 18 /2ndary	12 /1ary 16 /2ndary	
Pre-operation	Motility < 30% morphology < 4%	Motility < 30% morphology < 4%	

1st 6 weeks post	Motility:40% Morphology: 4%	Motility < 30% Morphology: 3%	Earlier arise to normal in the LVV
1st 12 weeks post op.	Motility 35% Morphology 4%	Motility 35-40% Morphology 5%	Drop-down in the LVV but arise to normal in OVV

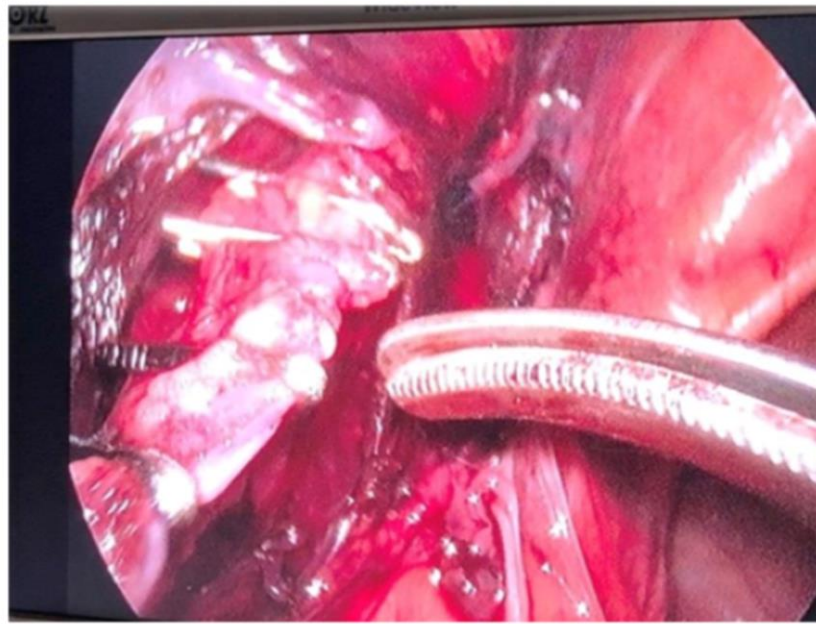


Figure 2: Metallic clips applied on both ends of bisected vein

Discussion:

As a varicocele is identified in 15% of healthy men and up to 35% of men with primary infertility, accordingly in this study two different techniques of infertile varicocelectomies handled for appoint more safety procedure and conceiving productive results. As mentioned in a study of epidemiology of vericocele by Bader Alsaikhan..et al. (2016); the exact pathophysiology of varicoceles is not very well understood, especially regarding its effect on male infertility. In this study

observed that due to pathophysiological and clinical consequences of prolonged duration VVs are a major cause of impaired spermatogenesis and deterioration of basal seminal parameters, but more commonly correctable causative factor in early periods of VV formation and causing infertility, as 9 (28.13%) of LVV and 11 (39.3%) of OVV were reversed conceived after operation by both methods (Kantartzi et al., 2007; Eisenberg & Lipshultz, 2011; Belay et al., 2016;

Alsaikhan et al., 2016; Chiba & Fujisawa, 2016).

In their study, Chiba & Fujisawa (2016) claimed that varicoceles can occur concomitantly with other conditions that cause impaired spermatogenesis. Further studies are necessary in order to identify the patients who are most likely to benefit from treatment. The pathophysiological facts emphasize that long duration VVs causes irreversible damages to the testes that even corrective operations yields no benefit for seminal parameters changes (Perry, 2001; Kantartzi et al., 2007; Chiba & Fujisawa, 2016) this had been supposed to be due to progression of adverse effect of varicocele on spermatogenesis which can be attributed to many factors such as an increased testicular temperature, increased intra-testicular pressure, hypoxia due to attenuation of blood flow, reflux of toxic metabolites from the adrenal glands and hormonal profile abnormalities (Kantartzi et al., 2007). Accordingly, we observed only 20 (33,4%) patients of this study cases got conceived after operation.

The sole inclusions for surgery in the study were the proved presence of clinical varicocele with subfertility seminal parameters, even when there was no complaint. This was based on the idea that early correction of varicocele will not only stop the progressive pathophysiological adverse changes but also will prevent

future infertility in younger male patients (Cohen, 2001; Perry, 2001; Chan, 2011).

The two different routes of surgery which had been used in this study, have a common factor together which is pathophysiological changes and the differentiating factor is the anatomical limitations, the pathophysiological both work to reverse progressing effects on the testes and seminal parameters which may cause failure of conceiving, while anatomical factor includes variability in approach one of which is that in OVV the abnormal aberrant veins which may be present which drains to the internal iliac veins can be handled and this is impossible in the LVV, same while by OVV there will be damages or obstruction in lymphatic ways by managing multiple veins in pampiniform plexus in the sub-inguinal region while in the LVV only single terminal testicular vein managed which will be easier and less complicated as it's near to the termination and entering left renal vein and lastly, collateral upper veins can be better managed by LVV (Cohen, 2001; Binsaleh & Lo, 2007; Borruto et al., 2010).

This anatomical arrangement postulation also had been booked by most of the researches as explaining that the left internal spermatic vein being is longer and enters the left renal vein at a right angle, whereas the right internal spermatic vein drains directly into the inferior vena cava and their consequences (Perry, 2001;

Kantartzi et al., 2007; Alsaikhan et al., 2016).

In other hand the documented explanations of causes of varicocele, with their pathophysiological consequences and recovery mechanism postoperatively with various results diversions are not clearly explained yet as VVs recognized in multiple studies may affects 40% of men with primary infertility and 80% of men with secondary infertility, although they also occur in 12% of men with normal semen parameters (Cohen, 2001; Borruto et al., 2010; Alkatout et al., 2015; Marte, 2018).

The presence of a varicocele does not always affect spermatogenesis, as it has been reported that only 20% of men with documented varicoceles suffer fertility problems (Perry, 2001; Cohen, 2001; Eisenberg & Lipshultz, 2011; Alsaikhan et al., 2016; Marte, 2018). However, varicocele repair appears to have beneficial effects in men with impaired semen parameters and palpable varicoceles as had been observed in the results in certain numbers of cases, also had been documented by other studies (Eisenberg & Lipshultz, 2011; Vieira, 2013; Chiba & Fujisawa, 2016; Belay et al., 2016).

In this study we agree with other studies in this regards that Invention of laparoscopic varicocelectomy gives a better visualization and more free access that wanted in surgery and the era of varicocelectomy procedure hugely

changed. Accordingly, as presence of dilated dumping contained- blood can be well observed just by simple squeezing of scrotum by assistant, moreover direct laparoscopic visions on right side we found nearly more than 5% of cases have had subclinical varicoceles on the right testis which were ligated with frequent collateral veins which had been handled and these were conditions not possible to be done by OVV (Cohen, 2001; McManus et al., 2004; Kantartzi et al., 2007; Borruto et al., 2010; Alkatout et al., 2015; Belay et al., 2016; Wang et al., 2020).

Conclusions:

Laparoscopic varicocelectomy is a macroscopical and promising procedure that is easy to perform, with wide panoramic accessibility. Have ability to perform uni and bilateral varicocelectomy by same ports and most evident method for presence of varicosity in query cases by direct vision bilaterally and to find any other external pressure factors that participating like hernia sac, big lipoma and adhesions. Also it is the best approach when recurrent varicoceles, obesity are problems; presence of collateral channels which if they missed may cause failure of operation and recurrent VV. Compared to the open technique, LVV has minimal postoperative morbidity, shorter recovery and an earlier return to normal activities. Although there was significant conceiving numbers superiority of the open method. The laparoscopic technique highly advised for varicocele ligation to replace the

conventional open method. But needs longer time follow up and bigger volumes of studies which makes to understand more details.

References

- Alkatout, I., Mettler, L., Maass, N., Noé, G.-K., & Elessawy, M. (2015). Abdominal anatomy in the context of port placement and trocars. *Journal of the Turkish German Gynecological Association, 16*(4), 241–251. <https://doi.org/10.5152/jtgga.2015.0148>
- Alsaikhan, B., Alrabeeah, K., Delouya, G., & Zini, A. (2016). Epidemiology of varicocele. *Asian Journal of Andrology, 18*(2), 179–181. <https://doi.org/10.4103/1008-682X.172640>
- Bebars, G. A., Zaki, A., Dawood, A. R., & El-Gohary, M. A. (2000). Laparoscopic versus Open High Ligation of the Testicular Veins for the Treatment of Varicocele. *JSLs: Journal of the Society of Laparoendoscopic Surgeons, 4*(3), 209–213.
- Belay, R. E., Huang, G. O., Shen, J. K.-C., & Ko, E. Y. K. (2016). Diagnosis of clinical and subclinical varicocele: How has it evolved? *Asian Journal of Andrology, 18*(2), 182–185. <https://doi.org/10.4103/1008-682X.169991>
- Binsaleh, S., & Lo, K. C. (2007). Varicocele: Microsurgical inguinal varicocele is the treatment of choice. *Canadian Urological Association Journal, 1*(3), 277–278.
- Borruto, F. A., Impellizzeri, P., Antonuccio, P., Finocchiaro, A., Scalfari, G., Arena, F., Esposito, C., & Romeo, C. (2010). Laparoscopic vs open varicocelelectomy in children and adolescents: Review of the recent literature and meta-analysis. *Journal of Pediatric Surgery, 45*(12), 2464–2469. <https://doi.org/10.1016/j.jpedsurg.2010.07.007>
- Chan, P. (2011). Management options of varicoceles. *Indian Journal of Urology: IJU: Journal of the Urological Society of India, 27*(1), 65–73. <https://doi.org/10.4103/0970-1591.78431>
- Chiba, K., & Fujisawa, M. (2016). Clinical Outcomes of Varicocele Repair in Infertile Men: A Review. *The World Journal of Men's Health, 34*(2), 101–109. <https://doi.org/10.5534/wjmh.2016.34.2.101>
- Cohen, R. C. (2001). Laparoscopic varicocelelectomy with preservation of the testicular artery in adolescents. *Journal of Pediatric Surgery, 36*(2), 394–396. <https://doi.org/10.1053/jpsu.2001.20725>
- Ding, H., Tian, J., Du, W., Zhang, L., Wang, H., & Wang, Z. (2012). Open non-microsurgical, laparoscopic or open microsurgical varicocelelectomy for male infertility: A meta-analysis of randomized controlled trials. *BJU International, 110*(10), 1536–1542. <https://doi.org/10.1111/j.1464-410X.2012.11093.x>

- Eisenberg, M. L., & Lipshultz, L. I. (2011). Varicocele-induced infertility: Newer insights into its pathophysiology. *Indian Journal of Urology: IJU: Journal of the Urological Society of India*, 27(1), 58–64.
<https://doi.org/10.4103/0970-1591.78428>
- Flannigan, R., Bach, P. V., & Goldstein, M. (2017). Microsurgical varicocele repair induces spermatogenesis among men with non obstructive azoospermia: A 25 year experience. *Fertility and Sterility*, 108(3), e310–e311.
<https://doi.org/10.1016/j.fertnstert.2017.07.918>
- Kantartzi, P. D., Goulis, C. D., Goulis, G. D., & Papadimas, I. (2007). Male infertility and varicocele: Myths and reality. *Hippokratia*, 11(3), 99–104.
- Marte, A. (2018). The history of varicocele: From antiquity to the modern ERA. *International Brazilian Journal of Urology: Official Journal of the Brazilian Society of Urology*, 44(3), 563–576.
<https://doi.org/10.1590/S1677-5538.IBJU.2017.0386>
- McManus, M. C., Barqawi, A., Meacham, R. B., Furness, P. D., & Koyle, M. A. (2004). Laparoscopic varicocele ligation: Are there advantages compared with the microscopic subinguinal approach? *Urology*, 64(2), 357–360; discussion 360–361.
<https://doi.org/10.1016/j.urology.2004.03.055>
- Perry, C. P. (2001). Current Concepts of Pelvic Congestion and Chronic Pelvic Pain. *JSLS: Journal of the Society of Laparoendoscopic Surgeons*, 5(2), 105–110.
- Vieira, M. (2013). New World Health Organization reference values for semen analysis: Where do we stand? *Einstein*, 11(2), 263–264.
<https://doi.org/10.1590/S1679-45082013000200023>
- Wang, Q., Liu, Y., & Wang, L. (2020). Open, Laparoscopic, and Microsurgical Varicolectomy for Male Infertility: A Systematic Review and Meta-analysis. *Indian Journal of Surgery*, 82(4), 478–485.
<https://doi.org/10.1007/s12262-019-02011-1>