

## Occlusal plane orientation with an extracranial posterior point of reference

Munther N KAZANJI \*

### ABSTRACT

This study was carried out to compare the location of occlusal plane, which exists in the natural dentition with the prosthetic occlusal plane when oriented according to Camper's line.

Lateral cephalometric radiographs were obtained from (106) dentate subjects using a standard radiological technique.

The results showed a variation between the orientation of the two planes. The plane extending from inferior border of ala of the nose to the inferior border of external auditory meatus was found to be reliable for the determination of occlusal plane of the artificial teeth.

**Key Words:** Occlusal plane, Camper's line, ala-tragus line.

### الخلاصة

أجريت هذه الدراسة لمقارنة موقع المستوى الإطباقى الموجود في الأسنان الطبيعية مع المستوى الإطباقى الصناعى والموجه طبقاً لخط كامبر .  
تم أخذ صور شعاعية جانبية لـ (١٠٦) أشخاص لديهم أسنان طبيعية كاملة باستخدام التقنية المثلى .  
أظهرت النتائج وجود اختلاف بين توجه المستويين . وجد أن المستوى الممتد من الحافة السفلى لأرنبة الأنف إلى الحافة السفلى للفتحة الأذنية العظمية الخارجية يمكن الاعتماد عليه في تحديد المستوى الإطباقى للأسنان الصناعية .

---

\*Munther Najeeb KAZANJI; BDS, MSc: Lecturer. Department of Prosthetic Dentistry, College of Dentistry, University of Mosul, Mosul, IRAQ.

## INTRODUCTION

Correct determination of the occlusal plane is an important step in complete denture construction for restoring the natural esthetics and for developing an occlusion that is compatible with functional movement of the mandible.

The occlusal plane is defined as the common plane established by the incisal and occlusal surfaces of the teeth<sup>(1)</sup>.

The occlusal plane in natural dentition has been reported to be nearly parallel to Camper's plane (ala-tragus plane) by several investigators<sup>(2-6)</sup>. The use of ala-tragus line to orient the occlusal plane has been controversial. This controversy is primarily due to disagreement on the exact point of reference for this line. Spratley<sup>(7)</sup> described it as running from center of ala of the nose to the center of tragus of ear. Baske *et al.*<sup>(8)</sup>, Grant and Johnson<sup>(9)</sup>, Neill and Naim<sup>(10)</sup> described the line as extending to the point at the center of tragus of ear.

Boucher<sup>(11)</sup> defined Camper's line as an imaginary line that runs from the inferior border of the ala of the nose to the superior border of the tragus of the ear.

Karkazis *et al.*<sup>(12)</sup> examined tracing of a cephalogram and showed that the line extending from the lower margin of ala of the nose to the inferior border of external auditory meatus was the closest to the natural occlusal plane.

A cephalometric study<sup>(12, 13)</sup> showed that the reliability of Camper's line is questionable.

Macle<sup>(14)</sup> stated that it is not possible to determine the level of occlusal plane posteriorly till the construction of trial dentures is well established.

Other investigator, Celebic<sup>(15)</sup>, used retromolar pad as a posterior point of reference.

The purpose of this study was to determine the reliability of extracranial posterior point (external auditory meatus) as a guide for occlusal plane orientation in edentulous patients.

## MATERIALS AND METHODS

A sample of (106) dental students was selected to be included in the study. They had to have (28-32) teeth in an acceptable oral form, an Angle class I relationship and no history of orthodontic treatment.

To identify the anterior point of Camper's line, a small radiopaque lead pellet (1) mm in diameter was attached by adhesive tape to the lower margin of ala of the nose, and another one was fixed by red sticky wax to the mesiopalatal cusp of the maxillary first molar.

Lateral cephalometric radiographs were obtained using standard radiographic technique, with the mandible in a rest position. Tracing was made on acetate paper from all the radiographs (figure 1).

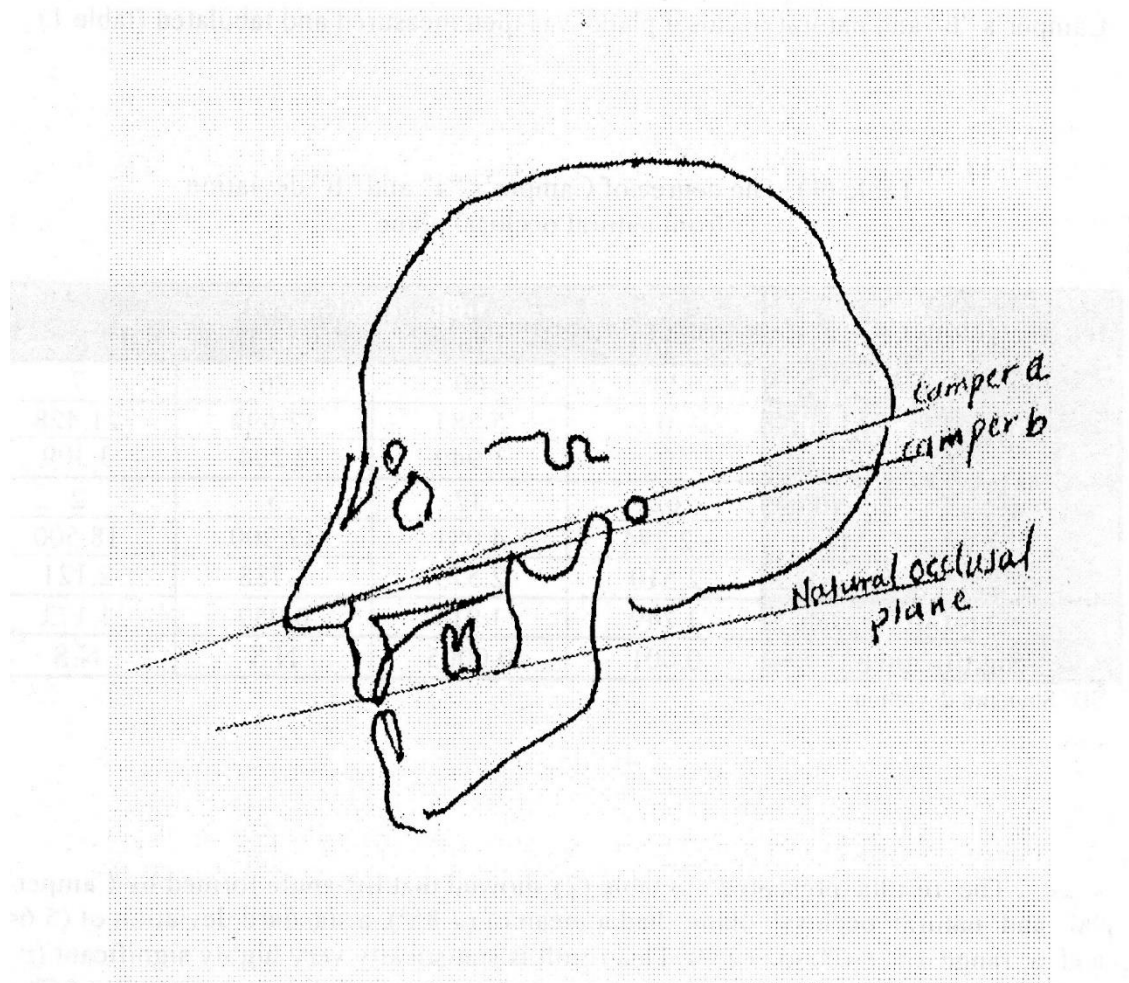


Figure (1): Tracing of cephalogram showing reference points used

The three planes were: Camper's "a" (the line extended from the lower margin of ala of the nose to the superior border of the external auditory meatus), Camper's "b" (the line extended from the lower margin of ala of the nose to the inferior border of the external auditory meatus) and the natural occlusal plane, which is the plane extended from the incisal edge of maxillary central incisor to the mesiopalatal cusp of maxillary first molar.

## RESULTS

The deviation, whether it is positive or negative angle, between Camper's "a", Camper's "b" and natural occlusal plane was then measured and tabulated (table 1).

Table (1): The degree of Camper's "a" and "b" deviation from natural occlusal plane

Camper's		Angles (in degree)			
		-7 to 0	1 to 8	9 to 16	17 to 25
"a"	No.	13	60	26	7
	Mean	0	5.883	12.692	21.428
	± SD	0	1.940	2.204	3.309
"b"	No.	62	37	5	2
	Mean	-2.274	4.081	12.200	18.500
	± SD	2.510	2.575	1.788	2.121
t-test		3.249	3.914	0.959	1.173
Significance		0.001	0.0005	N.S	N.S

SD: Standard deviation.

The results presented in table (2) showed that the angle formed by Camper's "a" and natural occlusal plane had a mean of (7.85°), a standard deviation of (5.64) and a range of (-7°) to (+25°). This result is statistically very highly significant ( $p < 0.0005$ ), indicating that there is an average of postero-inferior deviation of (7.85°) of the natural occlusal plane.

The angle formed by Camper's "b" and natural occlusal plane had a mean of (1.01°), a standard deviation of (5.25) and a range of (-7°) to (+25°).

Table (2): Comparison between Camper's "a" and "b" and natural occlusal plane

Angle	No.	Mean	± SD	t-test	Significance
Camper's "a" and Natural Occlusal Plane	106	7.858	5.642	9.136	0.0005
Camper's "b" and Natural Occlusal Plane	106	1.018	5.251		

SD: Standard deviation.

## DISCUSSION

In this study, a fixed posterior point of reference (external auditory meatus) was compared with natural occlusal plane. Camper's "b", which is the plane extended from the lower margin of ala of the nose to the inferior margin of external auditory meatus, found to have the closest relationship to the natural occlusal plane; and can be depended during the construction of complete denture. This finding agrees with other studies<sup>(3, 12)</sup>, which found that using this plane is more reliable and convenient in the arrangement of artificial teeth. On the other hand, this result disagrees with another study<sup>(6)</sup> that used ala-tragus line in creating occlusal plane for complete denture construction.

When ala-tragus line is used as the reference to set the occlusal plane, it is possible for the posterior teeth of the artificial occlusion to rise above the natural occlusal plane level. The lower denture comes posteriorly too high for patient comfort and the resultant inclined plane affects the stability of the lower denture.

It was concluded that extending the artificial occlusal plane from lower margin of ala of the nose to the inferior border of external auditory meatus presented the closest relationship to the natural occlusal plane which, from a clinical standpoint, can be used safely.

## REFERENCES

1. Glossary of Prosthodontic Terms. *J Prosthet Dent*. 1994; 71: 44-117.
2. Zarb GA, Bolender CL, Carlsson GE. Boucher's Prosthetic Treatment for Edentulous Patients. 11<sup>th</sup> Edn. The CV Mosby Co. 1991.
3. Abraham SR, Carey PD. The use of ala-tragus line for occlusal plane determination in complete denture. *J Dent*. 1979; 7(4): 339-341.
4. D'Sousa NL, Bhargara K. A cephalometric study comparing the occlusal plane in dentulous and edentulous subjects in relation to maxillo-mandibular space. *J Prosthet Dent*. 1996; 75: 177-182.
5. Winkler S. Essentials of Complete Denture Prosthodontics. Philadelphia. WB Saunders Co. 1979; Pp: 193-262.
6. Van Niekerk FW, Miller VJ, Bibby RE. The ala-tragus line in complete denture prosthodontics. *J Prosthet Dent*. 1985; 53(1): 67-69.
7. Spratley MH. A simplified technique for determining the occlusal plane in full denture construction. *J Oral, Rehabil*. 1980; 7: 31.
8. Bhasker RM, Davenport JC, Tomlin HR. Prosthetic Treatment of the Edentulous Patient. 1<sup>st</sup> Edn. London. MacMillan. 1976; Pp: 112.
9. Grant AA, Johnson W. An introduction to Removable Denture Prosthodontics. Edinburgh. Churchill Livingstone. 1983; Pp: 180.
10. Neill DJ, Naim RI. Complete Denture Prosthetics. Bristol. John Wright & Sons. 1975; Pp: 72-73.
11. Boucher CO. Current Clinical Dental Terminology. 3<sup>rd</sup> Edn. St Louis. CV Mosby Co. 1982; Pp: 175.

12. Karkazis HC, Polyzois GL, Zissis AJ. Relationship between ala-tragus line and natural occlusal plane. Implications in denture prosthodontics. *Quintessence Int.* 1986; 17: 253-255.
13. Monteith BD. Evaluation of a cephalometric method of occlusal plane orientation for complete denture. *J Prosthet Dent.* 1986; 55: 64-69.
14. Mack PJ. A discussion of some factors of relevance in the occlusion of complete dentures. *Aust Dent J.* 1989; 34(2): 122-129.
15. Celebic A, Valentic PM, Kraljevic K, Brkic H. A study of the occlusal plane orientation by intra-oral method (retromolar pad). *J Oral Rehabil.* 1995; 22(3): 233-236.