

The course and the branches of the greater palatine nerve on the inferior surface of the hard palate

Ayad A Al-Saraj¹
BVM&S, MSc (Assist Prof)

Abid Al-Jabbar Y Al-Hubity²
MBChB, PhD (Assist Prof)

¹Department of Basic Sciences
College of Dentistry, University of Mosul

²Department of Anatomy
College of Medicine, University of Mosul

ABSTRACT

The both sides of twenty seven adult human cadavers were dissected to know the course and branches of the greater palatine nerve. The results showed that the most common course (81.5%) of the nerve when it was emerged from the greater palatine nerve between the 2nd and 3rd molar teeth about 1 cm superior to the margin of the palatine gingiva; and in 75.9% cases the nerve was seen divided into large medial and small lateral branches. The bony palate examination of both sides of twenty three adult dried human skulls showed two grooves on the inferior surface of the palate, and these grooves were converted into unilateral (26.1%) and bilateral (13.2%) bony canal. The present study also noticed a unilateral spine between the grooves in 34.8% of cases and bilateral spine in 17.4% cases of the examined skulls. It is concluded that the dentist has to take these anatomical notes with consider to obtain a successful injection for greater palatine nerve block.

Key Words: Greater palatine nerve, hard palate.

أجريت دراسة تشريحية على جثث سبعة وعشرون شخصاً بالغاً وذلك بتشريح كلا الجهتين للحنك الصلب لمعرفة مسار وتفرعات العصب الحنكي الكبير. وقد وُجِدَ أن أعلى نسبة مسار الحنكي الكبير (81.5%) كانت عند خروج العصب من الثقب الحنكي الكبير بين الرحي الثاني والرحي الثالث وعلى بُعد 1 سم أعلى حافة اللثة الحنكية. كما لوحظ، وبنسبة 75.9% من الحالات، أن العصب ينقسم إلى فرع أنسي كبير وفرع وحشي صغير. كما وأن نتائج فحص كلا الجهتين للحنك الصلب لثلاثة وعشرون جمجمة أظهرت وجود أخدودين في السطح السفلي للحنك وفي بعض الحالات تحول هذان الأخدودان إلى قناة عظمية وبنسبة 26.1% في جهة واحدة و 13.2% في كلا الجهتين. وشوهد أيضاً وجود شوكة عظمية بين الأخدودين وبنسبة 34.8% في جهة واحدة و 17.4% في كلا الجهتين. لذلك فإن هذه الدراسة تتصح طبيب الأسنان بأخذ هذه الملاحظات التشريحية في عين الاعتبار لكي يحصل على أفضل نتيجة عند تخديره للعصب الحنكي الكبير.

الخلاصة

INTRODUCTION

The greater palatine nerve arises from the pterygopalatine ganglion and descends inferiorly through the greater palatine canal to appear on the oral surface of the palate when emerging from the greater palatine foramen medial to the 2nd molar

tooth.⁽¹⁾ The nerve then passes anteriorly through the mucoperiosteum to supply the lingual gingiva and palatal mucosa from the maxillary canines posteriorly.⁽²⁾ The greater palatine nerve and its branches is used for anaesthetic injection used by dentist especially for surgical procedures

involving the palatal mucosa, lingual gingiva posterior to the maxillary canines, and the underlying area of the palate.^(3, 4) Therefore, knowledge of the most common course and the main branches of the greater palatine nerve is important to dentist. The bone of the palate is formed by the palatine process of the maxilla and the horizontal plates of the palatine bone.⁽⁵⁾ The inferior surface of this bony plate adjacent to the alveolar margin is marked by two grooves for the greater palatine vessels and nerves,^(2, 5, 6) and between the grooves there is a palatine spine.⁽⁷⁾

In view of the clinical importance of the greater palatine nerve to the dentist, this study was conducted to know the exact anatomical course of this nerve and the variations found on the oral surface of the palate.

MATERIALS AND METHODS

Fifty four halves of hard palates belonged to twenty seven adult human cadavers were used in the present study. The materials used were obtained from a collection of cadavers (after being dissected by medical and dental students) belonged to the Department of Anatomy at Mosul Medical College during the period 1996–2002.

The greater palatine nerve on each side of the hard palate was carefully dissected after delicate removing of the mucoperiosteum to see the course of the nerve.

Forty six halves of bony palates belonged to twenty three adult human

dried skulls were also carefully examined to describe the grooves and spines for the greater palatine nerves.

RESULTS

Out of fifty four halves of hard palate (from 27 cadavers) used; in 44 cases 81.5% the greater palatine nerve was seen to emerge on the palate between the 2nd and 3rd molar teeth about 1 cm superior to the margin of the palatal gingiva, while in 10 cases (18.5%) the nerve was seen just medial to the 2nd molar teeth. In 41 cases (75.9%) the greater palatine nerve divides into a large medial and a small lateral branches, usually the medial one communicates with the branches of the nasopalatine nerve. In 13 cases (24.1%) the greater palatine nerve was seen as a single trunk which divided into small terminal branches (Figure 1).

For all the twenty three bony palates (dried skull) examined there was a common pattern characterized by the presence of two grooves with variable depth ranging from deep to shallow grooves (Figure 2). In 6 cases (26.1%) the grooves were converted into unilateral bony canal, while in 3 cases (13.2%) there was bilateral bony canal (Figure 3). In 8 cases (34.8%) there was a unilateral spine (Figure 2), while in 4 cases (17.4%) there was bilateral spines. In 2 cases (8.5%) there was a unilateral spine with unilateral bony canal.

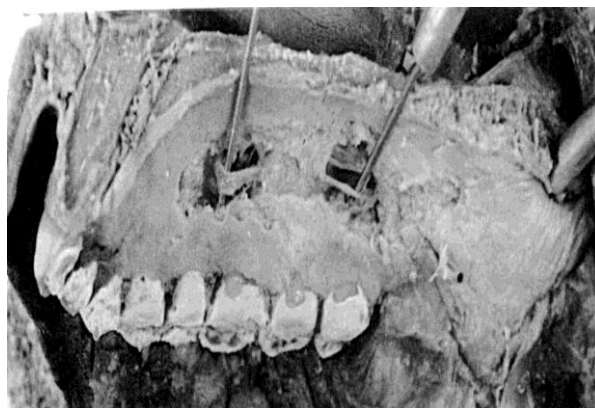
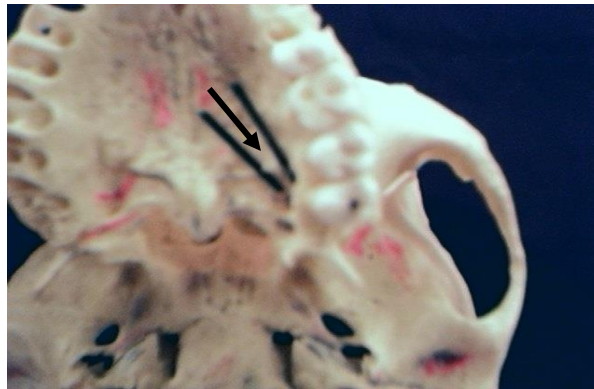


Figure (1): Dissection of the inferior surface of the hard palate showing the course of the

greater palatine nerve (probe) as a single trunk



Al-Rafidain Dent J
Vol. 3, No. 1, 2003

Figure (2): The inferior surface of the hard palate showing bilateral grooves (probes) separated by spine (arrow)

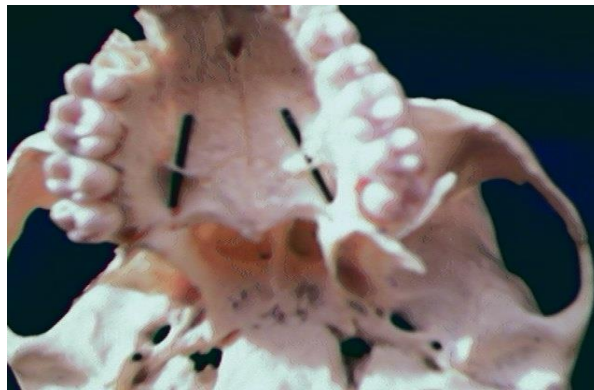


Figure (3): Inferior surface of the hard palate showing bilateral bony canal indicated by probes

DISCUSSION

The present work observed the presence of a spine between the two grooves of the branches of the greater palatine nerve. This finding is in agreement with other previous report.⁽⁷⁾ Most of the standard anatomical and maxillofacial surgical texts mentioned a little description about the course of the greater palatine nerve and the variations found on the oral surface of the hard palate.⁽⁸⁻¹¹⁾ The reason for this is probably because this area received little attention in anaesthetic practice. The greater palatine nerve block injection is used usually by dentist to provide satisfactory anaesthesia for oper-

ations involving the palate. This block is not always successful because of some possible factors which impede effective anaesthetics due to inadequate techniques.^(3, 4) In this study we have noticed a fibrous tissue forming osseofibrous canal which later ossified and converted to canals. This canal may act as anatomical barrier to diffusion of anaesthesia during the infiltration of the greater palatine nerve for local anaesthesia.

Our conclusion based on two facts; firstly that the dental surgery nowadays is more progressing compared to the last 10 years, and this needs from the anatomist to

focus on the structures and areas related to this type of surgery. Secondly, there is a bony canal which may face the greater palatine nerve and this canal acts as an anatomical barrier which creates some difficulties during the process of infiltrating the nerve for local anaesthesia. Therefore, this study suggests for the

dentist on trying to block the greater palatine nerve to deposit the anaesthetic solution between the 2nd and 3rd molar teeth at the mouth of the greater palatine foramen. This technique avoids any anatomical barrier, which might face the course of the greater palatine nerve.

REFERENCES

1. Liebgott B. The Anatomical Basis of Dentistry. WB Saunders Co. Philadelphia. 1982; p: 238.
2. Dixon A. Anatomy for Students of Dentistry. Churchill Livingstone. London. 1986; p: 132.
3. Howe G, Whitehead F. Local Anaesthesia in Dentistry. 2nd ed. John Wright & Sons, Ltd. Bristol. 1981; p: 71.
4. Malamed S. Handbook of Local Anaesthesia. 4th ed. CV Mosby Co. St Louis. 1997; p: 179.
5. Atkinson M, White F. Principle of Anatomy and Oral Anatomy for Dental Students. Churchill Livingstone. Edinburgh. 1992; p: 336.
6. Williams PL, Warwick R. Gray's Anatomy. 38th ed. Churchill Livingstone. Edinburgh, London, Melbourne, New York. 1995.
7. Jeyaseelan N, Gupta M. Canals for the greater palatine nerve and vessels in the hard palate. *J Anat.* 1988; 156: 231.
8. Romanes GJ. Cunningham's Textbook of Anatomy. 12th ed. Oxford University Press. Oxford, New York. 1981.
9. Last RJ. Anatomy: Regional and Applied. 8th ed. Churchill Livingstone. Edinburgh. 1995.
10. Snell RS. Clinical Anatomy for Medical Students. 5th ed. Little Brown & Co. Boston, New York, London. 1995.
11. Kruger GO. Textbook of Oral and Maxillofacial Surgery. 6th ed. Williams and Wilkins Co. Baltimore. 1984.

Received: 30/11/2002

Accepted for Publication: 27/1/2003