

Role of Multi-Disciplinary Team Clinic in the Management of Orthognathic Patients A Seven Years Review of Orthognathic Surgery

Dr. Bashar A. Tawfeeq
BDS. FICMS.

Department Of Oral And Maxillofacial Surgery
Al-Salam Teaching Hospital, Nineveh Health Directorate, , Ministry of Health. Iraq

Dr. Rawaa Y. Al-Rawee
BDS. MSc, OS.PhD,
MOMS MFDS

Department of Oral and Maxillofacial Surgery
Al-Salam Teaching Hospital, Nineveh Health Directorate, Ministry of Health. Iraq

Dr. Younis M. Saeed
BDS, MSc, PhD (Iec.)

Department of Othodontic, Pedodontic, Prevntion
College of Dentistry, University of Mosul

Dr. Dina A. Al-Khashab
BDS, MS

Dent. Health Specialized Center, Depart. of Orthodontic
Nineveh Health Directorate, Ministry of Health

Dr. Mahmood Kh. Ahmed
BDS. SHO.

Department Of Oral And Maxillofacial Surgery
Health Directorate, Ministry of Health. Iraq

الخلاصة

الاهداف: تهدف الدراسة الى تقييم الحاجة والفوائد لعيادة الفريق متعدد التخصصات (MDT) في علاج مرضى جراحة عظام الوجه التقويمية. **المواد وطرائق العمل:** تم فحص ما مجموعه 272 مريضاً في مركزين في الموصل. قسمت العينة إلى مجموعتين ، تم تشخيص المجموعة الأولى من فبراير 2004 حتى مارس 2009 بدون عيادة MDT ، بينما تم تشخيص المجموعة الثانية من أبريل 2009 حتى يوليو 2011 في عيادة MDT ، وتم تقييمها لرغبتهم و لتصحيح المشاكل الوظيفية والجمالية ، وهي معايير تم تطبيقها على كل منهم لإدارة الحاجة الحقيقية للعمل الجراحي. **النتائج:** من مجموع المرضى الباحثين عن العلاج، كانت المجموعة الأولى 116 مريضاً، و 54 مريضاً (46.5%)، بينما كانت المجموعة الثانية 156 مريضاً، 33 مريضاً (21.1%). **الاستنتاجات:** الحاجة إلى التصحيح الجراحي لتشوهات الوجه والفكين هي موضوع ثلاثي الجوانب: شكوى المريض الحقيقية، قرار فريق العمل وكذلك تعليم الطاقم الطبي. العيادة التخصصية للجراحة التقويمية لها دور يؤثر ايجابيا في تطوير القرار التشخيصي للحالات المرضية وبالتالي النتائج الفعالة للعمليات الجراحية.

ABSTRACT

Aims: to evaluate the need for and benefits of Multi-Disciplinary Team (MDT) clinic in treating orthognathic patients. **Materials and Methods:** a total number of 272 patients were examined in 2 centers in Mosul. The sample divided into 2 groups, first group diagnosed from Feb 2004 till March 2009 without MDT clinic, while second group diagnosed from April 2009 till July 2011 in MDT clinic, and evaluated for their needs and wants to correct functional and esthetic problems, a criteria were applied to all of them to manage the real need for the surgical work. **Results:** from total patients seeking treatment, first group were 116 patients, 54 patients (46.5%) operated, while the second group were 156 patients, 33 patients (21.1%) operated. **Conclusions:** need for surgical correction of facial and gnathic deformities is a three handed subject: patient's real complaint, team work decision and medical staff education.

Key words: Benefit of surgery, MDT clinic, Orthognathic surgery, Patient satisfaction.

Tawfeeq BA., Al-Rawee RY., Saeed YM., Al-Khashab DA., Ahmed M Kh. Role of Multi-Disciplinary Team Clinic in the Management of Orthognathic Patients A Seven Years Review of Orthognathic Surgery. Al-Rafidain Dent J. 2020;20(1):143-153.

Received: 9/4 /2014

Sent to Referees: 10/4 /2014

Accepted for Publication: 20/5/2014

INTRODUCTION

Orthognathic surgery refers to a group of corrective bone operations that involve movement of the jawbones completely or in parts.⁽¹⁾ Orthognathic surgery is indicated when there are severe dento-facial deformities that cannot be managed by orthodontic treatment alone, especially in adulthood, when the natural growth forces have ceased.⁽²⁾ Dentofacial deformities are described as deformities that affect primarily the jaws and dentition. They may be limited to one jaw or may extend to multiple craniofacial structures.⁽³⁾ The classification and analysis of facial skeletal deformities is complex and involves discrepancies in all planes of space. The measurement of these discrepancies must take into account dental compensations for the underlying skeletal deformity.⁽⁴⁾ The history of orthognathic surgery dates back to the 19th century, when Le Fort described the classic lines of maxillary fracture. Wassmund, in 1927, was the first surgeon to use an osteotomy line on Le Fort I level for the correction of malocclusion. Le Fort I osteotomy was popularized by Obwegeser in the mid-20th century as a standard procedure in maxillofacial surgery to correct dentofacial deformities.^(5,6) The modern history of orthognathic surgery started in the 1970s, as it gradually became a routine choice, with benefits such as improvement of mastication and reduction of facial pain and more stable results even in severe discrepancies^(7,8) The prevalence of dento-facial deformities has been estimated as

20% of the population worldwide.⁽⁹⁾ Data gathered from the United States of America points to a prevalence of approximately 20% of the US population, of which 2% warrant surgery.⁽¹⁰⁾ In Scandinavia, it has been estimated that 10% of young people are in need of orthodontic treatment.⁽¹¹⁾ In the Netherlands, it has been found that 39% of the population needs orthodontic treatment.⁽¹²⁾ Indications for orthognathic surgery, other than the purely anatomical ones, include the psychosocial and biophysiologic factors which greatly affect the need and demand for treatment. Desire for aesthetic improvement has been expressed as the major reason for seeking orthognathic surgery in several studies.^(13,14) Maxillary and/or mandibular facial skeletal deformities associated with masticatory malocclusion may include: Anteroposterior discrepancies, Vertical discrepancies, Transverse discrepancies, facial Asymmetries, In addition, orthognathic surgery may be indicated in cases where there are specific documented signs of dysfunction. These may include conditions involving airway dysfunction such as sleep apnea, temporomandibular joint disorders, psychosocial disorders and \ or speech impairments.⁽⁴⁾ The basic pre-surgical orthodontic goals are include align and position teeth over basal bone, avoid excessive intrusion or extrusion of teeth and avoid unstable expansion of the dental arches, decompensate teeth. Avoid class II and class III mechanics (unless required for dental decompensation correction in the arches) as well as perform stable and predictable orthodontics.⁽¹⁵⁾ Considering the

psychological aspects, neuroticism may have a negative effect on the early postoperative phase but not on the long-term outcome.⁽¹⁶⁾ Although patients with dysmorphophobia (feeling unattractive despite having almost normal appearance) may benefit from surgery, the initial treatment should be psychiatric rather than surgical.⁽¹³⁾ Pogrel and Scott⁽¹⁷⁾ concluded that most orthognathic surgery patients are psychologically normal, and routine preoperative psychological evaluation is not indicated. A cornerstone of a successful outcome is a thorough evaluation of the patient's expectations and careful preoperative information about the surgical process. Human biophysiology phenomena are similar throughout the world, but psychosocial responses may differ considerably between different cultures.⁽¹⁸⁾ Planning for the surgery usually involves input from a multidisciplinary team. Involved professionals are Oral and Maxillofacial surgeons, Orthodontists, and sometimes a Speech and language therapist. As the surgery usually results in a noticeable change in the patient's face a psychological assessment is occasionally required to assess patient's need for surgery and its predicted effect on the patient.^(19,20) The main goals of orthognathic surgery are to achieve a correct bite, an aesthetic face and an enlarged airway. While correcting the bite is important, if the face is not considered the resulting bony changes might lead to an unaesthetic result.⁽²¹⁾ Orthognathic surgery is also available as a very successful treatment (90-100%) for obstructive sleep apnea.⁽²²⁾ Great care needs to

be taken during the planning phase to maximize airway patency. Like any other surgery, there can be some complications like bleeding, swelling, infection, nausea and vomiting.⁽²³⁾ There could also be some numbness in the face due to nerve damage. The numbness may be either temporary, or, more rarely, permanent.⁽²⁴⁾ In general, complications of this surgery occur, but not frequently.⁽²⁵⁾

Aim of the study: to evaluate the need for and benefits of Multi-Disciplinary Team (MDT) clinic in treating orthognathic patients.

MATERIALS AND METHODS

Patients:

A total number of 272 patients were examined in two centers in Mosul; the maxillofacial department in Al-Salam Teaching hospital, and the MDT clinic in the training center in the Dental and Oral Management Iraqi Association. The collected sample divided into two groups, first group diagnosed from Feb 2004 till March 2009 without MDT clinic, while second group diagnosed from April 2009 till July 2011 in MDT clinic, and evaluated for their needs and willingness to correct functional and esthetic problems, a criteria were applied to all of them to manage the real need for the surgical work.

A short questionnaire applied to the patients including a brief history with clinical findings and final diagnosis with proper treatment plan, some

difficult advanced cases were subjected to consultation of Dr. Riyadh Al-Kamali, a famous Iraqi consultant in Erbil, and Mr. Kieth Postlithwaite, an orthognathic surgeon in Newcastle General Hospital in Newcastle upon Tyne, England.

The first group (Non MDT group) diagnosed and operated without the presence of MDT clinic, and the orthodontic opinion was achieved personally through a request consultation to different orthodontic and prosthodontic specialists.

The second group (MDT group) subjected to the MDT Clinic which contain a different specialty in Dentistry all of them share in the management of orthognathic conditions, including: Maxillofacial surgeon, Orthodontist, Prosthodontist and Senior House Officer, the same questionnaire applied to the patients seeking for MDT clinic, The clinic confined to just one day monthly from April 2009 till now.

General information, history which include mainly patient's chief complaint (esthetic or function), and then register the findings of clinical examination, investigations, treatment plan, then we ask for patient's desire (willingness), and deals a conversation about the treatment plan with the patient, with the presence of orthodontist and surgeon explaining the exact and real patient's need. Finally, after discussion, we can answer the exact question, Are the treatment plan that the MDT decide, coincide with the patient's willing or patient's real need? Then, after surgery, pay

attention for the patient's acceptance of the postoperative results, and comparison of total outcome of those patients subjected to MDT clinic and those diagnosed without MDT clinic.

Hospital Admission and Dismissal:

All patients admitted at morning of operation and for major typed operation dismissed out of hospital in the same operative day at evening, for supra-major operations, dismissed at morning of next two days.

Patients' follow up:

Patients followed post operatively for more than 5 months regularly as follow, weekly visit in the first month, 2 visits in the second month and once monthly for next 3 months.

RESULTS

From total patients 272 seeking treatment (7.5 years duration), 87 patients (31.9%) were operated surgically to correct their gnathic and facial problems, 12 patients (4.4%) refuse surgery, the rest of the diagnosed patients return back to their orthodontic specialists for further orthodontic correction.

First group, non-MDT, (within 5 years duration) were 116 patients, 54 patients (46.5%) operated, while the second group, with MDT, (within 2.5 years duration) were 156 patients, 33 patients (21.1%) operated. Table (1), Figures (1-4)

Table (1): number of patients examined and operated in the two groups

	Non MDT Group		MDT Group		Total Number	
	No.	%	No.	%	No.	%
Total number of diagnosed patients	116	42.64	156	57.35	272	100
Patients indicated for surgical correction	59	59.59	40	40.40	99	100
Number of Operated patients	54	62.06	33	37.93	87	100
Patients corrected by orthodontics alone	54	32.92	110	67.07	164	100
Patients have no real complaint clinically and radiographically	3	33.33	6	66.66	9	100

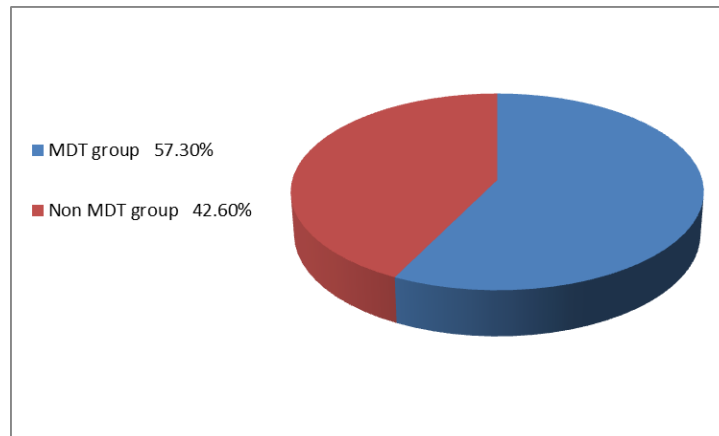


Figure (1): Diagnosed patients in both groups

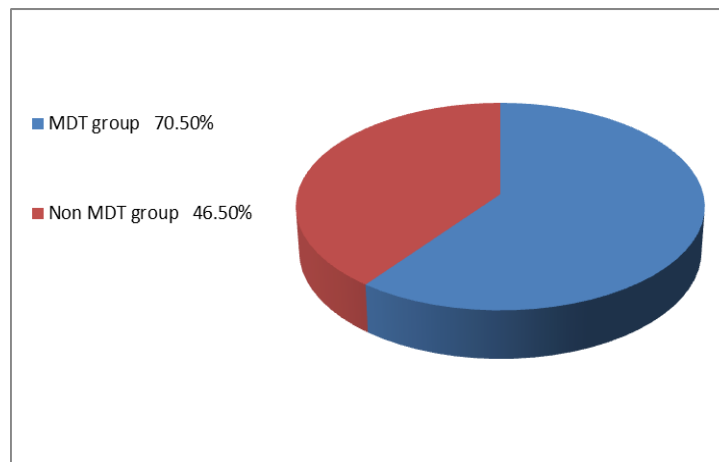


Figure (2): Patients treated by orthodontic alone in both groups

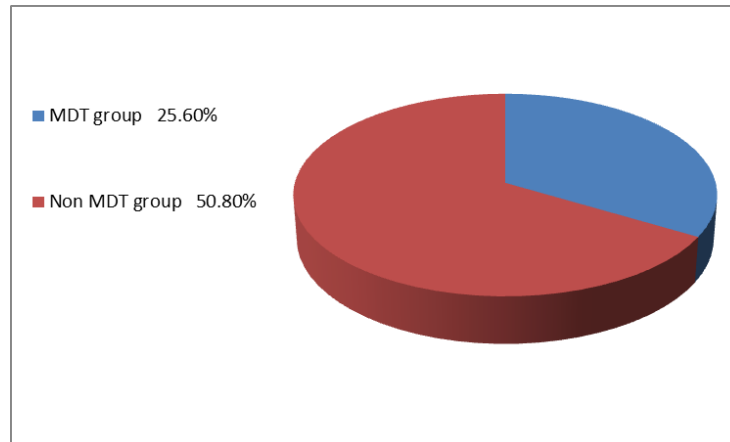


Figure (3): Patients indicated for surgery in both groups

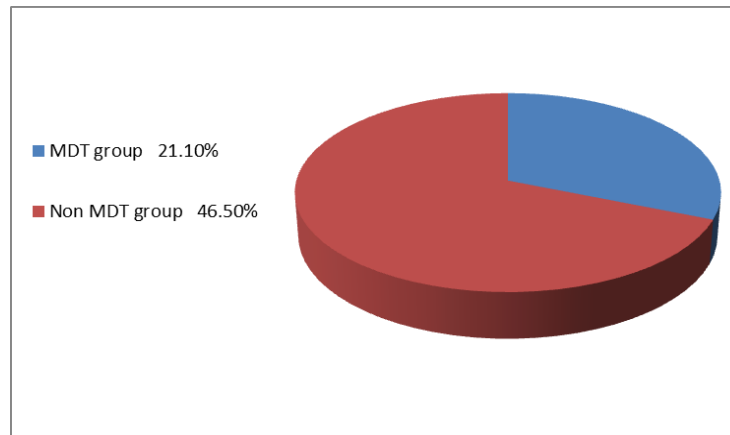


Figure (4): Operated patients in both groups

Regarding the reason for seeking treatment, patients had a main chief complaint related to esthetic cause range from mild gnathic or facial defect to severe cosmetic disfigurement, of those, 9 dysmorphophobic patients (3 from first group, 6 from second group) have no real complaint (clinical, functional and/or radiographical) that may undergo a surgical operation to correct, and accordingly, sustain their management by the final decision of the medical team. On

the contrary the remaining patients suffer from the following problems: for masticatory dysfunction (2 patients, MDT group), growth disorders (1 patient with sleep apnea, Non-MDT group), social problems (1 patient, MDT group) and TMJ pain (2 patients, MDT group).

One patient out of total 272, was unsatisfied by the postoperative result, in spite of noticed improvement in lip contour and dental arch alignment Figure (5), and about 8 patients, 2 from the non-

MDT group and 6 from the MDT group, return back for more additional cosmetic

operation, as they are highly satisfied with the results.

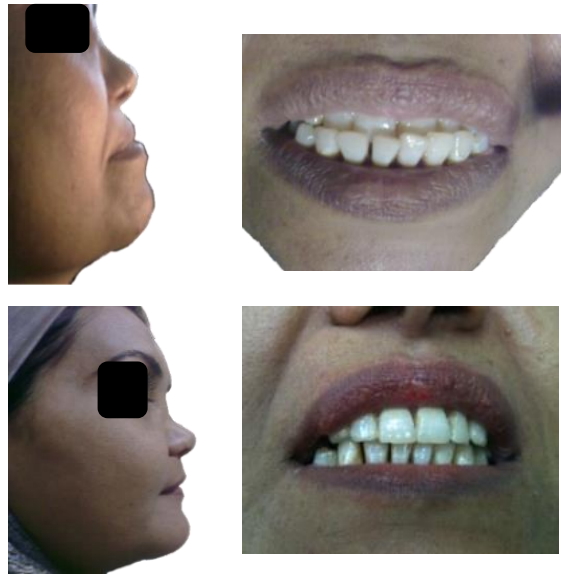

Figure (5): patient with history of impacted untreated LeFort III fracture, seeking for surgical correction; treated with bimaxillary anterior segmental osteotomy.

One relapse was noticed in the non-MDT group in patient with a history of repaired cleft lip and palate in that he underwent a bimaxillary osteotomy, LeFort I operation was relapsed due to powerful backward muscular pull while the lower skeletal osteotomy gave

him an accepted result and outcome satisfaction. Two patients from MDT group continued their esthetic correction post-surgically by a communication with the Implantology MDT clinic for advanced implantology, Figure (6).

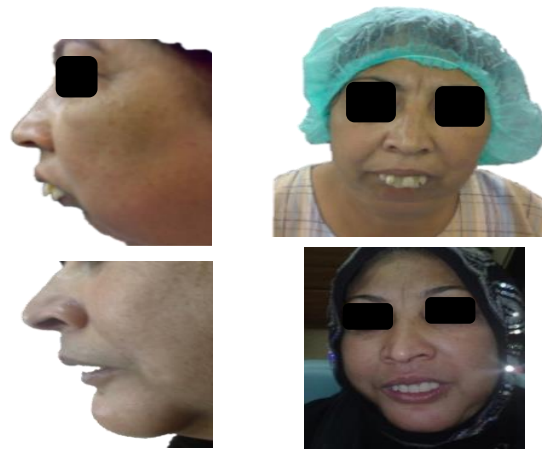

Figure (6): patient with history of obstructive sleep apnea, with severe mandibular micrognathia; corrected with bilateral inverted L osteotomy osteotomy and iliac blocks bone graft and onlay acrylic genioplasty with dental esthetic implant in communication with implant MDT.

Of total operations, supra-major operation applied for 52 patients (19.1%), the remaining 35 patients (12.8%) underwent a major operation.

DISCUSSION

Patient's trust with the decision of the MD Team is more than that decision produced by one or two separated specialists, on the other hand the quality of the final diagnosis and scheduled treatment plan created for each individual case are more accurate with the presence of MD Team and match the treatment plan arranged by two famous consultants that we consult for advanced cases, in addition, in total, the outcome results met the patients' satisfaction (the results were excellent according to patient's willing) ⁽²⁶⁾.

In comparison with non-MDT group, in the MDT clinic group, less patients were operated in relation to the total diagnosed patients (21.1% in MDT group, 46.5% in non MDT group), which is related to careful and accurate selection of patients for corrective operation.

In the same field, the total number of patients attend for MDT consultation are much more than that diagnosed in the first group, keeping in mind the time elapsed for first group (5 years – 23.2 patients per year) in relation to the duration of second group (2.5 years – 62.4 patients per year), this may be related to the growing education of the population and general medical and dental

staff in the knowledge of management of orthognathic surgery needs and benefit ⁽²⁶⁾.

The academic theory that some surgeons believe, the psychological disturbance of the patients due to facial contour change that result from orthognathic surgery, this study prove the reverse, in that one patient doesn't satisfy her post-operative result as shown in Figure (5), in contrast to 86 patients satisfy their results, and forwarded with the finding of Kiyak and Bell⁽¹⁶⁾ who considering the psychological aspects, neuroticism may have a negative effect on the early postoperative phase but not on the long-term outcome.

Postoperative follow up reveal unpleasant blood ooze following segmental surgery, haematoma and edema following mandibular basal surgery, temporary lip parasthesia following maxillary and/or mandibular basal surgery, no patient complaining from permanent complication, only one patient needs a pint of blood to compensate for the lost blood, 3 onlay genioplasty operated under local anaesthesia and all other operation done under general anaesthesia, these finding going closely with Alessandro *et al* ⁽²³⁾. who say that there can be some complications like bleeding, swelling, infection, nausea and vomiting; and also the same as Eckert and Panula *et al* ⁽²⁴⁾.

From what previously discussed multidisciplinary consultation aimed at providing holistic care to patients who are candidates for orthodontic–surgical inter-

vention. In all scenarios, surgical risks are explained to patients who also receive an information pamphlet. They can therefore ask questions about the treatment phases, the surgery itself, the postoperative effects, and the orthodontic treatment⁽²⁶⁾.

CONCLUSIONS

From the aspect of this study need for surgical correction of facial and gnathic deformities is getting increase with the advances of patients understanding. MDT clinic will contribute three handed subject: patient's real complaint, team work decision and medical staff education. For improve good quality surgeries with correct decision, less complications, patient satisfaction better to maintain MDT clinic.

REFERENCES

1. Wolford L M, Fields RT. Surgical planning. In: Booth PW, Schendel SA, Hausamen JE, eds. Maxillofacial surgery, 1999:1205–57.
2. Proffit WR, White RP Jr. Who needs surgical orthodontic treatment? *Int J Adult Orthodon Orthognath Surg*, 1990, 5:81–9.
3. Ong MAD. Spectrum of dentofacial deformities. *Ann Acad Med, Singapore*, 2004, 33:239–42.
4. Bryn Mawr, Rosemont, Criteria for Orthognathic Surgery, AAOMS, 9700 W. IL 60018, Published 1999 Nov. Accessed Aug 31,2006
5. Steinhauser EM. Historical development of orthognathic surgery. *J Craniomaxillofac Surg*, 1996, 24:195–204.
6. Drommer RB. The history of “Le Fort I osteotomy”. *J. Oral Maxillofac*, 1986, 14:119–22.
7. Proffit WR, White RP., The need for surgical orthodontic treatment. Jr, eds. *Surgical orthodontic treatment*. Mosby, St Louis, 1991:2–23.
8. Proffit WR, Turvey TA, Phillips C. Orthognathic surgery: a hierarchy of stability. *Int J Adult Orthodon Orthognath Surg*, 1996, 11:191–204.
9. Woldorf LM, Fields RT. Surgical planning. In: Booth PW, Schendel SA, Hausamen JE, eds. *Maxillofacial surgery*. London, Churchill Livingstone, 1999:849–61
10. Proffit WR et al. Prevalence of malocclusion and orthodontic treatment in the United States: estimates from the NHANES III survey. *Int J Adult Orthodon Orthognath Surg*, 1989, 13:97–106.
11. Permert L, Karlander EL, Wilhelm E. Treatment of malocclusions in children

- and adolescents at a public dental service clinic in Sweden: extent and cost. *Swed Dent J*, 22:187–193.
12. Burgersdij R, Truin G., Frankenmolen F., Kalsbeek H. et al. Malocclusion and orthodontic treatment needs of 15–74-year-old Dutch adults. *Community Dent Oral Epidemiol*, 1991, 19:64–7.
 13. Cunningham SJ, Hunt NP, Feinmann C. Psychological aspects of orthognathic surgery: a review of the literature. *Int J Adult Orthodon Orthognath Surg*, 1995, 10:159–72.
 14. Rodrigues-Garcia RCM, Sakai S., Rugh JD., Hath JP. Tiner BD., et al. Effects of major class II occlusal correction on temporomandibular signs and symptoms. *J Orofac Pain*, 1998, 12:185–92.
 15. Wolford LM, Stevao LL, Alexander CM, Goncalves JR, et al. Orthodontics for Orthognathic Surgery. An Issue of Oral and Maxillofacial Surgery Clinics of North America, E-Book. Elsevier Health Sciences, December / 2019, PP 240.
 16. Kiyak HA, Bell R. Psychological considerations in surgery and orthodontics In: Proffit WR, White RP Jr, eds. *Surgical-orthodontic treatment*. St Louis, Mosby Year Book 1991:71–91.
 17. Pogrel MA, Scott P. Is it possible to identify the psychologically “bad-risk” orthognathic surgery patient preoperatively? *Int J Adult Orthodon Orthognath Surg*, 1994, 9:105–110.
 18. Sadekand H., Salem G.. Psychological aspects of orthognathic surgery and its effect on quality of life in Egyptian patients, *La Revue de Santé de la Méditerranée orientale*, Vol. 13, No 1, 2007
 19. Miskowski RA, Zinser MJ., Kubler AC., Krug B. et al. Application of an augmented reality tool for maxillary positioning in orthognathic surgery - A feasibility study. *J Craniomaxillofac Surg*. 2006 Dec;34(8):478-83. Epub 2006 Dec 8.
 20. Uechi J., Okayama M., Shibata T., Muguruma T., et al.; A novel method for the 3-dimensional simulation of orthognathic surgery by using a multimodal image-fusion technique , *AJO-DO*, Volume 130, Issue 6, December 2006, Pages 786-798.
 21. Arnett GW., Gunson MJ.. Facial Planning for Orthodontists and Oral Surgeons. *Am J Orthod Dentofacial Orthop* 2004 Sep;126(3):290-5.

22. Prinsell JR Maxillomandibular advancement surgery in a site-specific treatment approach for obstructive sleep apnea in 50 consecutive patient's Chest 1999 Dec; 116(6):1519-29.
23. Alessandro CS., Felice OR., David BP.. Postoperative Nausea and Vomiting (PONV) After Orthognathic Surgery: 9, September 2006, Pages 1385-1397
24. Eckert AW., Maurer P., Kriwalsky MS., Schubert J.. "Complications in orthognathic surgery". J CRANIO MAXILL SURG 34 .September 2006. PP. 206. doi:10.1016 /S1010-5182(06)60797-X.
25. Panula, K; Finne K, Oikarinen K. (2001). "Incidence of complications and problems related to orthognathic surgery: a review of 655 patients.". J Oral Maxillofac Surg 59 (59): 1128–36. doi:10.1053/joms.2001.26704.
26. Kerbrat A., Kerbrat J.B., Bourlon A.S., Schouman T., etal. The multidisciplinary approach to orthodontic–surgical protocols in the Maxillofacial Department of Pitié-Salpêtrière Hospital. J Dentofacial Anom Orthod 2016; 19:308. DOI: 10.1051/odfen/2016006