

Foreign Body Inhalation: A shift in Clinical Pattern

Rabea S. A. Al Sofi* , Ziad T. Mahmood** , Omer M. T. Hammodat ***

*Department of Thoracic and Vascular Surgery, Al-Jumhori Teaching Hospital in Mosul City, Mosul.

**Department of Surgery, College of Medicine, Mosul University, Mosul.

***Department of Thoracic and Vascular Surgery, Al-Jomhori Teaching Hospital , Mosul.

Correspondence: ziadtariqmahm@uomosul.edu.iq

(Ann Coll Med Mosul 2019; 41 (2):178-183).

Received: 9th Dec. 2018; Accepted: 8th Sep. 2019.

ABSTRACT

Background: Foreign body inhalation is a common presentation in thoracic surgery and it is well known to present mainly in toddlers, commonly due to sun flower seeds or water melon seeds.

Objectives: To determine the changes in clinical pattern of foreign body inhalation regarding the age, sex, and type of foreign body.

Methods: This is a case series study of patients with foreign body inhalation admitted to Al-Jumhori teaching hospital in Mosul. The parameters used in this study are sex, age group and type of foreign body.

Results: The main age group affected was adolescents, and the commonest foreign body inhaled was the veil pin.

Conclusion: The bad habit of holding pins in mouth while doing other things with your hand has led to this change in clinical pattern of foreign body inhalation.

Keyword: Foreign body inhalation, veil pin, adolescent females.

استنشاق جسم غريب : تحول في النمط السريري

ربيع سالم عبد الجبار* ، زياد طارق محمود** ، عمر مظفر حمدون*

*شعبة جراحة الصدر ، مستشفى الجمهوري ، الموصل **فرع الجراحة ، كلية الطب ، جامعة الموصل ، الموصل ، العراق

الخلاصة

خلفية تاريخية: استنشاق جسم غريب هو من الاعراض الشائعة في جراحة الصدر ومن المعروف انها عادة تصيب الاطفال بسبب بذور زهرة الشمس او بذور البطيخ.

اهداف الدراسة: لتحديد التغيرات في النمط السريري لاستنشاق الجسم الغريب فيما يتعلق بالعمر والجنس ونوع الجسم الغريب. **الاسلوب:** هذه دراسة للسلسلة من الحالات للمرضى الذين يعانون من استنشاق جسم غريب تم استقبالهم في مستشفى الجمهوري التعليمي. المتغيرات المستخدمة في هذه الدراسة هي الجنس والفئة العمرية ونوع الجسم الغريب.

النتائج: الفئة العمرية الرئيسية المتأثرة هي المراهقات. وكان الجسم الغريب الاكثر شيوعا الذي تم استنشاقه هو دبوس الحجاب. **الاستنتاج:** العادة السيئة بوضع او ابقاء الدبوس في الفم اثناء القيام بأعمال اخرى باليدين ادت الى هذا التغيير في النمط السريري لاستنشاق الاجسام الغريبة.

الكلمات المفتاحية: استنشاق جسم غريب , دبوس الحجاب , المراهقات

INTRODUCTION

Tracheobronchial foreign body inhalation (FBI) is a potentially life-threatening event, because it can block respiration by obstructing the airway, thereby impairing ventilation and oxygenation. FBI in children may be suspected on the basis of a choking episode if such an episode is witnessed by an adult or remembered by the child. In contrast, the clinical presentation of unwitnessed FBI may be subtle, and diagnosis requires careful clinical assessment and the judicious use of radiography and bronchoscopy¹.

The first report of the removal of an airway foreign body by bronchoscopy dates back to 1897. The procedure was carried out by Gustav Killian, a doctor who was part of the clinical staff of the University of Friburg in Brisgau, Germany¹.

FBI is associated with significant morbidity and mortality. In USA, 500-3000 children every year die of foreign body inhalation².

75% of cases of FBI occur in children less than 3 years old³⁻⁵. In the USA, FBI is the sixth most common cause of accidental death in children^{6,7}. It is responsible for 12% of toy-related injuries in the US and accounts for 7% of accidental deaths in children <4 years old, with a peak incidence of FBI in the second year of life^{5,8-10}. The epidemiology is similar across countries¹¹.

The high incidence of tracheobronchial foreign bodies in toddlers is probably due to the oral-centred focus of exploration of environment characteristic of these early childhood years¹², coupled with the absence of molar teeth¹³. Most studies show that fewer than 15% of foreign body aspirations occur among children older than 5 years of age¹⁴.

In adults, foreign body aspiration accounts for 20% of reported cases of aspiration^{15,16}. The risk is higher in older people, especially in and after the seventh decade, probably because of a higher prevalence of aging-associated degenerative neurological and cerebrovascular disorders that can cause dysphagia and/or impaired cough reflex, and have various oral appliances^{15,17,18}.

The prevalence of foreign body aspiration is more common in boys^{4,10,14,19,20}.

In Western society, peanuts are the commonest foreign bodies inhaled^{21,22,23,24}, while watermelon seeds are the most commonly inhaled foreign bodies in Middle Eastern countries^{25,26}. In Iraq the most common foreign body is sunflower seeds⁵. Older children are more likely to aspirate non-food items such as pen caps, pins and paper clips²⁶.

METHODS

This is a case series study of 105 patients with FBI admitted to the Emergency Department / Al-Jumhuri Teaching Hospital / Mosul City in the period between the 1st of March 2011 & the 1st of May 2013.

The data were collected from the patients & their relatives as well as from their case sheets.

Time of presentation post pin inhalation was within the first 24 hours post inhalation for most cases. Most patients were referred from other health care facilities or other primary health centers or from private clinics. These patients needed admission to the emergency department with putting up an i.v. line, i.v. drugs and all performed at least one chest x-ray prior to bronchoscopy and some needed another x-ray post-bronchoscopy. A rigid bronchoscopy was performed for all patients in the emergency operative room under general anesthesia and mechanical ventilation. Some patients needed admission to the surgical ward postoperatively for observation over night or at least few hours post scope. A few discharged immediately post bronchoscopy while some needed admission to the intensive care unit for management of bronchospasm or laryngospasm as complication of the whole event. All patients were discharged well.

Sex distribution

Females affected more than males (Figure 1).

- 32 Males (30.5 %).
- 73 Females (69.5 %).

Age of patients:

The patients were classified according to the age into 7 groups:

- -9 patients (less than 1 year old)
- 34 (1 – 9 year)
- 41 (10 – 19 year)
- 15 (20 – 29 year)
- 4 (30 – 39 year)
- 0 (40 – 49 year)
- 2 (50 – 59 year)

The distribution of age groups is shown in (Figure 2).

Types of Foreign Body

The foreign bodies encountered were mainly veil pin, sun flower seed, water melon seed, beads, plastic objects and others figure 3 .

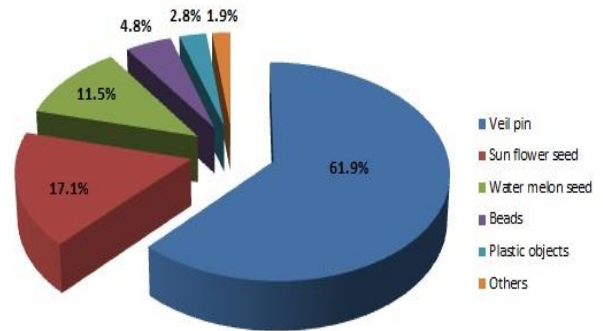


Figure (3): A pie gram showing types of foreign bodies.

RESULTS

Analysis of data defined 7 separate patient groups based upon the age of patients (the age of patients ranged from 6 months to 58 years), and 6 separate patient groups based upon the type of the inhaled foreign body.

Age and Sex Distribution

There is a significant relation between the age and sex in which females being the main sex affected in adolescent age group with a ratio of 7:1 (36 female, 5 males). Also the adolescents are the main age group affected (39.0% of all patients).

The distribution of age and sex was shown in Figure 2 .

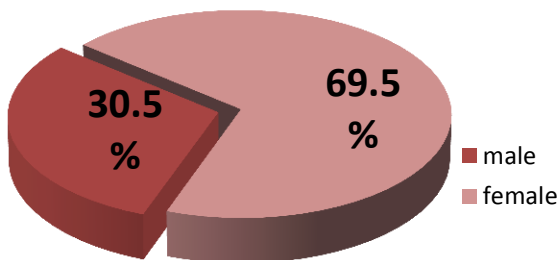


Figure (1): A pie gram showing distribution of patients according to

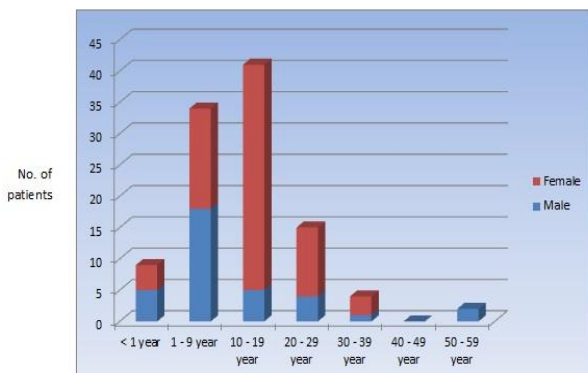


Figure (2): A histogram showing age and sex distribution of patients

Distribution of Foreign Body According to Sex of Patient

There is a significant relationship between the type of foreign body and the sex of the patient, where the veil pin is strongly related to female patients, while all other types of foreign body are slightly more common in males. The main types of foreign bodies encountered according to sex are shown in Table 1 and figure 4 .

Distribution of Foreign Body According to Age of Patient

There is a significant relationship between the type of foreign body and the age of the patient, where the commonest foreign bodies in toddlers are sun flower seeds and water melon seeds, while veil pin is the most common foreign body in adolescents.

The types of foreign bodies according to the age are shown in figure 5 .

Table 1 : Distribution of foreign body according to sex of patient.

Type of FB	Total no.	No. of males	No. of females
1 Veil pin	65	11	54
2 Sun flower seed	18	11	7
3 Water melon seed	12	7	5
4 beads	5	2	3
5 Plastic objects	3	2	1
6 Other materials (bean, metal piece)	2	2	-

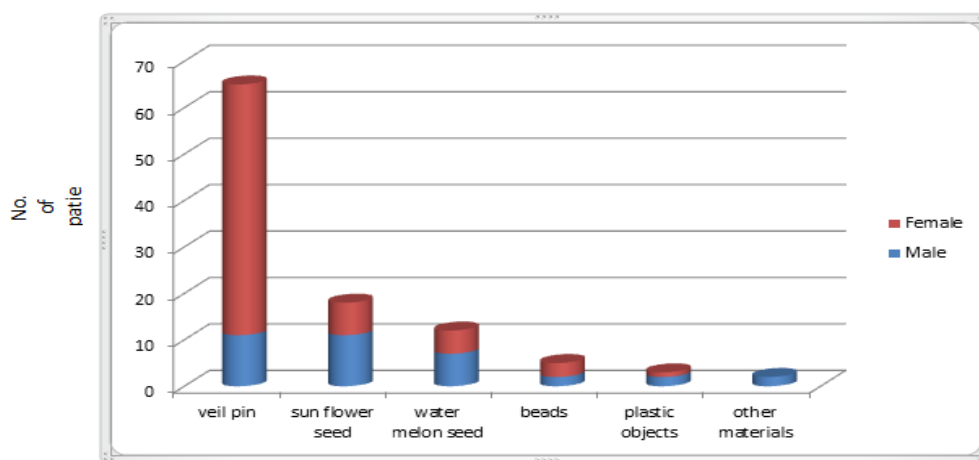


Figure (4) : A histogram showing the distribution of foreign bodies according to sex of patient.

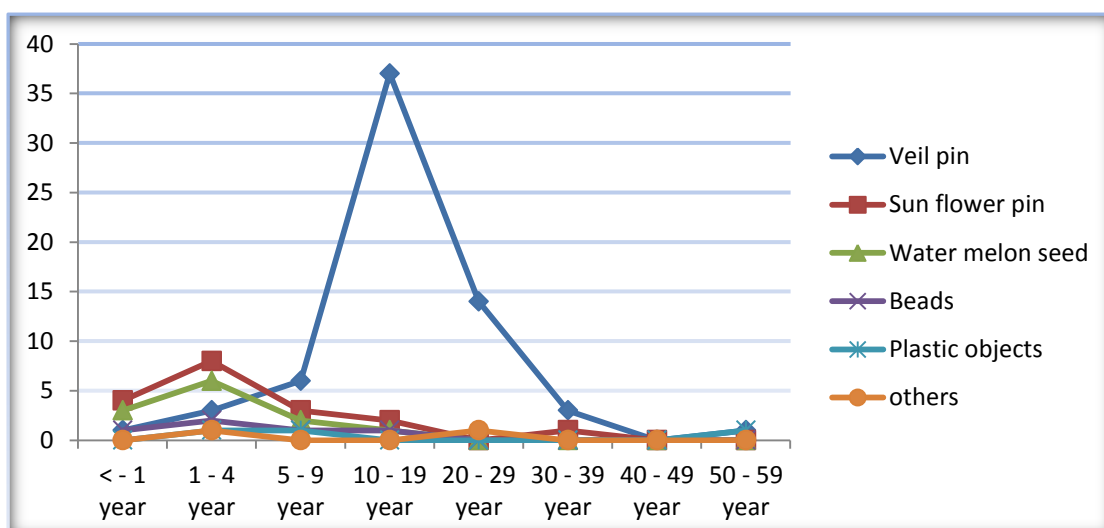


Figure 5 : A histogram showing the distribution of foreign body according to age of patient.

DISCUSSION

The main age group affected was adolescents (10–19 years old) which represented 39.0% of all patients, while toddlers (1 - 4 years old) represent only 20% of total number of patients. These results are greatly different from the results of other studies in different nearby cities or distant countries, e.g.; Ramos et al, Ozhan Kula et al of Turkey and Sherko Saeed study of Iraq in which toddlers represent about 75% of cases^{3,4,5}. With other studies found the peak incidence of foreign body inhalation in the second year of life, e.g.; Sherko Saeed study, Baharloo F et al, Dayang Zuraini Sahadan et al, and Bittencourt and Camargos studies^{5,8,9,10}.

In this study, the male percentage were 30.5% and females were 69.5%. This is also different from other studies in which the frequencies is more common in males e.g.; Ozhan Kula et al, Bittencourt and Camargos, and Joshua and Bradley Aliakbar et al^{4,10, 14,19,20}.

The commonest inhaled foreign body in this study was the veil pin used for fixation of veil (Hejab) representing 65 patients (61.9%) followed by sun flower seeds 18 patients (17.1%) then water melon seeds 12 patients (11.5%). This is greatly different from other studies, where in western society, peanuts are the commonest foreign bodies inhaled as seen in Wiseman NE, Stroe M, Mc Guirt et al and Black et al studies^{21,22,23,24}. While watermelon seeds are the most commonly inhaled foreign bodies in Middle Eastern countries as proven by Elhassani NB and Aytac et al studies^{25,26}. In Iraq the most common inhaled foreign body is sunflower seeds as seen by Sherko Saeed study⁵.

These results show significant differences in this study from others in terms of age, sex and type of inhaled foreign body. The high incidence of tracheobronchial foreign bodies in adolescent females and the significant change in the type of foreign body is due to the use of veil pin in fixation of head veil and the bad habit of putting the pin in the mouth while preparing the head veil.

CONCLUSION

Adolescent females are the most commonly affected group and the veil pin is the commonest type of inhaled FB. This is due to change in the habits of fixation of the wearied veil (Hejab) by the use of veil pin and the bad habit of holding the pin in the mouth while fixing the veil in place.

RECOMMENDATIONS

Education of the general population about the risks of putting pins in the mouth while fixing veils by the means of media and health promotion units and change to use other safe methods to fix veils (clips, .. etc.).

A simple advice to put the pin on the table or on the mirror edge rather than in the mouth can be all that is required.

These patients and these problems are burdening our health programs and health institutes with the time, cost and risks associated with managing such problem. But this dilemma can be avoided, if the public were to know the consequences or risks associated with this simple act of putting a pin or a nail or a screw in the mouth especially when talking, shouting or being in a hurry. A simple brochure or a short TV or radio advertisement may be all that it takes to save life and money. It is simple and it is dangerous but it is avoidable.

REFERENCES

1. Fleischer K. Erkennung und Entfernung Von. Bronchial-frem-dkorpereinst Jetzt. *Ther Ggengenw* 1974;113:348-58.
2. Calboon JH, Grover FL. Tracheobronchial aspiration in: Webb WR, Ileson A (eds). *St. Louis Mosby year book of thoracic surgery*, 1991, pp.142-50.
3. Ramos MB, Fernandez-Villar A, Rivo JE, et al. Extraction of airway foreign bodies in adults: experience from 1987-2008. *Interact Cardiovasc Thorac Surg*. 2009;9:402-405.
4. Özhan Kula, MD; Sinan Gürkan, MD; Hilal Altınöz, MD; Özlem Yazıcı, MD; Özer Ocaklı, MD; Seyhan Us Dülger, MD; Gülderen Dolunay, MD. Foreign Body Aspiration in Infants and Children. *SSK Süreyyapafla Thoracic Diseases Center, İstanbul, Turkey. Turkish Respiratory Journal*, 2003;4:(2):76-78.
5. Sherko Saeed F. Zmnako; College of Medicine, University of Sulaimani. Kurdistan Region, Iraq. Aso S. Marouf; ENT Department, Sulaimani Teaching Hospital. Kurdistan Region- Iraq. Use of Rigid Bronchoscopy in the Management of Children with Suspected Foreign Body Inhalations. *Kurdistan Academicians Journal*, 2009/2010, 7, 8 (1) part A (37-47)

6. Centers for Disease Control and Prevention (CDC). Toy-related injuries among children and teenagers - United States, 1996. *MMWR Morb Mortal Wkly Rep.* 1997;46:1185-1189.
7. Mantor PC, Tuggle DW, Tunell WP. An appropriate negative bronchoscopy rate in suspected foreign body aspiration. *Am J Surg.* 1989;158:622-624,
8. Baharloo F, Veyckemans F, Francis C, et al. Tracheobronchial foreign bodies: presentation and management in children and adults. *Chest.* 1999;115:1357-1362.
9. Dayang Zuraini Sahadan, MMed (Paeds), Norzila Mohamad Zainudin, MMed (Paeds), Asiah Kassim, MMed (Paeds), Zakaria Zahari, FRCS, Mazlinda Mahadzir, MMed (ENT), Che Zubaidah Che Daud, MMed (Radiology), Noryati Mohammad, MMed (Radiology); Case Series of Foreign Body Aspiration in Paediatric Institute, Hospital Kuala Lumpur; Hospital Kuala Lumpur, Paediatric, Jalan Pahang, Kuala Lumpur, Wilayah Persekutuan 50586, Malaysia, 2010.
10. Paulo F.S. Bittencourt, Paulo A.M. Camargos. Foreign body aspiration. *Jornal de Pediatria.* 0021-7557/02/78-01/9.
11. Righini CA, Morel N, Karkas A, et al. What is the diagnostic value of flexible bronchoscopy in the initial investigation of children with suspected foreign body aspiration? *Int J Pediatr Otorhinolaryngol.* 2007;71:1383-1390.
12. Kolb LC. *Modern Clinical Psychiatry.* London: WB Saunders, 1977: 62-82.
13. Kim G, Brummitt WM, Humphrey A, Siomra SW, Wallace WB. Foreign body in the airway: a review of 202 cases. *Laryngoscope* 1973;83: 347-354.
14. Joshua D. Rovin and Bradley M. Rodgers. Pediatric Foreign Body Aspiration. *Pediatrics in Review* 2000;21;86. DOI: 10.1542/pir.21-3-86.
15. Boyd M, Chatterjee A, Chiles C, et al. Tracheobronchial foreign body aspiration in adults. *South Med J.* 2009;102:171-174.
16. National Safety Council. *Leading causes of death: an excerpt of injury facts.* Chicago, IL: National Safety Council Press; 2003:10-15.
17. Smith Hammond CA, Goldstein LB. Cough and aspiration of food and liquids due to oral-pharyngeal dysphagia: ACCP evidence-based clinical practice guidelines. *Chest.* 2006;129(suppl 1):S15-S168.
18. Limper AH, Prakash UB. Tracheobronchial foreign bodies in adults. *Ann Intern Med.* 1990;112:604-609.
19. Aliakbar Rahbarimanesh, MD, Pediatric Infectious Diseases Specialist; Elaheh Noroozi, MD, Resident in Pediatrics; Mansour Molaian, MD, Pediatric Surgeon; Piman Salamati, MD, Community Medicine Specialist; Foreign Body Aspiration: A five-year Report in a Children's Hospital. Bahrami Children's Hospital, Tehran University of Medical Sciences, IR Iran. *Iran J Pediatr Jun* 2008; Vol 18 (No 2), Pp:191-192.
20. [Medscape.com](http://www.medscape.com), 2013.
21. Wiseman NE. The diagnosis of foreign body aspiration in childhood. *J Pediatr Surg* 1984; 19: 531-535.
22. Strome M. Tracheobronchial foreign bodies; an updated approach. *Ann Otol Rhinol Laryngol* 1977; 86: 649-654.
23. Mc Guirt WF, Holmes KD, Feehs R, Browne JD. Tracheobronchial foreign bodies. *Laryngoscope* 1988; 98: 615-618.
24. Black RE, Choi KJ, Syme WC, Johnson DG, Matlak ME. Bronchoscopic removal of aspirated foreign bodies in children. *Ann J Surg* 1984; 148: 778-781.
25. Elhassani NB. Tracheobronchial foreign bodies in the Middle East. *J Thorac Cardiovasc Surg* 1988; 96: 621-625.
26. Aytac A, Yurdakul Y, Ikizler C, Olga R, Saylam A. Inhalation of foreign bodies in children. *J Thorac Cardiovasc Surg* 1977; 74: 145-151.