

Intra-Gastric Balloon, an Aid for Weight Reduction in Obese Patient

Professor Nashwan Qahtan Mahgoob

Department of surgery, College of medicine, University of Mosul, Mosul

Correspondence: nashwanmahgoob@yahoo.com

Mobile 07701603690

(Ann Coll Med Mosul 2019; 41 (2):158-162).

Received: 14th Oct. 2019; Accepted: 1st Dec. 2019.

ABSTRACT

Background: we share our experience with an intra-gastric balloon to evaluate the safety, tolerability, and efficacy for patients with class one and two obesity. Methods: From January 2015 to January 2017, intra-gastric balloons were inserted in the stomachs of 85 patients at the endoscopy unit in CMC Hospital Erbil/Kurdistan/ Iraq. All the patients had a body mass index between 30 to 39 kg/m² and were within the age range of 17-50 with a mean age of 29 years, there were 55 female 30 male patients, the patients underwent consent, pre balloon insertion investigation tests and anesthesia evaluation. The balloon was inserted via an upper endoscopy device after diagnostic study and then it was filled with 550-600 (mills) of stained saline. All patients' were given an analgesic and antiemetic for a week and anti-secretory proton pump inhibitors for 6 months. Diet and the importance of the exercise were part of the program phase and protocol during the period of the study. The balloon was removed after 6 months. The patients were followed during the 6 months of insertion and 6 months after the removal. The weight reduction and complications were documented and reported.

Results: Satisfactory weight loss was obtained in 85% of patients after six months and 75% after 12 from insertion respectively. One patient underwent early removal of the balloon after 7 days of insertion; another patient had balloon leak and shrinkage which necessitated replacement by another one. Early postoperative pain and vomiting were universal but subsided in 90% during the first 10 days.

Conclusion: in well-selected patients the intra-gastric balloon is an effective tool that can be used to achieve weight loss with minimum complications.

Keyword: Obesity. Intra-gastric balloon. Diet regime.

استخدام بالون المعدة كعامل مساعد في انقاص الوزن لدى المرضى المصابين بالسمنة

الأستاذ نشوان قحطان محجوب

فرع الجراحة ، كلية الطب، جامعة الموصل، الموصل، العراق

الخلاصة

الخلفية: نشارك تجربتنا مع بالون المعدة لتقييم السلامة والتحمل والفعالية لمرضى السمنة من الدرجة الأولى والثانية. الأساليب: من كانون الثاني ٢٠١٥ إلى كانون الثاني ٢٠١٧ ، تم إدخال بالون المعدة في ٨٥ من المرضى في وحدة التنظير التابعة لمستشفى س م س.

مؤشر كتلة الجسم ما بين ٣٠ إلى ٣٩ كجم / م ٢ وكانوا ضمن الفئة العمرية ١٧-٥٠ مع متوسط عمر ٢٩ سنة ، ضمت الدراسة ٥٥ أنثى ٣٠ مريضاً من الذكور ، وخضع المرضى للموافقة على التداخل واتباع الارشادات. تم إدخال البالون عبر جهاز التنظير

العلوي بعد دراسة تشخيصية ، تم ملئ البالون بـ ٥٥٠-٦٠٠ مللتر من المياه المالحة الملونة بصيغة المثلين الزرقاء. تم إعطاء مسكن ومضاد للقيء لجميع المرضى لمدة أسبوع ومثبطات مضخة البروتون المضادة للإفراز لمدة ٦ أشهر. كان النظام الغذائي و التمرين الرياضي جزءاً من مرحلة البرنامج والبروتوكول خلال فترة الدراسة. تمت إزالة البالون بعد ٦ أشهر. تمت متابعة المرضى خلال ٦ أشهر من وضع البالون و ٦ أشهر بعد الإزالة. تم توثيق انخفاض الوزن والمضاعفات والإبلاغ عنها. النتائج: تم الحصول على خسارة مهمة للوزن في ٨٥ ٪ من المرضى بعد ستة أشهر و ٧٥ ٪ بعد ١٢ من وضع البالون على التوالي. خضع مريض واحد لإزالة البالون مبكراً بعد ٧ أيام من وضعه. مريض آخر أصيب بتسريب سائل البالون وانكماشه مما استلزم استبداله بآخر. كان الألم والقيء اللاحق للعمليات الجراحية في وقت مبكر لدى الجميع ولكنهما اختلفيا بنسبة ٩٠٪ خلال الأيام العشرة الأولى.

الخلاصة: في المرضى الذين يتم اختيارهم بشكل جيد ، يعد البالون المعدة أداة فعالة يمكن استخدامها لتحقيق فقدان الوزن مع الحد الأدنى من المضاعفات.

الكلمة المفتاحية: السمنة. بالون المعدة. النظام الغذائي.

INTRODUCTION

Obesity considered being a major health problem all over the world. The World Health Organization reports that worldwide, more than 1.9 billion adults, 18 years and older, were overweight. Of these over 650 million were obese¹. An estimated 115 million of these people will develop serious medical conditions, including diabetes mellitus, cardiovascular diseases, stroke, liver problems, and cancer. Studies show that those potentially life-threatening conditions can be improved with weight loss². Effective weight management for individuals with obesity can be carried on in many ways, what with a trail of pharmacological approaches was not achieving any significant outcomes³. Bariatric surgery has provided significant weight reduction and gained popularity, but there is a price to pay for there, which could be complications in the procedure or its outcome, as well as associated major morbidities and even mortality. There is, therefore, growing demand for less invasive approaches.

Since 1982, intra-gastric balloons have been used to induce early satiety by decreasing the capacity of the gastric reservoir thereby reducing food intake leading to weight loss as well as it causes the food to stay longer in the stomach making the patient feels full for a longer time. Gastric balloons have been upgraded and improved and several papers on them with conflicting results have been published^{4,5,6}.

This paper presents our experience of the safety, tolerance and weight reduction efficacy of the intra-gastric balloon in class one and two obese patients in our region

PATIENTS AND METHODS

The study included eighty-five patients with class 1 and 2 obesity. There were 30 males and 45

females in the age range of 17-50 years with a mean age of 29 years. The criteria for inclusion were as follows:

- 1- Body mass index of 30 to 39kg/m²
- 2- Failure to achieve weight control by means of lifestyle modification with or without pharmacological agents.

Accept the procedure and follow up, that includes:

- Removal not allowed without a definite indication.
- Follow diet control and regular exercise during and after the insertion.
- Visit the doctor according to the special schedule given to the patient.

Exclusion Criteria were as follows:

- 1- Endocrine diseases cause obesity.
- 2- Pregnancy, or planning to get pregnant.
- 3- Presence of gastric lesions such as active peptic ulcer disease, or hiatus hernia more than 3 cm or grade 2 gastroesophageal reflux.
- 4- Previous gastric surgery.
- 5- Patients on anticoagulants, alcoholics, or drug abusers.

Patients gave their consent. Basic laboratory tests, including full blood count, biochemical profile, glycated hemoglobin, electrocardiogram, viral screen, abdominal ultrasound, and anesthetic evaluation were done, the procedure performed under monitored anesthesia care at the endoscopy unit at CMC hospital Erbil/ Iraq. All the patients instructed to have fasting 8 hours before the procedure.

The first step was diagnostic esophagogastroduodenoscopy to rule out any pathology that would preclude balloon insertion. After the removal of the scope, a collapsed balloon with its filling tube was inserted into the stomach after adequate lubrication of the balloon sheath by

xylocaine gel. The location of the collapsed balloon was controlled near the antral region by re-inserting the scope under direct vision, the guidewire removed; the balloon was filled with 550-600 mills of saline stained with 10 mills of methylene blue). As shown in figure 1,2,3.

After the balloon had been filled, the filling tube gently detached from the balloon and taken out. The mean procedure time was 25 min. The patients were kept for 10 hours for post-procedure care and discharged home. They were allowed to start liquid after 6 hours and to start on a soft diet the 2nd day and to eat the usual food after 7 days.

Antiemetic and analgesic medication (Ondansetron and acetaminophen) injection were used in the post-operative time and then changed to oral route for 3 to 5 days. Proton pump inhibitor (PPI) 20 mg once daily was prescribed for the whole six months.

The balloon was removed after 6 months under monitored anesthesia care with endotracheal intubation at the endoscopy unit at the operative theatre. The average time for the removal of the balloon was 20 minutes; patients were discharged 4 hours after the procedure, with the advice to continue the diet and exercise protocol and to visit the doctor according to the appointment given.

Regarding weight loss assessment, we divide the patients into 3 levels, level one included those who had satisfactory results after 6 months in which they lost 25% or more from original weight and remain so after 12 months from insertion, fair result level were those who lost 15 to 24 from their original weight, unsatisfactory level included those who showed decrease of 14% or less from their original weight, the weight loss percentage has been calculated by using the following formula: kg lost divided by starting weight, then, multiply the result by 100.

RESULTS

On account of intolerance, predictable features experienced by most of the patients included: nausea, vomiting, and abdominal cramps. One patient had the balloon removed 7 days after the initial insertion and excluded from the study. Otherwise, with 5 to 7 days of antiemetic and analgesics, the procedure was generally well tolerated and the balloon remained for the scheduled period. In one patient, evidence of

balloon leakage was noticed by a change in his urine color 2 months after insertion, the patient underwent removal of the damaged balloon and replacement of a new one, the follow up for her weight reduction started from the second balloon insertion time. All patients recovered uneventfully from anesthesia during insertion and removal procedures.

The outcome in our patients was classified into three groups. Group 1 (satisfactory result) accounted for 85%, 75% of patients whose maximum weight loss was more than 25% from their original weight after 6 months and remained after 12 months from insertion respectively. Group 2 (fair result) represented 10%, and 14.5% of the patients, who had lost between 15% to 24 from their original weight after 6, and 12 months from insertion respectively. Group 3 (unsatisfactory result) represented 5%, and 10.5% of the patients. They had been unable to achieve perfection and had lost less than 14% or less after 6 months, and 12 months respectively. As shown in Table 1

DISCUSSION

The deployment of an intra-gastric balloon to promote weight loss was first reported by Nieben et al in 1982⁷. The intra-gastric balloon is becoming a popular weight loss device as an alternative to surgery especially in those with class one and two obesity. Over the years, several researchers have tried different balloon types⁸. We used an intra-gastric balloon of spherical shape with a volume capacity (500 to 600 mills) and is filled with saline. Gastric balloon procedures were approved in the United States in 2015 for patients with a BMI of 30 to 40 that have not had previous weight loss surgery but are currently not covered by insurance⁹. Intra-gastric balloon act by reducing the available room in the stomach for food. The average stomach is 1.5 L in volume and the average gastric balloon takes up close to half of that space, physically the patient not able to eat as much in one setting, furthermore, it restricts the free passage of food and water, essentially slowing its passage through stomach, making patient feel full quicker and longer.

Obviously, the outcome is not comparable with the results obtained in bariatric surgery, but noteworthy to said that it doesn't require surgery, no incisions or scarring, typically calls for very little

recovery time, not permanent, not invasive, no need for vitamin supplementation, patient can return to her or his work within a 10 days, it may result in long-term weight loss when used in conjunction with a diet and exercise program and lifestyle changes^{10,11}. Complication of intra-gastric balloon is either simple that can be overcome by medication and time like acid reflux, nausea and vomiting which are universal during the first few days, vomiting after eating for the first few weeks is not uncommon but temporary and can be resolved if the patient adapts slow eating and select the type of food^{11,12}. Stomach cramps are common due to the presence of a foreign body in the stomach and can be managed by antispasmodic medication. Three to five days of analgesic and antiemetic found to be extremely helpful for early abdominal pain and vomiting. Proton pump inhibitor was extremely effective for the prevention of ulcer and balloon damage from the effect of gastric acid, follow up of patient is extremely important to overcome such conditions.

The major complications are bleeding, perforation, intestinal obstruction, and death which

has been happened¹³, none of these have been reported in the current study.

Weight loss in our patients was impressive, with the average weight loss of more than 25% of their original weight which changes the patient from one class of obesity to a class below it. However, in the 1-year follow-up, 10% to 15% of the lost weight had been regained which is similar to other studies^{3,7}.

In conclusion: Our data documents that in well-selected patients, an intra-gastric balloon is an effective tool that can be used to achieve weight loss with minimum complications. We believe that patients' motivation and compliance, as well as respect for dietary and behavioral rules, are mandatory to achieve the expected results. We recommend further follow up of our patients for further time to evaluate the benefit of such a procedure for a longer time.

Table 1: weight loss in number and percentage in all groups after 6 and 12 months from insertion.

Time from insertion	*Satisfactory result	**Fair result	***Unsatisfactory result
6 months	72 patients 85%	9 patients 10%	4 patients 5%
12 months	64 patients 75%	12 patients 14.5%	9 patients 10.5%

*satisfactory result means loss of 25% or more from original weight.

**fair result means loss of 15 to 24% from original weight.

***unsatisfactory result means loss of less than 14% from original weight.

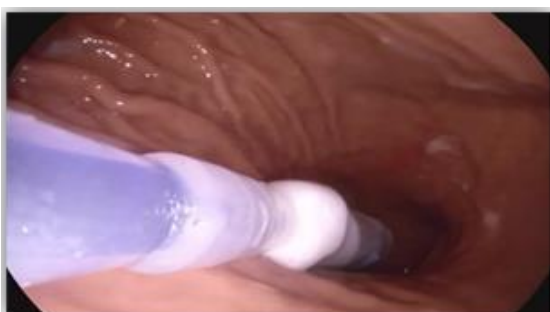

Figure 1: Adjustment of collapsed balloon at antrum.

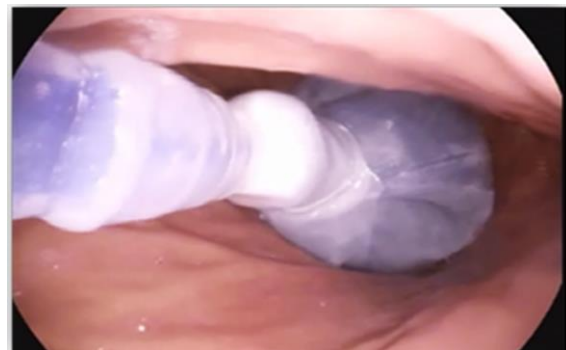

Figure 2: Balloon inflation

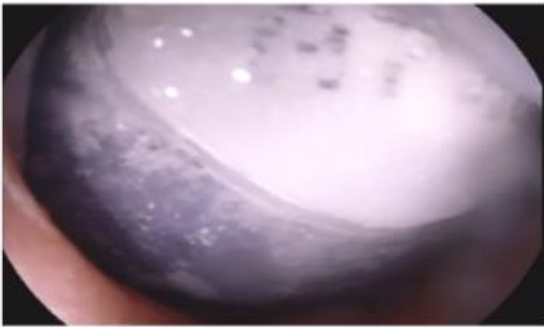


Figure 3: Complete inflation of the balloon

Acknowledgments: Thanks for all workers at endoscopy unit in CMC Hospital Erbil/Kurdistan/Iraq for their support and endless help.

Conflict of Interest: Author has no Conflict of Interest in this research.

All procedures performed in studies involving human participants were in accordance with the ethical standards of the institutional and/or national research committee and with the 1964 Helsinki declaration and its later amendments or comparable ethical standards.

REFERENCES

1. www.oecd.org/health/obesity-update.htm© OECD 2017
2. Genco A, Cipriano M, Bacci V, Cuzzolaro M, Materia A, Raparelli L, et al. BioEnterics Intra-gastric Balloon (BIB): A short-term, double-blind, randomised, controlled, crossover study on weight reduction in morbidly obese patients. *Int J Obes (Lond)* 2006;30:129–33. [PubMed] doi.org/10.1038/sj.ijo.0803094
3. Mohammed I. Yasawy, Abdulaziz A. Al-Quorain, Anas M. Hussameddin, Zakia M. Yasawy, and Raid M. Al-Sulaiman. *J Family Community Med.* Obesity and gastric balloon. 2014 Sep-Dec; 21(3): 196–199. [doi: 10.4103/2230-8229.142977](https://doi.org/10.4103/2230-8229.142977)
4. Ponce J, Quebbemann BB, Patterson EJ. Prospective, randomized, multicenter study evaluating safety and efficacy of intra-gastric dual-balloon in obesity. *Surg Obes Relat Dis.* 2013;9:290–5. [PubMed] doi.org/10.1016/j.soard.2012.07.007
5. Giuricin M, Nagliati C, Palmisano S, Simeth C, Urban F, Buri L, et al. Short-and long-term efficacy of intra-gastric air-filled balloon (Heliosphere® BAG) among obese patients. *Obes Surg.* 2012;22:1686–9. [PubMed]
6. Ganesh R, Rao AD, Baladas HG, Leese T. The Bioenteric Intra-gastric Balloon (BIB) as a

treatment for obesity: Poor results in Asian patients. *Singapore Med J.* 2007;48:227–31. [PubMed]

7. Nieben OG, Haboe H. Intra-gastric balloon as an artificial bezoar for treatment of obesity. *Lancet* 1982; 1:198-9.
8. Roman S, Napoléon B, Mion F, Bory RM, Guyot P, D'Orazio H, et al. Intra-gastric balloon for “non-morbid” obesity: A retrospective evaluation of tolerance and efficacy. *Obes Surg.* 2004;14:539–44. [PubMed]
9. Flavio Augusto Martins Fernandes, Jr, , Gustavo L. Carvalho, , PhD, [Diego L. Lima](#), Intra-gastric Balloon for Overweight Patients. *JLS.* 2016 Jan-Mar; 20(1): e2015.00107. doi: [10.4293/JLS.2015.00107](https://doi.org/10.4293/JLS.2015.00107)
10. Imaz I, Martínez-Cervell C, García-Álvarez EE, Sendra-Gutiérrez JM, González-Enríquez J. Safety and effectiveness of the intra-gastric balloon for obesity. A meta-analysis. *Obes Surg* 2008; 18: 841–846. [PubMed] [Google Scholar]
11. Totté E, Hendrickx L, Pauwels M, Van Hee R. Weight reduction by means of intra-gastric device: experience with the bioenterics intra-gastric balloon. *Obes Surg.* 2001 Aug;11(4):519-23.
12. Flavio Augusto Martins Fernandes, Jr, MD, MSc, Gustavo L. Carvalho, MD, PhD Intra-gastric Balloon for Overweight Patients. *JLS.* 2016 Jan-Mar; 20(1): e2015.00107. doi: [10.4293/JLS.2015.00107](https://doi.org/10.4293/JLS.2015.00107)
13. Al-Momen A1, El-Mogy I. Intra-gastric balloon for obesity: a retrospective evaluation of tolerance and efficacy. *Obes Surg.* 2005 Jan;15(1):101-5. doi.org/10.1381/0960892052993558