

## Helicobacter pylori in Gastric biopsy: A Histochemical and Immunohistochemical Assessment

Zainab Waleed Aziz\* , Shuaib Hashim Saleem\*\* , Hatim Abdulmajeed Al-Nuaimy\*\*\*

\*Department of Pathology, College of Medicine, Ninevah University, Mosul, Iraq, \*\*Department of Pathology, College of Medicine, University of Mosul, Mosul, Iraq, \*\*\*Senior Histopathology , Al-Jumhorii Teaching Hospital, Mosul, Iraq .

Correspondence: zainabwaleed90@yahoo.com

(Ann Coll Med Mosul 2019; 41 (2):139-147).

Received: 16<sup>th</sup> Feb. 2019; Accepted: 15<sup>th</sup> May 2019.

### ABSTRACT

**Background:** Helicobacter species pylori represent one of the medically prominent and most common infections in the world. Contamination with this microbe has set as a causal factor in the development of gastritis, peptic ulcer, and gastric neoplasia. Consequently, prompt diagnosis is essential.

**Objectives:** This study was conveyed to detect *H.pylori* in gastric biopsies specimens by using routine Hematoxylin, Modified Giemsa dye as well as immunohistochemical stain, besides to assess the specificity and sensitivity of Helicobacter microbe detection in each method.

**Patients and methods:** The research was both prospective and retrospective, carried out on 100 cases of endoscopically obtained gastric biopsies. Data obtained from archives of the pathology department, at AL-Jamhuri Teaching Hospital, Mosul city, and collected in a period spanning from April 2013 to March 2014. The information included; Age, sex, gastric biopsy location, inflammation status, the presence of dysplasia or carcinoma. *Helicobacter pylori* infection was assessed histochemically and immunohistochemically.

**Results:** In a total of 100 gastric samples, patients' age range was 11 to 82 years (mean age of 46.5 years), with a male to female ratio of 1.38:1. *Helicobacter pylori* bacilli were positive with H&E/MGS in 71 (71%) of cases, increased to 75 (75%) case with IHC. Chronic gastritis noticed in 85 biopsy specimens, 74% were positive for *H.pylori*. There was a statistically significant difference between IHC and H&E/MGS ( $p=0.04$ ) for detection of *H.pylori*. The sensibility and specificity of the H&E/MGS were measured compared with the recommended standard sensitive and specific IHC test; they were 95% and 100% respectively.

**Conclusion:** The routine ancillary stains request for the detection of *H.pylori* remains a laboratory and an institution right. This study revealed that, in our laboratory, the regular application of ancillary dyes is not obliged for the description of *H.pylori* because it was readily recognizable in the bulk of sections with haematoxylin staining. However, we recommend the use of IHC in specific circumstances.

**Keywords:** *Helicobacter pylori*, Gastric biopsy, Modified Giemsa stain, Immunohistochemistry, Cancer.

### عصيات الملوية البوابية في خزعة المعدة : تقييم كيميائي نسيجي ومناعي كيميائي نسيجي

زينب وليد عزيز\* ، شعيب هاشم سالم\*\* ، حاتم عبد المجيد النعيمي\*\*\*  
\*فرع الامراض ، كلية الطب ، جامعة نينوى ، الموصل ، العراق ، \*\*فرع الامراض ، كلية الطب ، جامعة الموصل ، الموصل ، العراق ،  
\*\*\*اختصاص علم الامراض ، مستشفى الجمهوري التعليمي ، الموصل ، العراق

### الخلاصة

**معلومات أساسية:** عصيات الملوية البوابية تمثل واحدة من الأمراض الأكثر شيوعاً في جميع أنحاء العالم. العدوى بهذه البكتيريا سلبية الغرام قد أنشئ كعامل مسبب في حدوث التهاب المعدة، أورام المعدة، بما في ذلك سرطان غشاء المعدة والأورام الليمفاوية

لأنسجة المعدة المرتبطة بالغشاء المخاطي. ولهذا بالنظر إلى الآثار الموثقة توثيقاً جيداً من ناحية الأمراض التي تسببها هذه البكتيريا، كان من الضروري التشخيص الصحيح والسريع لها.

**الهدف من الدراسة:** أجريت هذه الدراسة للكشف عن بكتيريا الملوية البوابية باستخدام ثلاثة أساليب: صبغة روتينية، صبغة خاصة وكذلك طريقة مناعية- كيميائية- نسيجية في خزعات المعدة. لقد جمعت العينات من مختلف الحالات المرضية للمعدة وقد تم تقييم حساسية وخصوصية الكشف عن هذه البكتيريا في كل أسلوب.

**المرضى والطرق:** إن هذه الدراسة مستقبلية ورجعية أجريت على ١٠٠ حالة. تم الحصول على خزعات المعدة باستخدام الناظور الفموي المعدي. تم الحصول على البيانات من محفوظات قسم علم الأمراض، مستشفى ابن سينا. تم جمع البيانات في الفترة الممتدة من كانون الأول/ ٢٠١٧ والى آب/ ٢٠١٨. وقيمت العدوى بالبكتيريا بطريقتي كيميائي نسيجي ومناعي- كيميائي- نسيجي.

**النتائج:** تراوحت أعمار المرضى بين ١١ إلى ٨٢ عاماً (معدل: ٤٦.٥ سنة) أغلبهم بين ٢١-٣٠ سنة. عصابات الملوية البوابية كانت إيجابية مع الصبغة الروتينية والصبغة الخاصة في ٧١ (٧١٪) من الحالات، بينما مع طريقة مناعية- كيميائية- نسيجية في ٧٥ (٧٥٪) من الحالات. لقد كانت عينات خزعة التهاب المعدة المزمن ٨٥، ٧٤٪ كانت إيجابية بالنسبة للبكتيريا. تم الكشف عن سرطان المعدة (سرطان الغشاء وسرطان الغدد الليمفاوية) في ١٠٪ الحالات، ٥٠٪ كانت مرتبطة مع البكتيريا إيجابياً. كان هناك فرق يعتد به إحصائياً بين طريقة مناعية- كيميائية- نسيجية وكذلك الصبغة الروتينية والصبغة الخاصة ( $p = 0.04$ ) للكشف عن البكتيريا العسوية. الحساسية والنوعية في الصبغة الروتينية والصبغة الخاصة قيست بالمقارنة مع الموصى بها مع طريقة مناعية- كيميائية- نسيجية كانت حساسة ومحددة و كان الاختبار المعياري؛ ٩٥٪ و ١٠٠٪ على التوالي.

**الاستنتاجات:** الحاجة لاستخدام طريقة المناعية- الكيميائية- النسيجية روتينياً للكشف عن هذه البكتيريا يعتمد على المؤسسات والمختبرات. لقد أظهرت دراستنا، انه في مؤسستنا، الاستخدام الروتيني لطريقة المناعية- الكيميائية- النسيجية ليس ضرورياً لتحديد البكتيريا الملوية البوابية وذلك لسهولة رؤيتها بالصبغة الروتينية.

**الكلمات المفتاحية:** عصابات الملوية البوابية، خزعة المعدة، صبغة كيمزا المعدلة، الطريقة المناعية- الكيميائية- النسيجية، سرطان.

## INTRODUCTION

**H**elicobacter pylori (*H. pylori*) represent one of the medically prominent and most common infections worldwide<sup>1</sup>. It is a curved rod gram-negative multi-flagellated bacterium observed virtually solely attached on the gastric mucosa of human beings<sup>2</sup>. Under unfavorable circumstances, it can become viable but non-culturable coccoid form<sup>2</sup>. In gastric biopsies, Helicobacter microbes are 0.5 to 1.0 Mm wide and 2.5 to 5.0 Mm long; they carry up to six unipolar wrapped flagella which are crucial for bacterial movement<sup>3</sup>. Flagella manifests a specific end bulb, which is an expansion of the flagellar case<sup>3</sup>. In developing countries, 70% to 90% of the people carries *H. pylori* before the age of 10 years<sup>3</sup>. In developed countries, the prevalence of infection is lower, varying from 25% to 50%<sup>4</sup>. The rate of new *H. pylori* infections among adults in the Westerly world is less than 0.5% per year<sup>5</sup>. Since spontaneous elimination of the infection is rare, it proceeds in most cases to chronic gastritis<sup>6,7</sup>. However, the cytokine response and the gastric

acid secretion are bound for an individual's ultimate clinical outcome<sup>8</sup>. It has found that a reduction in the production of gastric acid predisposes to corpus gastritis or pangastritis which in turn leads to gastric ulcer, atrophy, and carcinoma<sup>9,10</sup>.

In gastric cancer, irrespective of their histology, most of these tumors originate from mucosa infected by *H. pylori* and very rarely occur without inflammation. Therefore, *H. pylori* are considered to be a strong factor in the evolution of gastric cancer<sup>11,12</sup>.

Therefore, regarding all facts about the strong correlation between *H. pylori* and different upper gastrointestinal lesions, it is very crucial to specify the presence of this bacteria in gastric biopsy reports as it has an important role in the therapeutic implications too<sup>13</sup>. Since, over years pathologists have sought different reliable methods for detecting *H. pylori* in biopsy specimens, including special stains, immunohistochemistry (IHC), polymerase chain reaction (PCR) and lately, in situ hybridization<sup>14</sup>.

## PATIENTS AND METHODS

### Patient Selection

This study was a prospective and retrospective carried out in a series of 100 consecutive endoscopically obtained gastric biopsies during a period spanning from April 2013 to March 2014. A tissue block of each case was chosen for histochemistry and IHC.

We maintained a routine protocol approval to access the clinicopathological data from archives of the department of pathology laboratory, at AL-Jamhuri Teaching Hospital, Mosul City, and these included; Age (ranged from 11 to 82 years with a mean of 46.5 years), sex (58 males and 42 females with a male to female ratio of 1.38:1), gastric biopsy location .

Patients with chronic gastritis, gastric ulcers, adenocarcinoma, and MALToma also included.

The studied cases of chronic gastritis were reviewed according to the recommended table by the Sydney system<sup>15</sup>.

### Histochemical and IHC Staining

All the obtained gastric biopsies were collected, placed on filter paper, fixed in 10% formalin overnight, processed, and embedded in paraffin wax. After that 4micron-thick tissue sections taken.

Once the slides prepared, *H. pylori* status analyzed by three methods: H&E, modified Giemsa stain (MGS) using 1:9 dilution (Sheehan's modified may) and immunohistochemical stains (IHC) applying a rabbit polyclonal antibody against *H. pylori* (1:160 dilution; Cell Marque, Ventana, catalog: 760-2645, Rocklin, Calif) according to the manufacturer's guidance using automated BenchMark instrument (Ventana). Antigen retrieval was performed by microwave heating in a sodium citrate buffer. An avidin-biotin detection method used with 3,3'-diaminobenzidine tetrahydrochloride visualization<sup>16</sup>.

### Scoring and Analysis of *H.pylori* Staining

All cases microscopically examined for interpretation of histochemical and immunohistochemical stains of *H pylori* infection. Each set of histologic sections calculated, and the results inscribed.

*H.pylori* categorized as either positive or negative. The presence of any stained organisms resembling *H.pylori* bacteria designated as positive. The lack of any *H. pylori* like microbe

stain assigned as negative. *H. pylori* is typically a curved rod microbe that is 2.5-4.0 microns long and 0.5-1.0 microns thick. It is observed on the lumen or epithelial surface of the gastric mucosa; the organisms are infrequently seen in within epithelial cells or gastric crypts<sup>17</sup>.

### Statistical Analysis

The Chi-square test was performed to analyze negative and positive cases as defined by H&E/MGS and IHC for pathologic hallmarks. A cut level of  $p < 0.05$  was used for separation of cases.

## RESULTS

The patients' age range was 11 to 82 years (mean of 46.5 years) most of them were in the third decade. There were 58 (58%) males and 42 (42%) females with a male to female ratio of 1.38:1, **Figure 1&2** .

The presence of *H. pylori* was significantly correlated with male sex and with young age group ( $p < 0.001$ ), as shown in **Table 1** .

Gastric biopsies were obtained from the antrum (81%) and the corpus (19 %) only. The frequency of *H. pylori* was higher in the antrum than corpus both histochemically and immunohistochemically, **Table 2** .

The histopathological findings of endoscopically obtained gastric biopsies were all illustrated in **Table 3** . Cases of gastritis were classified and graded, according to the updated Sydney system, **Table 4** .

The detection rate of *H. pylori* was different with different stains used (H&E, MGS or IHC). The bacilli were positive with H&E/MGS in 71 (71 %) of cases, increased to 75 (75 %) by IHC stain, with a degree of colonization graded into mild, moderate and marked, **Table 5 & Figure 3** . There were 8 (11 %) cases of mild colonization detected by IHC; of these 8 cases, only 4 were positive by the H&E/MGS **Figure 4&5** . On the other hand, all moderate and marked cases were positive by all stains, **Figure 3&6** . All parenchyma infected with *H. pylori* manifested variable active and chronic gastritis. With a sample of 85 chronic gastritis biopsy specimens, 63 (74%) maintained active inflammation, and 22 (26%) kept chronic inactive inflammation. The presence of *H. pylori* significantly linked with active ( $p < 0.0001$ ) and chronic ( $p < 0.0001$ ) inflammation. Among *H. pylori*

definite chronic gastritis, there was no significant difference between the infiltration of *H. pylori* in the mucosa and the degree of severity (mild, moderate, or severe). Intestinal metaplasia was present in 3(4%) cases of gastritis; one was of a severe type. Two of them were positive for Helicobacter microbe by IHC; both displayed colonization of bacteria in areas other than metaplasia. Five gastric biopsies exhibited features of peptic ulcer, *H. pylori* were positive in 3 of them. Gastric cancer (adenocarcinoma and lymphoma) detected in 10% of the cases, 50% were associated with *H. pylori* positivity. The presence of *H. pylori* significantly correlated with dysplasia and gastric cancer in spite of the small sample in this study ( $p < 0.04$ ). **Figure 7** .

The sensitivity and specificity of the H&E/MGS were measured compared with the recommended standard sensitive and specific IHC test; they were 95% and 100% respectively. Ultimately, this survey noticed a statistically significant difference between IHC and H&E/MGS ( $p= 0.04$ ) for the detection of *H. pylori*.

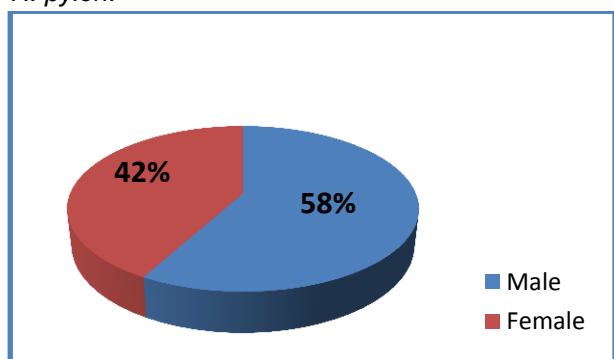


Figure 1: Sex distribution .

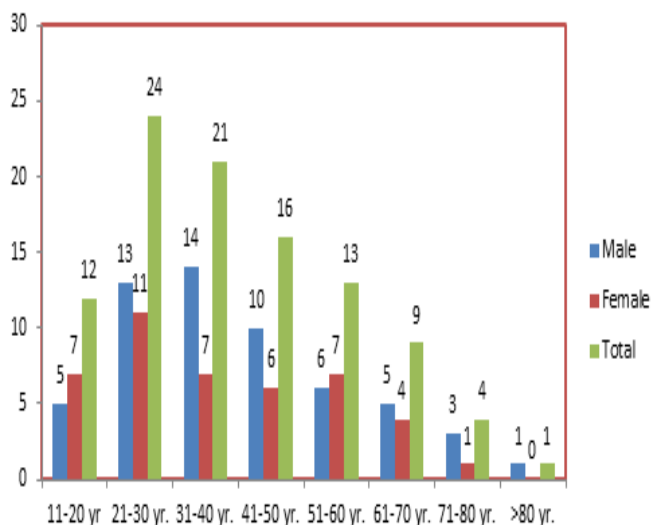


Figure 2: Age and sex distribution

Table 1: *H. pylori* density in relation to age and sex in the study group .

H pylori	Age	Age	Male	Female	Total
	≤ 40	> 40			
Positive	43	28	38	33	71
Negative	14	15	20	9	29
Total	57	43	58	42	100

$p \text{ value} < 0.01$ .

Table 2: Correlation between histochemistry and IHC for detection of *H.pylori* in relation to the location of the gastric biopsy.

<i>H. pylori</i> presence	Corpus	Antrum	Total (n=100)
	(n= 19)	(n=81)	
<b>Histochemistry</b>			
Positive	11	60	71
Negative	8	21	29
<b>IHC</b>			
Positive	12	63	75
Negative	6	19	25

Table 3: Histopathological findings of endoscopically obtained gastric biopsies.

Histopathological findings	(n)
Chronic gastritis	85
Gastric ulcer	5
Gastric cancer	10
Adenocarcinoma	7
Intestinal type	3
Diffuse type	4
Lymphoma(MALToma)	3
Total	100

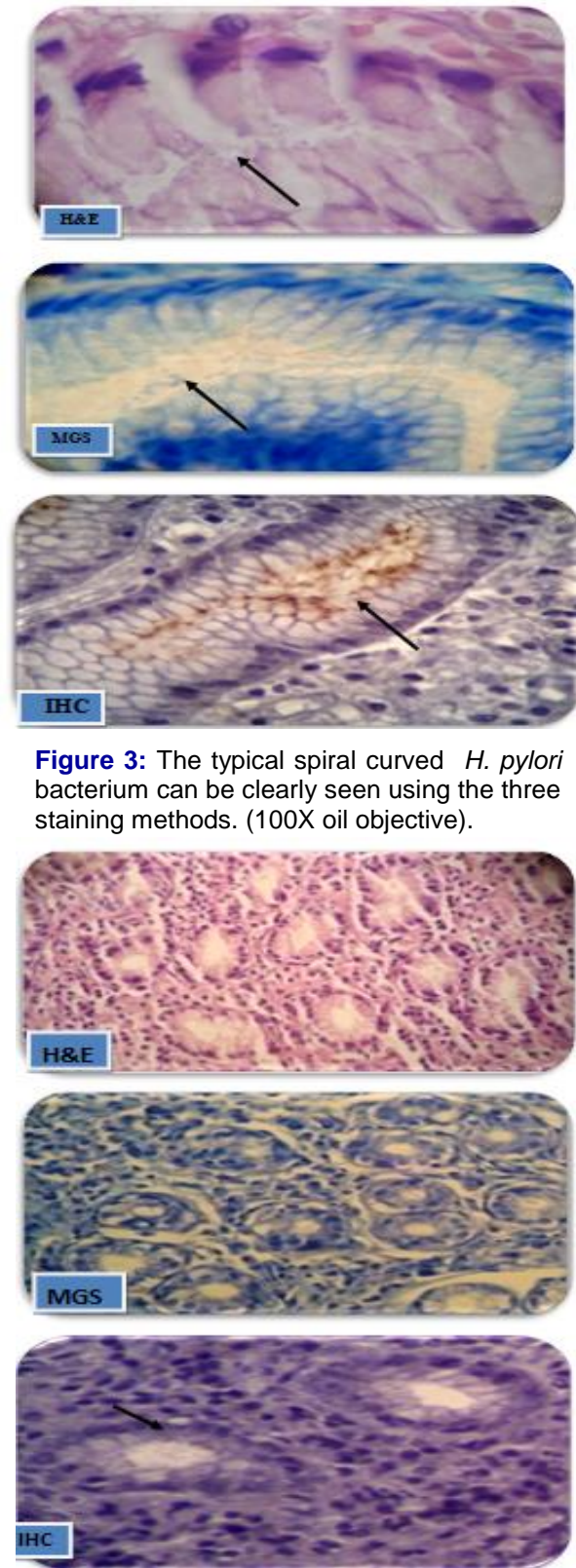
**Table 4:** *H.pylori* colonization and histological grades of gastritis by updated Sydney system.

Sydney system	<i>H pylori</i> +	<i>H pylori</i> -	Total	P value	
<b>Chronic inflammation</b>					
1	0	6	6	p<0.001	
2	38	16	54		
3	25	0	25		
<b>PMN inflammation</b>					
0	13	9	22	P<0.001	
1	7	5	12		
2	34	8	42		
3	9	0	9		
<b>Glandular atrophy</b>					
0		42	7	49	P=0.258
1		14	10	24	
2		7	2	9	
3		0	3	3	
<b>Intestinal metaplasia</b>					
0		63	19	82	P=0.08
1		0	2	2	
2		0	0	0	
3		0	1	1	

**Table 5:** *H.pylori* colonization in correlation to histochemistry and IHC

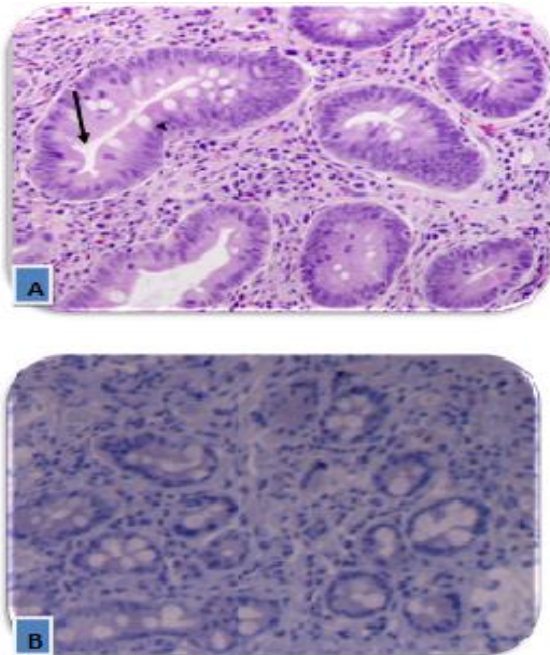
<i>H. pylori</i> colonization	H&E/MGS (n)	IHC (n)
0 None	29	25
1 Mild	4	8
2 Moderate	41	41
3 Severe	26	26
<b>Total</b>	<b>100</b>	<b>100</b>

p value= 0.04

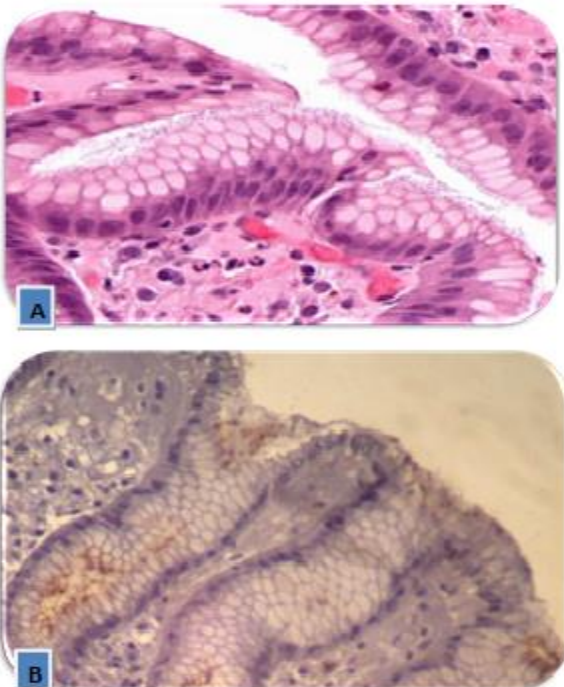


**Figure 3:** The typical spiral curved *H. pylori* bacterium can be clearly seen using the three staining methods. (100X oil objective).

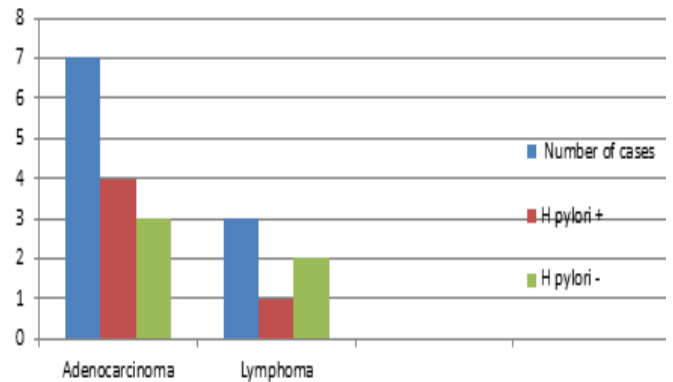
**Figure 4:** Chronic gastritis with H&E/MGS negative for *H. pylori*; however, IHC was positive for the coccoid form( arrow), (10x40HPF).



**Figure 5:** (A, arrow), chronic gastritis with intestinal metaplasia and small cylindrical structures “suspicious” for *Helicobacter pylori* seen with H&E staining; (B), however, the immunohistochemical stain was negative, (10x10HPF).



**Figure (6):** (A),Chronic active gastritis with abundant organisms on the surface; (B),confirmed by immunohistochemical staining . (10x10HPF).



**Figure 7:** Association of *H. pylori* with gastric cancer. ( p value <0.04)

### DISCUSSION

*Helicobacter pylorus* is a major human pathogen for which an accurate detection required for proper patient management<sup>18</sup>. In most cases, *H.pylori* recognized in a good hematoxylin and eosin stain. However, the sensitivity of this remains low, especially when there are no many bacteria<sup>18</sup>. None one method has sufficient sensitivity and specificity to be considered a gold standard, therefore, most laboratories use an additional staining method in the identification of the organism<sup>14, 18</sup>.

In the present study, we adopted three methods (H&E, MGS, and IHC) for *H. pylori* revealing. The mean age of sampled patients was 46.5 years, being more prevalent between 21 and 30 years. The *H. pylori* appearance significantly correlated with a young age group, a finding similar to the fact that the incidence of *H. pylori* infection is higher at a younger age in the developing world<sup>19</sup>.

This study displayed *H.pylori* infection more common in male sex which is similar to a systematic review and meta-analysis of 244 studies analyzed by Ibrahim et al<sup>20</sup>. The result of this study perhaps attributed to some male habits like smoking, alcohol drinking, and diet-related factors that might damage gastric mucosa and change the gastric internal environment.

Similar to our research, most studies confirmed the high prevalence rate of antral *H.pylori*, utilizing various identification methods<sup>5</sup>, this explained by that, in practice, most gastric biopsies obtained from the antrum.

The detection rate of *H pylori* is variable and dependent on the stain used ( H&E, special stain

or IHC). It has reported that hematoxylin-eosin stain alone can detect *H. pylori* in 66% of cases with many false positives and false negatives<sup>18</sup>.

In this study, we introduced a modified Giemsa stain (MGS) and immunohistochemistry (IHC) stain for detection of *H. pylori*. The bacilli were positive with H&E/MGS in 71 (71%) of cases this rate increased to 75% by using IHC. The sensibility and specificity of the H&E/MGS were measured compared with the recommended standard sensitive and specific IHC test; they were 95% and 100% respectively. This high sensitivity attributed to patient used during the examination of the H&E and Giemsa stained sections in addition to the use of at least 15 high power fields looking for *H. pylori* organisms, a similar finding reported in Smith et al<sup>21</sup>.

However, the false negative results in H&E/MGS explained by the fact that the mildly colonized or the singly scattered bacteria easily be lost by the H&E/MGS<sup>22</sup>. In extension to the point that many *H. pylori* organisms transformed into coccoid forms, after therapy, which may pass by the routine dyes undetected<sup>22</sup>. Those single or modified organisms were visualized obviously by IHC<sup>(22, 23)</sup>. Based on these results it is clear that immunohistochemical staining could marginally enhance the detection rate of the organisms<sup>23</sup>.

In the current research with an 85 chronic gastritis biopsy samples, the significant association between chronic active gastritis and *H. pylori* infection has been previously analyzed in many other studies<sup>24,25</sup>. Hence, the chronic active inflammation should prompt a careful search of the sections for the presence of the *H. pylori*.

Five percent of dyspeptic patients confirmed to have gastric ulcer disease in this study, three of them were positive for *H. pylori* microbe, a conclusion that similar to a study in Iran, with a percentage of 71%<sup>26</sup>.

Chronic *H. pylori* gastritis leads in more than half of the affected subjects to gastric atrophy<sup>27</sup>. In this survey, glandular atrophy present in 36 (42.4%) cases of chronic gastritis, most were of a mild degree, results similar to those reported by previous studies done in Iraq<sup>8,28</sup>. On the other hand, *H. pylori* were present in 49.5% of atrophic gastritis just comparable to those reported in Turkey and Iran, (43% and 68%) respectively<sup>29,26</sup>.

Despite some doubts, it globally believed that *H. pylori* have a fundamental role in the pathogenesis of gastric cancer<sup>30</sup>. Gastric cancer (adenocarcinoma and lymphoma) detected in 10% of the studied sample, 50% were associated with *H. pylori* similar to Taiwanese study<sup>31</sup>. The residence of Helicobacter microbe was positively associated with gastric dysplasia and cancer in spite of the small sample. However, further studies are needed to confirm the role of this microorganism in the gastric carcinogenesis in our locality.

The results of this study revealed that IHC is a highly specific and sensitive method for the identification of *H. pylori* as compared to H&E and MGS<sup>2</sup>. However, in our laboratory, *H. Pylori* almost readily viewed in the majority of cases with haematoxylin stain which comparable to a recent study suggesting that pathologists' are able to identify these bacilli regardless their training level therefore ancillary staining for *H. pylori* is not indicated in our practice<sup>32</sup>. However, in a small number of cases, an immunohistochemical stain can be particularly useful like in severe active gastritis in which no helicobacter microbes could be detected on haematoxylin stains, to avoid the false-negative results, and for the follow-up biopsies to confirm the absence of *H. pylori* regardless of the number of the organisms present or the shape it chooses<sup>2</sup>.

## CONCLUSION

The routine ancillary stains request for the detection of *H. pylori* remains a laboratory and an institution right. This study revealed, in our laboratory, a regular application of ancillary dyes for the description of *H. pylori* not obligated because it was readily recognizable in the bulk of sections with haematoxylin staining. However, we propose IHC for samples with severe chronic severe active gastritis in which *H. pylori* not distinguished by H&E dyes, post-treatment biopsy samples, and when particles "suspicious" but not conclusive for *H. pylori* viewed on haematoxylin stains.

## REFERENCES

1. Sarma A, Hazarika BB, Patgiri SJ, et al. Isolation of *Helicobacter pylori* from Gastric Biopsy Specimens and Evaluation of Common Contaminants Associated with H. Pylori Cultures. *Int J Med Res Prof.* 2016; 2; 161-4.
2. Mégraud F and Lehours P. *Helicobacter pylori* Detection and Antimicrobial Susceptibility Testing. *Clin. Microbiol. Rev.* 2007; 20: 280-322.
3. Amieva MR, El-Omar EM. Host-bacterial interactions in *Helicobacter pylori* infection. *Gastroenterol.* 2008;134(1):306–23.
4. Horvitz G and Gold BD. Gastroduodenal diseases of childhood. *Curr. Opin. Gastroenterol,* 2006; 22:632-40.
5. Kusters J, van Vliet A, Kuipers E, et al. Pathogenesis of *Helicobacter pylori* infection. *Clin. Microbiol. Rev.* 2006; 19:449-90.
6. Valle K, Kekki E, Sipponen R, et al. Long-term course and consequences of *Helicobacter pylori* gastritis. Results of a 32-year follow-up study. *Scand. J. Gastroenterol.* 1996; 31: 546-50.
7. Kosunen TU, Aromaa A, Knekt P, et al. *Helicobacter* antibodies in 1973 and 1994 in the adult population of Vammala, Finland. *Epidemiol. Infect.* 1997; 119:29-34.
8. Hussein NF, Napaki SM, Atherton JC, et al. A Study of *Helicobacter pylori*-associated Gastritis Patterns in Iraq and Their Association with Strain Virulence. *Saudi J Gastro.* 2009; 15: 125-7
9. Lochhead P and El-Omar E. *Helicobacter pylori* infection and gastric cancer. *Baillieres Best Pract. Res. Clin. Gastroenterol.* 2007; 21:281-97.
10. Rugge MP, Correa M, Dixon F, et al. Gastric mucosal atrophy: interobserver consistency using new criteria for classification and grading. *Aliment. Pharmacol. Ther.* 2005; 16:1249-59.
11. Asaka M, Kato M, Graham DY, et al. Prevention of Gastric Cancer by *Helicobacter pylori* Eradication. *Inter Med.* 2010; 49: 633-6.
12. Lee JU and Kim N. Diagnosis of *Helicobacter pylori* by invasive test: histology. *Ann Transl Med.* 2015;3: 1-10.
13. Wong BC, Lam SK, Wong WM, et al. *Helicobacter pylori* eradication to prevent gastric cancer in a high-risk region of China: a randomized controlled trial. *JAMA* 2004; 291:187-94.
14. Patnayak R, Reddy V, Jena A, et al. Utility of immunohistochemistry in demonstrating *Helicobacter pylori*. *Onc Gas Hep Rep.* 2015;4:4-7
15. Dixon MF, Genta RM, Yardley JH, et al. Classification and grading of gastritis. The updated Sydney system. *Am J Surg Pathol* 1996;20:1161–81.
16. Guesdon J, Ternynck T, Avrameas S, et al. The use of avidin-biotin interaction in immunoenzymatic techniques. *J Histochem Cytochem.* 1979; 27:1131-9.
17. Riba AK, Ingeneri TJ, Strand CL, et al. Improved Histologic Identification of *Helicobacter pylori* by Immunohistochemistry Using a New Novocastra Monoclonal Antibody. *Laboratory Medicine.* 2011;42:35-9.
18. El-Zimaity H, Graham D, Al-Assi M, et al. Interobserver variation in the histopathological assessment of *Helicobacter pylori* gastritis. *Hum Pathol.* 1996; 27:35–41.
19. Khalifa MM, Sharaf RR, Aziz RK, et al. *Helicobacter pylori*: a poor man's gut pathogen? *Gut Pathogens.* 2010;2:2.
20. Ibrahim A, Morais S, Ferro A, et al. Sex-differences in the prevalence of *Helicobacter pylori* infection in pediatric and adult populations: Systematic review and meta-analysis of 244 studies. *Dig Liver Dis.* 2017; 49(7):742-9
21. Smith SB, Snow AN, Perry RL, et al. *Helicobacter pylori* To Stain or Not to Stain? *Am J Clin Pathol.* 2012;137:733-8.
22. Marzio L, Angelucci D, Grossi L, et al. Anti-*Helicobacter pylori* specific antibody immunohistochemistry improves the diagnostic accuracy of *Helicobacter pylori* in biopsy specimen from patients treated with triple therapy. *Am J Gastroenterol.* 1998;93:223–6
23. Ayoola AE, Ageely HM, Gadour MO, et al. Prevalence of *Helicobacter pylori* infection among patients with dyspepsia in South-Western Saudi Arabia. *Saudi Med J* 2004; 25: 1433-8
24. Pranjal Sharma R, Kalpana Kumari MK. Histological identification of *Helicobacter pylori*: comparison of staining methods. *Int J Med Res Rev.* 2015;3(10):1167-73
25. Gunaid A, Hassan N, Murray-Lyon I, et al. Prevalence and risk factors for *Helicobacter pylori* infection among Yemeni dyspeptic patients. *Saudi Med J* 2003; 24: 512-7



26. Hashemi M.R, Rahnavardi M, Bikdeli B, et al. *H pylori* infection among 1000 southern Iranian dyspeptic patients. World J Gastroenterol. 2006; 34: 5479-82
27. Zhang C, Yamada N, Wu YL, et al. *Helicobacter pylori* infection, glandular atrophy and intestinal metaplasia in superficial gastritis, gastric erosion, erosive gastritis, gastric ulcer and early gastric cancer. World J Gastroenterol. 2005;11(6):791–6.
28. Ahmed A M. Histopathological evaluation of chronic gastritis in Duhok region according to the updated Sydney system. A thesis submitted to the scientific council of pathology in partial fulfillment of the requirement for the degree of fellowship in the Iraqi board for medical specialization in pathology,2010.
29. Fikret D, Kaya Ö, Suna E, et al. Relationship between atrophic gastritis, intestinal metaplasia, dysplasia and *Helicobacter pylori* infection. Turkish J Gastroenterol. 2001;12:169-72
30. Singh K, Ghoshal UC. Causal role of *Helicobacter pylori* infection in gastric cancer: an Asian enigma. World J Gastroenterol. 2006; 12: 1346-51
31. Wu MS, Shun CT, Lee WC, et al. Gastric cancer risk in relation to *Helicobacter pylori* infection and subtypes of intestinal metaplasia. Br J Cancer. 1998;78(1): 125-8
32. Richard H and Robert M. Routine Anti-*Helicobacter* Immunohistochemical Staining is Significantly Superior to Reflex Staining Protocols for the Detection of *Helicobacter* in Gastric Biopsy Specimens. *Helicobacter*. 2016; 21,581-5.