

Stability, Mobility and Pull out Forces of Immediate Loaded Endosteal Screw Type Dental Implants of 4 and 4.5mm in Diameter (Comparative Experimental Study)

Luay N Abood

BDS, MSc. (Assist lect)

Munther N Kazanji

BDS, MSc (Assist Prof)

Mumammed J. Essa

BDS, MSc, Phd (Assist Prof)

Department of Prosthetic Dentistry

College of Dentistry, University of Mosul

Department of Prosthetic Dentistry

College of Dentistry, University of Mosul

Department of Surgery

College of Veterinary, University of Mosul

ABSTRACT

Aims: To compare the immediate loaded implants with the non-loaded type by pull-out force test measured with aids of semiautomatic strength tester machine and mobility test using orthodontic gauge and digital vernier. **Materials and Methods:** Twenty implants (Denti Dental implant system Ltd. Hungary) of screw type 10mm length with 4, and 4.5mm diameter were inserted in the mandible of 5 local breed dogs. Four implants for each animal, 2 of them were immediately loaded two days after surgery with Nickel Chrome crowns. Primary implant stability measured at the base line time, pull-out force test and mobility test done after three months of healing process. One-way analysis of variance with Duncan multiple range test were used for statistical analysis. **Results:** Revealed that there was no significant difference between the immediate loading and control group for the 4.5mm implant diameter, with significant difference for the 4mm diameter implant. No effect of time on the mobility of implant between the initial stability and final mobility of implants. The success rate of immediate loaded implants was 75% when compared to 100% success rate of non-loaded type. **Conclusion:** the immediate loading of screw type single-tooth implant of 4.5 mm diameter, 10mm length do not jeopardize tissue integration and osseointegration occurred properly as it is in the non-loaded delayed loaded type implants.

Key words: Mobility, Pull out Force, Immediate Loaded, Dental Implants.

Kazanji MN, Essa MJ, Abood LN. Stability, Mobility and Pull out Forces of Immediate Loaded Endosteal Screw Type Dental Implants of 4 and 4.5mm in Diameter (Comparative Experimental Study). *Al-Rafidain Dent J.* 2006; 6(Sp Iss): 133S-141S.

Received: 28/7/2005

Accepted for Publication: 31/10/2005

INTRODUCTION

The ultimate goal of an immediate loading protocol is to predictably reduce surgical interventions and to shorten the time frame between surgery and prosthesis completion. This will ultimately lessen patient's reservations and increase acceptance of implant therapy⁽¹⁾, Although immediate loading protocol still needs to be validated with significant number of clinical cases, extended follow up prior to be as a part of routine treatment as an implant therapy.

The interest in immediate dental implant loading first arose when Gapski *et al.*,⁽²⁾ introduced this modality with edentulous mandibles. Encouraging initial results shown for splinted restorations.⁽³⁻⁶⁾ In an

animal study, Corso *et al.*,⁽⁷⁾ investigated the effect of immediate loading of single standing dental implants with different surfaces. They reported good results, provided that the implant has an excellent primary stability, showed that unsplinted implants could be loaded immediately in single crown restorations of the edentulous mandible. Primary implant stability is a fundamental factor in obtaining osseointegration for immediate implant loading.⁽⁸⁻¹⁰⁾ The bone-implant interface should have no micromotion more than 150 µm to ensure osseointegration.⁽¹¹⁾ Primary stability estimated also by depending on bone mineral density measured with dental quantitative computed tomography.⁽¹²⁾ The surgical pl-

acement of implant must be delicate procedures, atraumatic.^(13,14)

Implant length and diameter also influences the outcome of immediate loading. The majority of studies have suggested that the implant should be $\geq 10\text{mm}$ long to ensure high success rate.⁽¹⁵⁻¹⁷⁾

Studies showed that the implant diameter was effective in stress distribution of masticatory force in immediate loading implant.^(18,19)

Optimum success of immediate loading implant obtained when large diameter implant used if the edentulous region offers enough bone space.⁽²⁰⁾ Controlling of functional forces is a dramatic criteria since early loading may interface with the ability of new bone formation, this is accomplished by decreasing the occlusal table to decrease the force of occlusion.⁽²¹⁾ The implant were to be successful if the following conditions met at the time of evaluation⁽²²⁾ :

- (1) No clinically detectable mobility when tested with an opposing instrument pressure.
- (2) No evidence of peri-implant radiolucency.
- (3) No recurrent or persistent peri-implant infection.
- (4) No complaint of neuropathies or parasthesia.
- (5) No crestal bone loss exceeding 1.5mm by the end of the first year of functional loading and no bone loss exceeding 0.2mm/year in subsequent years.⁽²³⁾

The purpose of present experimental study is to compare the immediate loaded with non loaded single-tooth implant regarding the effect of implant diameter on pull-out force and mobility of immediate loading protocol.

MATERIALS AND METHODS

Five adult local breed dogs weighting 15-22 Kg from both sexes were selected in the study, the animals were kept under the same condition of feeding and housing in standard separated cages. The dogs received antihelminthic drugs (Piprazine Citrate and Ivermectin) to control the external and internal parasites. Periapical radiographs were taken to the left side of mandible to evaluate the root length and morphology and to determine any pathological lesion which may occur, radiographic machine head made perpendicular to both mandible and film with 16 inch head to object distance and the X-ray film were exposed

to 90 kV and 7.5 mAs.

Initial measurements of the dimension of jaws were registered under general anesthesia by a heavy body rubber base impression molded manually over each jaw to obtain an impression for the upper and lower jaws accurately and special trays were made. One hour Prior to each surgical procedure, animals oral cavity was irrigated by 2% Chlorohexidine mouth wash and systemic administrations of antibiotics using Procaine Penicillin and Streptomycin intramuscularly at a dose of 10,000 IU, 10 mg/kg body weight respectively as cover to subside the infection. In addition to that analgesic as Dipyrone given for 3-4 days at dose of 1500mg intramuscularly once daily after operation.

All surgical procedures, mobility measurements and radiographic examinations were done under general anesthesia by using Atropine Sulfate at a dose of 0.04 mg/kg body weight intramuscularly as a premedication to reduce salivary and mucous secretion. Followed 10 minutes later by a mixture of Ketamine Hydrochloride 5% and Xylazine 2%, at a dose 15,5 mg/kg respectively intramuscularly. Teeth were extracted by hemisection with profuse irrigation. Then flap suturing done. After two months of extraction procedure, another radiographs were taken for checking bone healing which occurred by bone mineralization with a complete trabecular bone formation (Figure 1).

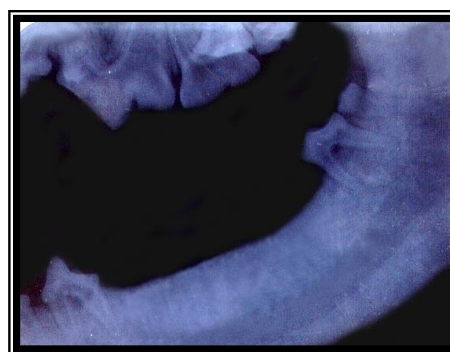


Figure (1): Radiographic view of the lower jaw showing bone healing two months post extraction period.

Two months later second impression (Figure 2) was taken by regular body rubber base impression material using special tray for the construction of study model af-

ter two months of teeth extraction and to make the surgical template.

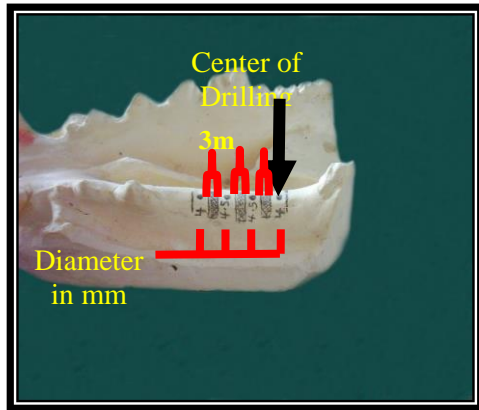


Figure (2): Implants site planed over master cast with 3mm distance.

Twenty dental implants of one-stage surgery made of pure unalloyed Titanium (Denti Dental implant system Ltd. Hungary) were used in this study, each dog received four implants of two different diameter (4, and 4.5mm) two months post extraction period, with standard length of 10mm, the anterior two implants were the control groups while the posterior two implants were the experimental groups. The surgical instillation have been done under a traumatic sterile condition by the use of high torque hand-piece at a speed of 1500 rpm with copious external irrigating system, a mid crestal incision along the healed extra-

ction site was done then muco-periosteal flap reflected both buccaly and lingually.

Implant osteotomy site were prepared with a distance of 3mm between two individual implants (Figure 3) by the aid of surgical template (prepared by Biostar vacuums machine) before the operation with standard instrument of Dental implant system, the implant bed were sequentially enlarged to 4 and 4.5mm, respectively starting with 2, 3.5mm pilot drill, to optimize the primary stability, The preparation of final drill was only performed in the crestal 3mm of the mandible to allow the compression of central sponges bone by the implant.

The implant then placed in its site until the end of screw reach the crestal bone of mandible and the top collar smooth surface extended 4 mm above the crestal bone with peak insertion torque $\geq 35\text{N/m}^2$, then the flap repositioned and sutured. Final impression was taken by regular body rubber base impression material immediately by indirect closed technique. The upper and lower casts were mounted on articulator (Figure 3, c) at centric occlusion by direct manual occlusion. Nickel Chrome crowns were constructed and fixed on the abutments (Figure 3, d) by means of self-cure composite resin after 48 hours of implant installation and occlusal adjustment was done to eliminate any occlusal contacts.

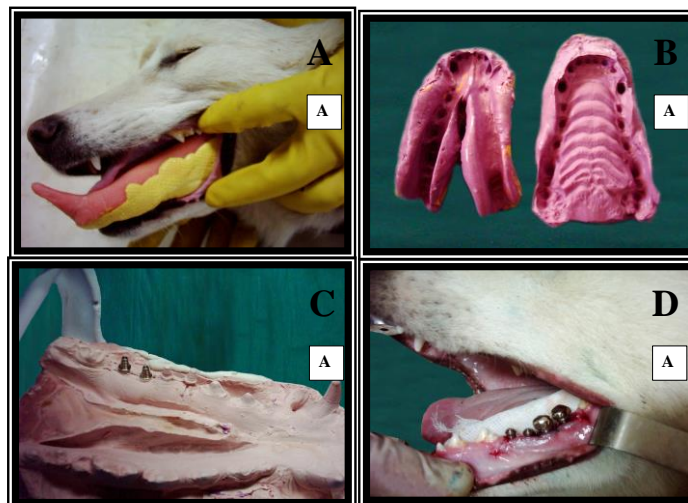


Figure (3): Steps of impression and crowns insertion: A, Special tray with impression material; B, Secondary impression; C, Laboratory analogues; D, Nickel Chrome crowns.

Postoperatively during first two weeks, plaque controls was performed by rinsing the mouth of animal daily by 0.2% Chlorohexidine Digluconate. Later was continued by brushing the teeth with soft brush and 0.2% Chlorohexidine gel 3–4 times a week and dogs feeding maintained by soft diet through the whole period of study to minimize the functional loading of implant. Radiographic examination were done at 1, 2, 3 months subsequently after crown insertion (Figure 4).

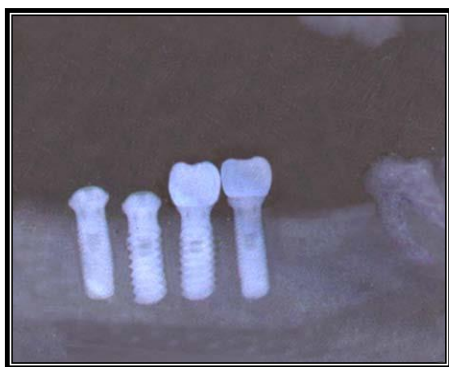


Figure (4): Radiographic X-ray film of the implants with the abutments after 3 months of implants placement

Mobility test was done at time of implants placement and after three months by the aids of Digital vernier which have the ability of measuring up to 0.001mm, the vernier was carried by a rigid holder to be steady, the rod of the vernier adjusted on the top of implant this is for the control group and at the implant abutment junction for experimental group, at the other side of implant an orthodontic stress gauge was applied at a pressure of 1 pound that repeated in all stage of measurement, a special wooden device were constructed to fix the head of the dog snugly while the mandible is fixed on the wooden table by fixation screws applied on the teeth from above and wooden table from below.

Bone resection accomplished with the preservation of inferior border of mandible and the animals were not sacrificed due to ethical reasons Then sectioning the bone approximately 1.5mm mesial and distal to each implant fixture by bone saw. The implant from each group was placed in normal saline with numbering to be prepared for mechanical test. The bone-implant blocks were prepared for semiautomatic pull-

out testing machine by immersing them in a blocks of self-cured acrylic with dimensions similar to that of machine vise.

A stainless-steel metal plate of 1.5mm thickness with a hole just large enough for the middle portion of the pulling fixture to tightly slip through, a bone-implant block was placed beneath the metal plate and secured in the machine vise (Figure 5).




Figure (5): A bone-implant with acrylic resin block placed beneath the metal plate and secured in the machine

The implant fixture pulled-out by aids of clamp fixed to the opposing machine vise, this clamp contains a small hole at the cutting ends enough to engage the implant neck. The semiautomatic pull-out machine with measurement accuracy of 0.1 Kgms measure the force needed to pull-out the implant from its surrounding bone with cross-head speed 2mm/min. the ultimate interfacial strength calculated by multiplying the obtained magnitude in Kg by 9.8.

The statistical analysis included One-way analysis of variance with Duncan multiple range test, Person correlation coefficient, and Student *t*-test for assessment of the significance of the difference between two means when *P*-value ≤ 0.05 .

RESULTS

At the follow up examination three months after implant instillation, all restorations and implants were still in service, with slight abrasion at the occlusal surface. Except two of implants were failed and excluded from the study which is due to technical reasons.

Effect of Load and Diameter on Pull-Out Force Magnitude: Student *t*-test showed

no significant difference between immediate loaded implants of (4.5mm) with the control type, while there was significant difference between the immediate loaded

and control groups of (4mm) diameter and also significant difference between the immediate loaded type of (4mm) and (4.5mm) diameter implants (Table 1).

Table (1): Effect of load and diameter respectively: student t-test analysis between immediate and delayed loading with 4mm and 4.5mm diameter.

Effect of Load	Mean ± SD	DF	T-value	P-value
Experimental 4.5mm	305.87±59.4	8	0.33	Not Significant
control 4.5mm	318.97±66.0			
Experimental 4mm	139.27±97.1	6	2.17	Significant
control 4mm	248.17±49.0			
Total experimental	243.37±110.2	16	0.96	Not Significant
total control	283.57±66.3			
Effect of Diameter	Mean ± SD	DF	T-value	P-value
Experimental 4.5mm	305.87±59.4	6	3.08	Significant
experimental 4 mm	139.27±97.1			
Control 4.5mm	318.97±66.0	8	1.92	Not Significant
control 4mm	248.17±49.0			
Total 4.5mm diameter	312.37±59.6	16	3.08	Significant

SD: Standard deviation; DF: Degree of freedom.

Effect of the Load and Diameter on Mobility: One way analysis of variance for experimental and control type implant with different diameter at time of implant placement and after three months showed signifi-

cant difference between the tested groups Duncan multiple range tests showed that the causative group is the experimental 4mm diameter implants after three months of implant instillation (Table 2).

Table (2) Mean, standard deviation of primary implant stability and mobility after three months for each tested group with Duncan multiple

Level	Number	Mean ± SD (µm)	Duncan grouping
Control 4 B	5	22±1.48	A
Control 4.5 B	5	14±0.89	A
Experimental 4 B	3	23±2.08	A
Experimental 4.5 B	5	18±0.84	A
Control 4 T	5	16±0.55	A
Control 4.5 T	5	20±0.71	A
Experimental 4 T	3	666±57.74	B
Experimental 4.5 T	5	26±1.52	A

B: Base line (time of implant insertion); T: Three months post implant insertion; Different letters mean significant difference.

Correlation Between Pull-Out Force and 3rd Month Implant Mobility Test: Parson correlation coefficient between pull-out force that needed for implant failure, and

the mobility after osseointegration (three months post instillation) is inversely proportional shown in Figure (6).

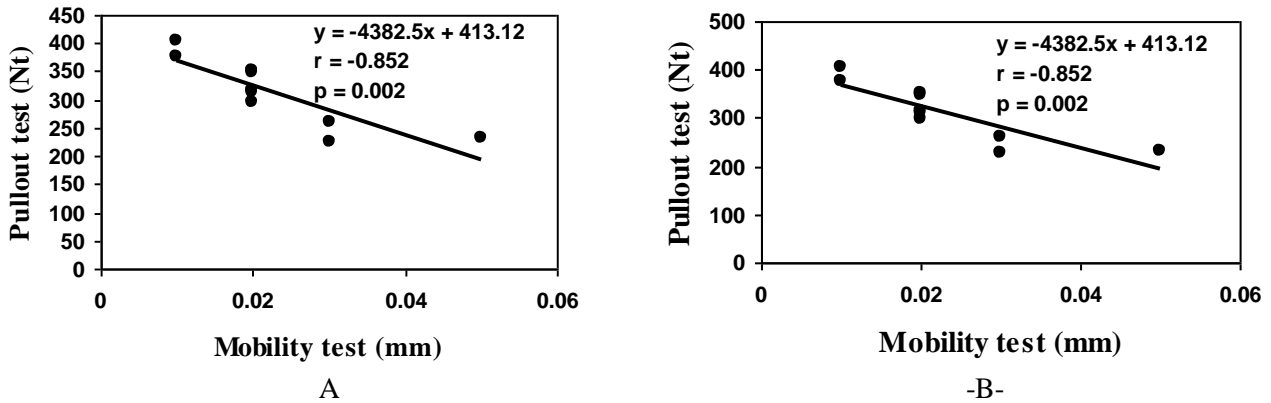


Figure (6): A: Correlation coefficient for 4.5 mm diameter implant group; B: Correlation coefficient for 4 mm diameter implant which are significant –ve correlation between mobility and pull-out force. (Y: Pull-out; X: Mobility; r: Correlation coefficient; p: Probability value)

Implant Success and Failure: According to the success criteria of Smith and Zarb⁽²⁴⁾ (Table 3), showed high success rate for the immediate loaded implant of large diameter (4.5mm) compared to the same diameter

of non-loaded group, while small diameter type showed a low success rate when compared to the non-loaded type with the same diameter.

Table (3) The success criteria of the tested implants according to smith and zarb.⁽³⁾

Implant group	Number	Peri-implant radiolucency	M	% success rate
Experimental 4 mm	3	2 implants +ve	2 implants ve	33%
Experimental 4.5mm	5	–ve	–ve	100%
Control 4mm	5	–ve	–ve	100%
Control 4.5mm	5	–ve	–ve	100%

N: Number of implant samples; M: Clinically detectable mobility of implant; –Ve: Absence of the above conditions; +Ve: Presence of the above conditions.

DISCUSSION

Immediate loading, implants are successful when compared to delayed type loaded implant procedure. This result was in agreement with the result of other studies.^(25–28) Other study showed that the immediate loading of interforaminal mandibular implants demonstrated a highly acceptable clinical success with an intimate bone contact when compared to the non-loaded implants.⁽²⁹⁾

The result of this study showed that immediate loading implant protocol with 4mm diameter gives a significant difference with lower pull-out force when compared with delayed loaded implant. This mean that small diameter implant is unsuitable to be used for the immediate loading,

due to the small size area distribution of biomechanical forces that exerts in implant during osseointegration period.

This result was reaffirmed by Siddiqui *et al.*,⁽³⁰⁾ while Testori *et al.*,⁽²²⁾ disagree with this result and they demonstrated with multiple implant placement that with a diameter of 3.75mm was preferred because it offers more flexibility and less invasion, depending on the density of bone and by increase the number of installed implants to distribute the exerted occlusal force.

This study evaluated the primary stability effectiveness for immediate loading protocol, which should be less than 150 μm, when implant movement exceed this critical value. It will lead to fibrous repair at the bone-implant interface rather than

osseous regeneration. This was reaffirmed by Brunski⁽³¹⁾, and Szmukler-moncler *et al.*^(11,32)

Large diameter implants ($\geq 4.5\text{mm}$) are recommended due to the reduction in the mobility because of the increasing in surface area of bone strain distribution and achieving earlier bone integration, which agree with other studies.^(33–36)

The negative significant correlation between implant stability with pull-out force is a guide for making knowledge about the prognosis of implant success for the whole study. This result agrees with Horiuchi *et al.*,⁽¹⁵⁾ which found that the failing implants often have a reduced stability compared with the successful implants at time of implant placement. As a criterion for immediate loading, the placement torque has been considered to correlation with a sufficient primary stability, this type of correlation is true at the time of implant installation and at the end of study.

CONCLUSION

Immediate loading of single-tooth implant is a successful way when compared to the non-loaded type. Diameter of implant fixture for immediately loaded protocol better to be ($\geq 4.5\text{mm}$) to obtained a wide surface area for the distribution of occlusal force.

Primary implant stability is a crucial factor for the immediate loading implant, which should be less than $150\mu\text{m}$ to avoid fibrous repair at bone implant interface rather than the osseous regeneration. Increase of pull-out force magnitude give an impression for the degree of implant stability and success mode.

REFERENCES

1. Lozada JL, Tsukamoto N, Farnos A, Kan J, Rungcharassaeng K. Scientific rationale for the surgical and prosthodontic protocol for immediately loaded root-form implants in the completely edentulous patient. *J Oral Implantol.* 2000; 26: 51–58.
2. Gapski R, Wang H L, Mascarenhas P, Lang NP. Critical review of the immediate implant loading. *Clin Oral Impl Res* 2003; 14: 515–527.
3. Schnitman PA, Wohrle PS, Rubenstein JE. Immediate fixed interim prosthesis supported by two-stage threaded implants: Methodology and results. *J Oral Implantol.* 1990; 2: 96–105.
4. Tarnow DP, Emtiaz S, Classi A. Immediate loading of threaded implants at stage I surgery in edentulous arches: ten consecutive case report with I- to 5 year data. *Int J Oral Maxillofac Implants.* 1997; 12: 319–324
5. Randow K, Ericsson I, Nilner K, Petersson A, Glantz PO. Immediate functional loading of Branemark dental implants: An 18-month clinical follow-up study. *Clin Oral Impl Res* 1999; 10: 8–15.
6. Gatti C, Haeffliger W, Chiapasco M. Implant related mandibular overdenture with immediate loading: A prospective study of ITI implants. *Int J Oral Maxillofac Implant* 2000; 15: 383–388.
7. Corso M, Sirota C, Fiorellini J, Rasool F, Szmukler-Moncler S, Weber H. Clinical and radiographic evaluation of early loaded free-standing dental implants with various coatings in beagle dogs. *J Prosthet Dent.* 1999; 82:428–435.
8. Saadoun A, Andre P. Immediate loading : Prospectives. *Implant Dent.* 2002; 11(4): 318–322.
9. Balshi TJ, Wolfinger GJ. Immediate loading of dental implants in the edentulous maxilla: case study of a unique protocol. *Int J Periodont Restor Dent.* 2003; 23: 37–45.
10. Nkenke E, Lehner B, Weinzier K, Thams U, Neugebauer J, Stevling H, Radespiel-Troger M, Neukam FW. Bone contact, growth, and density around immediately loaded implants in the mandible of mini pigs. *Clin Oral Impl Res.* 2003; 14:312–321.
11. Szmukler-Moncler S, Salama H, Reingewirtz Y, Dubruille JH. Timing of loading and effect of micromotion on bone-dental implant interface: review of experimental literature. *J Biomed Mater Res.* 1998 43: 192–203.
12. Beer A, Gahleitner A, Holm A, Tschabitscher M, Homolka P. Correlation of insertion torques with bone mineral density from dental quantitative CT in the mandible. *Clin Oral Impl Res.* 2002; 13: 616–620.
13. Ericsson I, Randow K, Nilner K, Peterson A. Early functional loading of branemark dental implant: 5-year clinical follow-up study. *Clin Oral Impl Res.* 2000; 11: 70–77.

14. Saadoun A, Sebbag P. Immediate loading of implants with removable or fixed restorations. *Int J Magaz Oral Implantol.* 2003; 2: 14–26.
15. Horiuchi K, Uchida H, Yamamoto K and Sugimura M Immediate loading of Branemark system implants following placement in edentulous patients: A clinical report. *Int J Oral Maxillofac Implant.* 2000; 15: 824–830.
16. Klokkevold PR, Johnson P, Dadgostari S, Caputo A, Davies JE, Nishimura RD. Early endosseous integration enhanced by dual acid etching of titanium: A torque removal study in the rabbit. *Clin Oral Impl Res.* 2001; 12: 350–57.
17. Bernard JP, Szmukler–Muoncler S, Pessotto S, Vazquez L, Belser UC. The anchorage of Branemark and ITI implants of different length. I. An experimental study in the canine mandible. *Clin Oral Impl Res.* 2003; 14: 593–600.
18. Iplikcioglu H, Akca K. Comparative evaluation of the effect of diameter, length and number of implants supporting three–unit fixed partial prostheses on stress distribution in the bone. *J Dent.* 2002; 30: 41–46.
19. Himmlova L, Dostalova T, Kacovsky A, Konvickova S. Influence of implant length and diameter on stress distribution: A finite element analysis. *J Prosthet Dent.* 2004; 91:20–25.
20. Nkenke E, Lehner B, Weinzier K, Thams U, Neugebauer J, Stevling H, Radespiel–Troger M, Neukam FW. Bone contact, growth, and density around immediately loaded implants in the mandible of mini pigs. *Clin Oral Impl Res.* 2003; 14,312–321.
21. Albrektsson T, Branemark PI, Hansson HA, Lindstrom J. osseointegrated titanium implants. Requirements for ensuring a long lasting direct bone to implant anchorage in man. *Acta Orthop Scand.* 1981; 52: 155–170.
22. Testori T, Szmunkler–Moncler S, Francetti L, Del Fabbro M, Trisi P, Weinstein RI. Healing of osseotite implants under submerged and immediate loading conditions in a single patient: A case report and interface analysis after 2 months. *Int J Periodont Restor Dent.* 2002; 22(4): 345–353.
23. Albrektsson T, Zarb G, Worthington P, Eriksson AR. The long term efficacy of currently used dental implant: A review and proposed criteria of success. *Int J Oral Maxillofac Implants.* 1986; 1: 11–25.
24. Smith D, Zarb G. Criteria for success of osseointegrated endosseous implants. *J Prosthet Dent.* 1988; 62: 567–572.
25. Jo YH, Hobo PK, Hobo S. Freestanding and multiunit immediate loading of the expandable implant: An up–to–40–month postoperative survival study. *J Prosthet Dent.* 2001; 85: 148–155.
26. Rungcharassaeng K, Lozada JL, Kan JY, Kim JS, Campagni WV, Munoz CA. Peri–implant tissue response of immediately loaded, threaded, hydroxyapatite–coated implants: 1–year results. *J Prosthet Dent.* 2002; 87: 173–181.
27. Wolfinger GJ, Balshi TJ, Rangert B. Immediate functional loading of Branemark system implants in edentulous mandibles: Clinical report of the results of developmental and simplified protocols. *Int J Oral Maxillofac Implants.* 2003 18: 250–257.
28. Winter W, Heckmann SM, Weber HP. A time–dependent healing function for immediate loaded implants. *J Biomech.* 2004; 23: 1–7.
29. Lorenzoni M, Pertl C, Zhang K, Wegscheider WA. In patient comparison of immediately loaded and non–loaded implants within 6 months. *Clin Oral Impl Res.* 2003; 14: 273–279.
30. Siddiqui AA, Ismail JY, Kukunas S. Immediate loading of dental implants in the edentulous mandible: A preliminary case report from an international prospective multicenter study. *Compendium.* 2001; 22(10): 1–10.
31. Brunski JP. Biomechanical factors affecting the bone–dental implant interface. *Clin Mater.* 1992; 10(3): 153–201.
32. Szmukler–Moncler S, Salama H, Reingewirtz Y, Dubruille JH. Timing of loading and effect of micromotion on bone–dental implant interface: review of experimental literature. *J Biomed Mater Res.* 1998; 43: 192–203.
33. Chiapasco M, Gatti C, Rossi E, Haefliger W, Markwalder TH. Implant–retained mandibular overdentures with immediate loading. A retrospective multicenter study on 226 consecutive cases. *Clin Oral Implant Res.* 1997; 8: 537–546.
34. Austerl S. The influence of implant length and diameter on the bone strain finite el-

- ement analysis. *Aust J Prosth Dent.* 2002; 4: 43–50.
35. Juan CI, Ziad NJ. Immediate loading of osseotite implants: two–year results. *Implant Dent.* 2002; 11: 123–134.
36. Barone A, Covani U, Gherlone E. Radiographic bone density around immediately loaded oral implants: A case series. *Clin Oral Impl Res.* 2003; 14: 610–615.