

The effect of pisang ambon (*Musa paradisiaca* L.) stem extract on the regulation of IL-1 β , IL-6 and TNF- α in rats' enteritis

R. Kurnijasanti^{1*} and M. Candrarisna²

¹Laboratory of Pharmacology, Faculty of Veterinary Medicine, Universitas Airlangga, ²Laboratory of Pharmacology, Faculty of Veterinary Medicine, Wijaya Kusuma University, Surabaya, Indonesia

*Corresponding email: santisam19@yahoo.co.id

(Received June 13, 2018; Accepted July 15, 2018)

Abstract

Considering that NSAIDs are widely used in medication for pain, inflammatory, and fever, its side effect, mucosal erosion, needs to be minimized. The purpose of this paper is to study the potential use of *Musa paradisiaca* L. stem extract in lowering TNF α , IL-1 β and IL-6 proinflammatory cytokines in rats' enteritis. Thirty male wistar strain rats (*Rattus Norvegicus*) aged 2-3 months were divided into 5 groups with 6 repetitions. The positive and negative control groups were given a solvent of *Musa paradisiaca* L. stem extract. Groups P1, P2, and P3 were treated with the extract. The groups were treated for 14 days. On the 8th day, all of the rats were administered with Indomethacin as enteritis inducer, except for the rats in the negative control group which were only administered with indomethacin solvent. On the 15th day, the rats were necropsied, and their jejunum were taken in order to make the immunohistochemistry (IHC) preparations. The IHC test results were statistically analyzed using ANOVA and then continued with the Duncan test. The results showed that the granting of *Musa paradisiaca* L. stem extract has anti-inflammatory activity against the inflamed jejunum tissue. The anti-inflammatory activity against the damage of jejunum tissue was indicated by an attenuated expression of IL-1 β , IL-6 and TNF- α proinflammatory cytokines in the jejunum. The increasing dose showed more significant effects.

Keywords: Enteritis, IL-1 β , IL-6, TNF- α , *Musa paradisiaca* L

Available online at <http://www.vetmedmosul.com>

تأثير مستخلصات Pisang Ambon (*Musa paradisiaca* L.) على تنظيم IL-6 و IL-1 β و TNF- α في التهاب الأمعاء لدى الفئران

روجمان كيرنجاسنتي¹ و ميرانتى كندراسانا²

¹مختبر الادوية، كلية الطب البيطري، جامعة ايرلنكا، ²مختبر الادوية كلية الطب البيطري وجيا كوسوما، جامعة صرابايا، إندونيسيا

الخلاصة

بالنظر إلى أن مضادات الالتهاب غير الستيروئيدية تستخدم على نطاق واسع في علاج الألم، والتهابات، والحمى، فإن تأثيرها الجانبي، تآكل الغشاء المخاطي، لذلك يتوجب تقليل تأثيراتها الجانبية إلى الحد الأدنى. الغرض من هذه البحث هو دراسة الاستخدام المحتمل لمستخلص جذع *Musa paradisiaca* L. في خفض السيتوكينات المسببة للالتهابات TNF α و IL-1 β و IL-6 في التهاب الأمعاء لدى الفئران. تم تقسيم ثلاثين ذكور الفئران سلالة wistar (*Rattus norvegicus*) الذين تتراوح أعمارهم بين 2-3 أشهر إلى 5 مجموعات مع 6 تكرارات. أعطيت المجموعة الضابطة الإيجابية والسلبية مذيب لمستخلص جذع موسى باراديسياكا إل. تم علاج المجموعات P1 و P2 و P3 مع المستخلص. تم علاج المجموعات لمدة 14 يوماً. في اليوم الثامن، أعطيت جميع الفئران الإندوميثاسين كحافز التهاب الأمعاء، باستثناء الفئران في مجموعة التحكم السلبية التي أعطيت مذيب الإندوميثاسين فقط. في اليوم الخامس عشر، تم قتل الفئران بشكل رحيم واخذ الصائم من أجل تحضير الكيمياء المناعية. وقد تم تحليل نتائج اختبار كيمياء النسيج المناعي إحصائياً باستخدام ANOVA ثم اتبعه اختبار دنكن. أظهرت النتائج أن منح مستخلص موس موسى باراديسياكا إل له نشاط مضاد للالتهابات ضد أنسجة الصائم الملتهبة. تم توضيح النشاط

المضاد للالتهابات ضد تلف أنسجة الصائم من خلال التعبير الموهن من السيتوكينات الالتهابية الالتهابية IL-1 β و IL-6 و TNF- α في الصائم. أظهرت جرعة متزايدة آثار أكثر ايجابية.

Introduction

The Non-Steroidal Anti-inflammatory Drugs (NSAIDs) are oftenly used as medication to pain, inflammatory, and fever. The use of these medications is very effective in overcoming pain, fever, and inflammation, but it is often accompanied by side effects on mucosal erosion i.e. that can form ulcers, perforations and bleeding to cause death (1). This happens because NSAIDs have wide enterohepatic circulation. One of NSAIDs that has the most toxic side effects on intestinal mucosa is indomethacin. Granting a systemic NSAIDs also cause damage to the small intestine due to biliary excretion (2). The NSAIDs drugs showed toxic effects on the small intestine through a constitutive enzyme inhibition of cyclooxygenase-1 (COX1) which subsequently led to a decrease in the synthesis of protective prostaglandins. The NSAIDs are also thought to have local effect that damage the mucosa of the small intestine. On the cellular level, Indomethacin also induces mitochondrial damage of vilienterosit which results a villus shortening (3). This situation causes a lot of increased permeability of the small intestine (4). The side effects of NSAIDs can be inhibited or reduced with the use of drugs that can increase the synthesis of protective prostaglandins.

Treatment efforts can be done by utilizing plants as medicines, mainly from sewage plants that have not been utilized optimally. Pisang Ambon (*Musa paradisiaca* L.) is one of very important plants that is economically important because all parts of the plant can be utilized. In Indonesian, pisang means banana. For example, banana flowers can be cooked, banana stems can be used as a traditional medicine, organic fertilizer, forage, and others (5). The sap of the banana tree can also be used as a wound healer (6). Methanol extract of *Musa paradisiaca* L. can be used as wound healer (7).

Pisang Ambon (*Musa paradisiaca* L.), particularly the stem, have polyphenolic compounds as antioxidant activity which serves to inhibit the concentration of fat, has a capacity of electron donor and the reduction of metal ions, as well as serve as a chelating agent to the metal ion. The methanol extract of *Musa paradisiaca* var. Sapiantum L have the anti-inflammatory effect against enteritis in rats which were induced with Indomethacin (8).

The inflammation process in the small intestine which is induced by indomethacin involves oxidant compounds that cause oxidative damage on the mucosa. The granting of brown seaweed in rats, which have experimental enteritis by indomethacin, may reduce the inflammatory process that is allegedly happening on intestinal mucosa via the attenuation of the negative effects of oxidants. Enteritis

induced by indomethacin is a form of inflammation that has many hispathological similarities to inflammatory bowel disease. The reactive oxygen compounds play a significant role in the process of inflammation on enteritis induced by indomethacin. An increase in reactive oxygen compounds in the tissues of the small intestine causes oxidative damage that worsen the inflammation.

It can be studied by observing the expression of proinflammatory cytokines including 'tumor necrosis factor- α ' (TNF- α) and interleukin 1 β (IL-1 β), which are the major factors in the mucosa damage of the small intestine. The explanation of the effect of the *Musa paradisiaca* L. stem extract granting against inflammation can be used as a theoretical foundation for further research about the prevention and treatment of enteritis induced by NSAIDs particularly indomethacin.

The results of the research are expected to explain the influence of the *Musa paradisiaca* L. stem extract granting against inflammation which can be observed on the expression of TNF- α , IL-1 β and IL-6 proinflammatory cytokines in rats's enteritis. The explanation of the effect of the *Musa paradisiaca* L. stem extract against inflammation can be used as a theoretical foundation for further research about the prevention and treatment of enteritis induced by NSAIDs particularly indomethacin. Aim of present work was to study the potential use of *Musa paradisiaca* L. stem extract in attenuating the expression of TNF α , IL-1 β and IL-6 proinflammatory cytokines in rats' enteritis.

Materials and methods

Ethical approval

The experiment was carried out with the ethical clearance by the Commission of Health Research Ethics, Faculty of Dentistry, Universitas Airlangga No. 168/KKEPK.FKG/VIII/2016.

Animals

Thirty male wistar strain rats (*Rattus Norvegicus*) aged 2-3 months and weight 150-200 g. The animals were grouped into 5 groups.

Materials

Indomethacin, a banana (*Musa paradisiaca* L.) stem, 10% formalin in 0.15 M PBS (pH 7.4), formic acid, 30%/0.28 M sodium citrate, ethanol, xylene, paraffin, water for injection, mayer hematoxylyn, eosin, chloroform, glacial acetic acid, 10% NaCl, ketamine, Methyl Green 1%, rat's monoclonal antibodies of TNF α , IL-1 β and IL-6 antibodies, Goat anti mouse IgG biotin labeled, SA-HRP

(Streptavidin-Horse Peroxidase), DAB (3,3 diamino benzidine tetrahydrochloride).

Instrumentations and tools

Glass objects, glass cover, electron microscope, surgical tools, test tubes, medicine pots, rotary evaporator, pH meter, balance, camera, and ANNOVA software.

Preparation of the extract

Banana stem was cleaned, cut into small pieces, and dried. Once dry, the cleaned banana stem was mashed, resulting 900 g banana powder. The powder was extracted using maseration method with ethanol 96% (3000 ml). The obtained maserate was collected and evaporated using rotary evaporator under vacuum, resulting thick extract of 45 g. The ethanol extract of the banana stems was put in air tight containers and stored in refrigerator till time to use.

Animal treatments

The first group (negative control, K-) consists of 6 male Wistar rats were given only a solvent of banana extract and indomethacin solvent. The second group (positive control, K+) consists of 6 male Wistar rats were given an indomethacin 15 mg/kg body weight orally to trigger enteritis without giving extracts of banana stems. The third group (P1) is composed of six male Wistar rats which were administered with the banana stem extract 5 mg/kg (9) for 7 days. The fourth group (P2) is composed of six male Wistar rats which were administered with the banana stem extract 10 mg/kg (9) for 7 days. The fifth group (P3) is composed of six male Wistar rats which were administered with the banana stem extract 20 mg/kg (9) for 7 days.

On the 8th day, the rats were administered with indomethacin 15 mg/kg (single dose) of body weight orally using oral gavage as enteritis inductions (10). The administration of the banana stems extract was continued until 7 days after the first administration. On the 15th day, all rats were dissected in order to obtain the jejunum tissue. The TNF α , IL-1 β and IL-6 immunohistochemical examination was performed in each group.

Histopathology and immunohistochemistry

The manufacture of deparaffinized paraffin blocks and the TNF α , IL-1 β and IL-6 immunohistochemical expression examination were performed in accordance with Boenisch methods (11). The paraffin blocks were cut using rotary microtome with thickness 4 μ m. Blocking with 3% H₂O₂ in PBS pH 7.4 and in blocking with 1% BSA in PBS for 60 minutes. Lebelled the slides with primary antibodies which are anti-TNF α , IL-1 β , and IL-6 in 4 degrees Celsius 1% BSA overnight. Washed the slides with PBS pH 7.4 three times for 5 minutes. Incubated the slides with SA-HRP (Horseradish Peroxidase-Streptavidin) 1:500 for 40 minutes at room temperature. Washed the slides with PBS pH 7.4

three times for 5 minutes. Dropped the slides with the DAB (3,3 benzidine diamino tetra hydrochloride) chromogen substrate for 20 minutes. Washed with PBS pH 7.4 three times for 5 minutes. Wash with H₂O three times for 5 minutes each. Counter stained with Methyl Green 1% at room temperature. The slides were soaked with tap water for 5 minutes. Preparations were made and dried overnight at room temperature & the slides were ready to use.

Statistical analysis

A statistical analysis was performed to TNF α , IL-1 β and IL-6 expression variables on the 6 small intestine tissue by scoring the value based on Knodel scoring methods (12). To find out if there is a meaningful difference in the expression of TNF α , IL-1 β and IL-6 on the jejunum tissue between the groups, ANOVA test was performed and then followed by double Duncan's Distance test with significance level of 5%.

Results

Indometacin, the enteritis inducer, was administered with dose 10 mg/kg, 15 mg/kg, and 20 mg/kg to each in 6 animals. It was performed in an effort to obtain the optimal dose of enteritis induction without causing the death. The results showed that the most proper dose of enteritis induction was 15 mg/kg. The results of the exploration can be seen in Figure 1.




Figure 1: Rats' feces, before induction (black arrow) after induction (red arrow).

Figure 1 shows that the Indomethacin with a dose of 15 mg/kg was successfully used as enteritis induction. The indication can be seen in the rat's feces (Figure 1). The feces signify the presence of diarrhea in the rat where the feces were more rodents and there was bleeding in comparison previous feces before induction.

Histopathological observation of rats' jejunum which has been administered with indomethacin and administered with banana (*Musa paradisiaca* L.) extract can be seen in the Figure 2.

Immunohistochemical examination was performed by using monoclonal antibody against IL-1 β , IL-6 and TNF- α proteins. Positive results are characterized by the presence of brown spots on the cytoplasm. The results were examined using a microscope with 10x40 magnification.

The immunohistochemical examination results with monoclonal antibodies against the expression of IL-1 β , to see the effect of the banana stem extract (*Musa paradisiaca* L.), can be seen in Figure 3 and Table 1.

The immunohistochemical examination results with monoclonal antibodies against the expression of IL-6, to see the effect of the banana stem extract (*Musa paradisiaca* L.), can be seen in Figure 4 and Table 2.

The immunohistochemical examination results with monoclonal antibodies against the expression of TNF α , to see the effect of the banana stem extract (*Musa paradisiaca* L.), can be seen in Figure 5 and Table 3.

Table 1: The interleukin 1 β (IL-1 β) expression of rats' jejunum on IHC examination

Groups	The average of IL-1 β expression \pm SD (cell/viewing field)
Negative Control (K-)	32.00a \pm 2.36
Positive Control (K+)	64.67e \pm 4.13
5 mg/kg banana stem extract (P1)	53.33d \pm 3.07
10 mg/kg banana stem extract (P2)	45.50c \pm 5.64
20 mg/kg banana stem extract (P3)	39.83b \pm 3.25

Table 2: The interleukin 6 (IL-6) expression of rats' jejunum on IHC examination

Groups	The average of IL-6 expression \pm SD (cell/viewing field)
Negative Control (K-)	28.33a \pm 2.16
Positive Control (K+)	60.00d \pm 2.00
5 mg/kg banana stem extract (P1)	48.83c \pm 2.61
10 mg/kg banana stem extract (P2)	42.00b \pm 8.40
20 mg/kg banana stem extract (P3)	28.17 a \pm 3.82

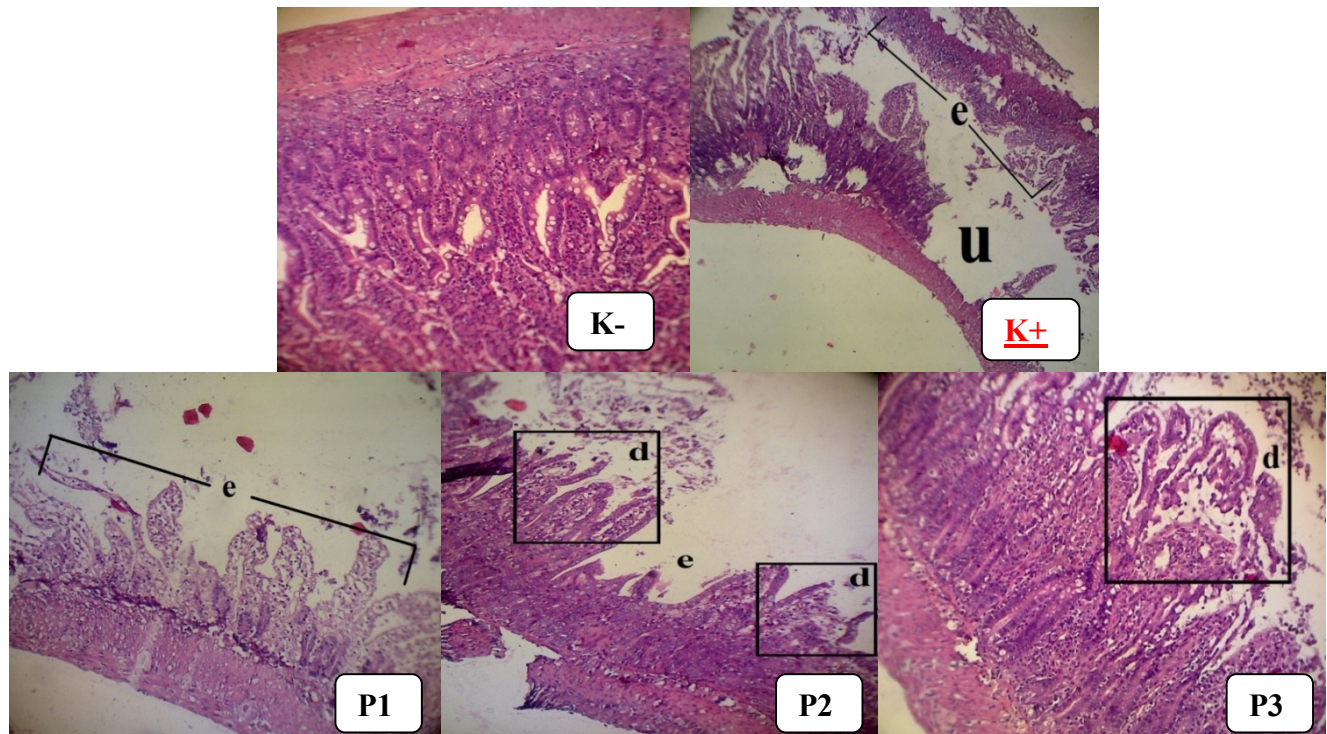


Figure 2: Histomicrograph of epithelium of mucosa jejunum. H.E color with 100x magnification using Optilab ® viewer. Explanation: (K-) there is no damage to the epithelium, (K+) many erosion (e) and ulcer (u) can be observed, (P1) there are many erosion (e), (P3) there is small desquamation (d)

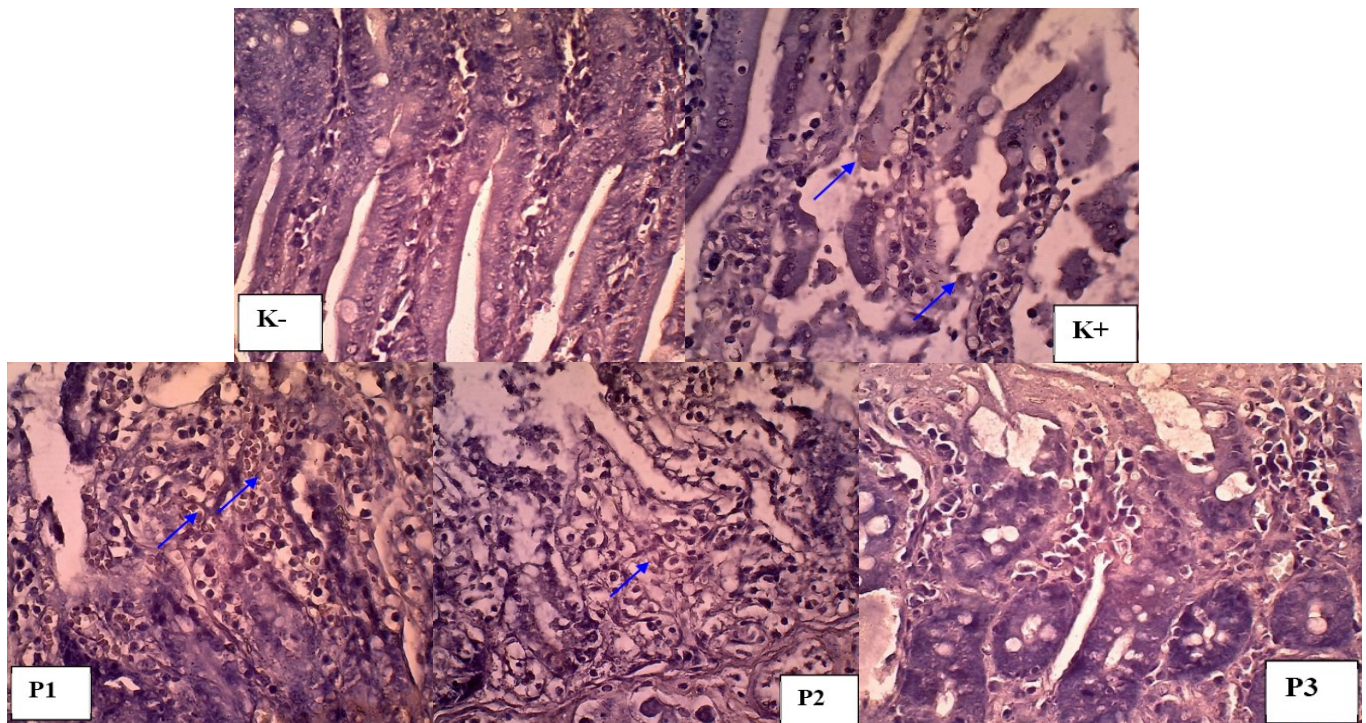


Figure 3: The interleukin 1 β (IL-1 β) expression from rat's jejunum on the IHC examination using a microscope with a magnification of 400 times.

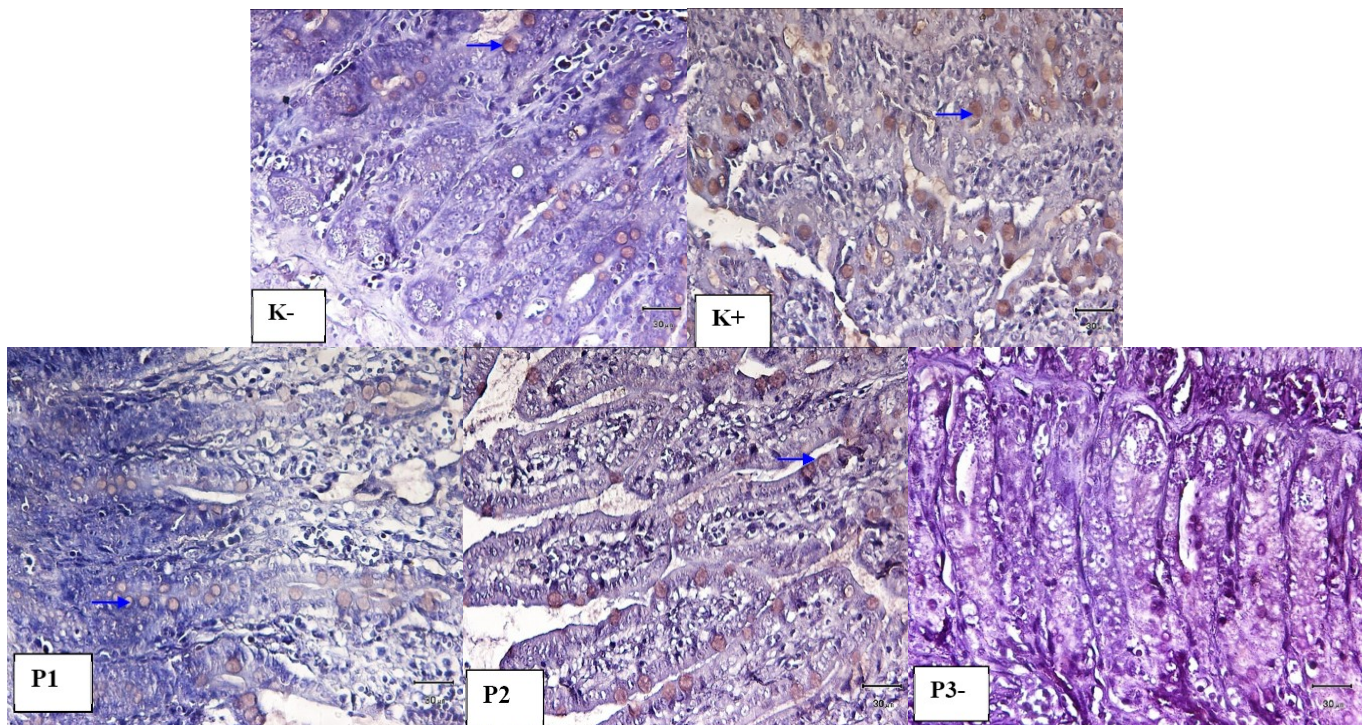


Figure 4: The interleukin 6 (IL-6) expression from rat's jejunum on the IHC examination using a microscope with a magnification of 400 times.

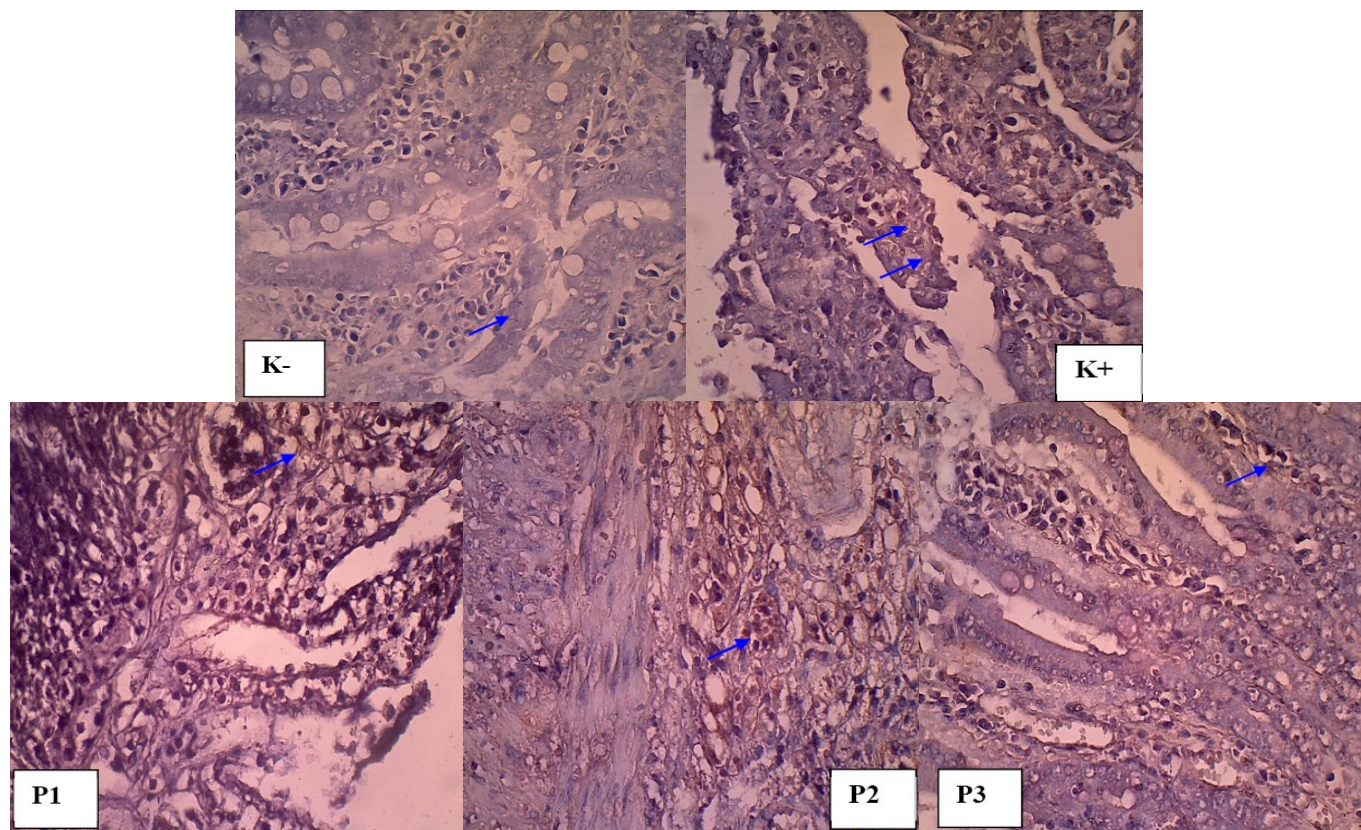


Figure 5: The interleukin TNF α expression from rat's jejunum on the IHC examination.

Table 3: The interleukin TNF α expression of rats' jejunum on IHC examination

Groups	The average of TNF α expression \pm SD (cell/viewing field)
Negative Control (K-)	43.66a \pm 3.20
Positive Control (K+)	79.67d \pm 3.88
5 mg/kg banana stem extract (P1)	59.33c \pm 7.31
10 mg/kg banana stem extract (P2)	53.83b \pm 3.25
20 mg/kg banana stem extract (P3)	44.83a \pm 3.25

Discussion

The results showed that the administration of banana stem extract (*Musa paradisiaca* L.) has an anti-inflammatory activity against inflamed jejunum. Anti-inflammatory activity against tissue damage in the small intestine was indicated by a decreased expression of IL-1 β , IL-6, and TNF- α proinflammatory cytokines in jejunum. In increasing doses, the results showed a more significant decrement of IL-1 β , IL-6 and TNF- α proinflammatory cytokines expressions in jejunum. This is possible because the higher the dose, the more potent anti-inflammatory

active ingredient, which was expressed by the decrement of IL-1 β , IL-6 and TNF- α proinflammatory cytokines in the jejunum. The expression of IL-1 β , IL-6 and TNF- α proinflammatory cytokines in jejunum is a systematic acute phase response caused by the combined work of IL-1, TNF- α , and IL-6. Interleukin-1, IL-6, and TNF alpha work synergistically to increase T cell activation and acute inflammatory responses. In 12-24 hours from the beginning of the acute phase response, increased IL-1, TNF- α , and IL-6 induce the production of acute phase proteins by hepatocytes. The ability of IL-1, TNF- α , and IL-6 to induce the production of acute phase proteins by liver cells occurs through the induction of the same transcription factor, NF-IL-6, after each cytokine binds to its receptor. This macrophage is an active cell that has phagocytosis activity that releases more inflammatory mediators and cytokines. The active macrophages tissue secretes IL-1, IL-6, and TNF- α cytokines, which induce many local and systemic changes in acute inflammatory responses. All three cytokines work locally by inducing coagulation and increasing vascular permeability. TNF- α and IL-1 induce increased expression of adhesion molecules in vascular endothelial cells. TNF- α stimulates the expression of Selectin E that bind to adhesion molecules on neutrophils,

whereas IL-1 induces increased expression of ICAM-1 and VCAM-1 which bound to integrins in lymphocytes and monocytes. Neutrophils, monocytes, and lymphocytes in the circulation are attached to the blood vessel wall by recognizing the adhesion molecule which then moves through the blood vessel wall and into the tissue. IL-1 and TNF- α also work on macrophages and endothelial cells to induce the chemokines that play a role in neutrophilic influx through enhancement of their adhesion to vascular endothelium and act as strong chemotactic factors. IFN- γ and TNF- α activate macrophages and neutrophils, increase phagocytic activity, and increase release of lytic enzymes into the tissues (13).

Local acute inflammatory responses can occur without much involvement of the immune system. Cytokines, that are sometimes released at the site of inflammation, facilitate the attachment of immune cells to vascular endothelial cells and the migration of these cells through blood vessel walls into the tissues. This leads to lymphocyte, neutrophil, monocyte, eosinophil, basophil, and mast cell infestations to the site of damaged tissue, where they play a role in clearance of antigens and tissue healing (13). The timing and intensity of the local acute inflammatory response should be carefully regulated to control tissue damage and facilitate the tissue repair mechanism which is needed for healing.

Conclusion

To conclude, the provision of banana stem extract can decrease TNF α , IL-1 β and IL-6 expression. TNF α , IL-1 β and IL-6 expression were decreased even more along with the increased dose of banana stem extract.

Acknowledgement

The authors would like to thank DRPM of Directorate of Higher Education (DIKTI) for providing the fund to conduct this research.

References

1. Peesa J, Yalavarthi P, Rasheed A, Mandava V. A perspective review on role of novel NSAID prodrugs in the management of acute inflammation. *J Accute Dis.* 2016;5(5):364-381.
2. Niu X, de Graaf I, van der Bij H, Groothuis G. Precision cut intestinal slices are an appropriate ex vivo model to study NSAID-induced intestinal toxicity in rats. *Toxicol Vitro.* 2014;28(7):1296-1305.
3. Basivireddy J, Vasudevan A, Jacob M, Balasubramanian K. Indomethacin-induced mitochondrial dysfunction and oxidative stress in villus enterocytes. *Biochem Pharmacol.* 2002;64(2):339-349.
4. Silver K, Littlejohn A, Thomas L, Bawa B, Lillich J. Suppression of calpain expression by NSAIDs is associated with inhibition of cell migration in rat duodenum. *Toxicol.* 2017;383:1-12.
5. Suhartanto M, Harti H. *Teknologi Sehat Budidaya Pisang: Dari Benih Sampai Pasca Panen.* 1st ed. [ebook] Bogor: Pusat Kajian Hortikultura Tropika Lembaga Penelitian Dan Pengabdian Kepada Masyarakat Institut Pertanian Bogor. Available at: <http://pkht.ipb.ac.id/wp-content/uploads/2016/02/buku-ajar-teknologi-sehat-pisang.pdf> [Accessed 24 Dec. 2017].
6. Pangestika R. Efektivitas Getah Batang Semu Pisang Ambon (*Musa acuminata*) Dan Getah Batang Semu Pisang Kepok (*Musa balbisiana*) Pada Penyembuhan Luka Bakar Mencit (*Mus musculus*). Undergraduate. Universitas Sanata Dharma. 2017. 69p. <http://repository.usd.ac.id/id/eprint/9424>
7. Amutha K, Selvakumari U. Wound healing activity of methanolic stem extract of *Musa paradisiaca* Linn. (Banana) in Wistar albino rats. *Int Wound J.* 2014;13(5):763-767.
8. Akinlolu A. Musa Sapientum Improv. Total Antioxidant and Lipid Profile Status of Adult Wistar Rats In Indomethacin – Induced Gastric Ulceration. *Dergipark.ulakbim.gov.tr.* Retrieved 16 November 2017, from <http://dergipark.ulakbim.gov.tr/sducmfrr/article/view/1018003883/0>.
9. Salau B. Methanolic Extract of Musa Sapientum Surker Proffers Antioxidant Effects against Indomethacin-Induced Ulceration Oxidative stress in Wistar Rats. *Int J Pharm Biol Sci.* 2013;8(1):07-12. <http://dx.doi.org/10.9790/3008-0810712>
10. Odabasoglu F, Cakir A, Suleyman H, Aslan A, Bayir Y, Halici M, Kazaz C. Gastroprotective and antioxidant effects of usnic acid on indomethacin-induced gastric ulcer in rats. *Ethnopharmacol.* 2006;103(1), 59-65. 10.1016/j.jep.2005.06.043.
11. Li W, Hao D, Fan T, Huang H, Yao H, Niu X. Protective effect of chelerythrine against ethanol-induced gastric ulcer in mice. *Chemo-Biological Interactions.* 2014;208:18-27. 10.1016/j.cbi.2013.11.011
12. Rüschoff J, Dietel M, Baretton G, Arbogast S, Walch A, Monges G. HER2 diagnostics in gastric cancer—guideline validation and development of standardized immunohistochemical testing. *Virchows Archiv.* 2010;457(3):299-307. 10.1007/s00428-010-0952-2
13. Kindt T, Goldsby R, Osborne B, Kuby J. *Kuby immunology.* New York: W.H. Freeman; 2007. 574 p. ISBN: 97780716785903