

Effect of natural apple cider vinegar on morphometric changes of salivary glands in hydroxy urea treated mice

Rafah Sami Ayoub

Ph.D. Vet-
physiology

Alhan Daham Hadi
Al-Moula
M. Sc. Medical
anatomy

Tahani Abdul Aziz
Al-Sandok
Ph.D. Dental
pharmacology

Received
28/12/2005

Accepted
3/4/2006

الخلاصة

درس تأثير المعاملة بالهاييدروكسي يوريا وخل التفاح الطبيعي على الغدد اللعابية الكبيرة (النكافية, تحت الفكية واللسانية) اعطي الهايدروكسي يوريا بجرعة 80 ملغم / كلغم / اليوم عن طريق الفم وقد أدى إلى انخفاض معنوي في قطر وارتفاع الخلايا في عنبيات الغدد النكافية واللسانية مقارنة مع مجموعة السيطرة وأيضا إلى انخفاض في قطر القناة البينية والمخططة في الغدد النكافية وتحت الفكية واللسانية مقارنة مع مجموعة السيطرة بينما ارتفاع خلايا القناة البينية للغدد النكافية وتحت الفكية انخفض لكن بشكل غير معنوي. إعطاء خل التفاح الطبيعي بجرعة (20 ملغم/كلغم) لمدة (7) أيام بعد المعاملة بالهاييدروكسي يوريا لمدة سبعة أيام أدى إلى انخفاض معنوي في قطر وارتفاع الخلايا في عنبيات الغدد النكافية وتحت الفكية واللسانية مقارنة مع مجموعة السيطرة. بينما قطر عنبيات الغدد النكافية وتحت اللسانية انخفض معنويا بالمقارنة مع المجموعة العاملة بالهاييدروكسي يوريا وكذلك قطر القناة المخططة للغدد النكافية وتحت الفكية انخفض معنويا بالمقارنة مع مجموعة السيطرة والمجموعة المعاملة بالهاييدروكسي يوريا وأما ارتفاع خلايا القناة البينية للغدد النكافية وتحت اللسانية انخفض معنويا مقارنة مع مجموعة السيطرة.

وأن إعطاء خل التفاح الطبيعي بنفس الوقت مع الهايدروكسي يوريا لمدة سبعة أيام أظهر انخفاضاً معنوياً في قطر وارتفاع خلايا العنبيات في الغدد النكافية وتحت اللسانية مقارنة

مع مجموعة السيطرة وكذلك انخفض قطر القناة البينية والمخططة للغده النكافية وتحت الفكية واللسانية مقارنة مع مجموعة السيطرة. اما ارتفاع خلايا القناة المخططة للغده النكافية وتحت الفكية واللسانية قد انخفض بشكل معنوي مقارنة مع مجموعة السيطرة. وتشير النتائج في هذه الدراسة بأن خل التفاح الطبيعي لم يظهر تأثيراً وقائياً للتأثير المدمر للهيدروكسي يوريا على الغدد اللعابية.

ABSTRACT

The effect of hydroxy urea (cytotoxic) drug and cotreatment of natural apple cider vinegar on mice major salivary gland (parotid submandibular and sublingual) were studied.

Hydroxy urea at a dose of 80 mg/kg/day produced a significant decrease in the diameter and height of parotid acini and sublingual gland acini compared to control also the diameter of intercalated duct and striated duct of parotid, submandibular, sublingual showed significant decrease compared to control. While the height of intercalated duct cells of parotid and submandibular gland declined but no to a significant level.

Administration of natural apple cider vinegar (20 mg/kg) for (7) days after hydroxy urea treatment for (7) days caused a significant decrease in the diameter and height of parotid acini and sublingual and submandibular acini compared to control. While the diameter of parotid acini and sublingual acini decreased significantly as compared to hydroxy urea group. Also the diameter of striated duct of parotid and submandibular gland decreased significantly as compared to hydroxy urea group and control group. The height of intercalated duct cells of parotid and sublingual glands decreased significantly compared to control group.

Administration of natural apple cider vinegar at the same time with hydroxy urea for (7) days showed a significant decrease in the diameter and height of parotid acini and sublingual acini compared to control also the diameter of intercalated duct and striated duct of parotid, submandibular and sublingual gland decreased significantly as compared to control. The height of striated duct cells of parotid, submandibular and sublingual decreased significantly compared to control.

The result in this study showed that natural apple cider vinegar has no protective effect to the degenerative effect of hydroxy urea on salivary gland.

Introduction

Salivary glands have become a useful investigative tool for the study of some basic problems in physiology, such as trans epithelial salt and water transport, protein syntheses and exocytosis, the neuropharmacology of autonomic nerves and receptors and stimulus secretion coupling (1).

Salivary glands are exocrine tissues that have the main function of secreting saliva. These glands consist of acini ducts, nerves, myoepithelial cells, mast cells and plasma cells, approximately 80% of each gland is acini which secrete electrolyte, water and proteins (2). It is well established that salivary glands fluid secretion is under neural control. Parasympathetic and sympathetic nerves innervate acinar cell, duct cells, and blood vessels(3). The cytotoxicity of hydroxy urea is to combat melanoma, chronic myelogenous leukemia, primary squamous cell cancer of head and neck, various cancers. The mechanism of action of hydroxy urea involves inhibition of deoxyribonucleic acid (DNA) syntheses hydroxy urea acts primarily as an inhibitor of ribonucleotide reductase this leads to the depletion of essential DNA precursors. Repair of DNA damage is also inhibited the lethal effect of hydroxy urea on cells in (s) phase and is known radiosensitiser (4,5). Chemotherapy generally produces salivary gland dysfunction and taste dysfunction and xerostomia (6). Salivary gland dysfunction produces difficulties in eating, swallowing and increases the incidence to infection and the consequent development of mucositis, oral mucositis can obviously causes sever pain and add significantly to the morbidity of cancer therapy (7). The constant cellular division associated with epithelial renewal that renders the oral cavity so susceptible to damage by anticancer therapies. Chemotherapy primarily damages and kills dividing cells by damaging DNA or interfering with cell division, consequently tissues with more cells undergoing division at the time of administration of the therapy will be damaged worse than those with lower rate of cellular division (8).

Since natural apple cider vinegar has hypolipidemic and antioxidative effect (9) and protective effect on bone marrow (10) and spermatogenesis in male mice (11). The present study was designed to investigate the effect of natural apple cider vinegar on morphometric changes of salivary glands in mice treated with hydroxy urea.

Materials and Methods

Twenty four male Swiss mice weighting (25-30) gm were housed under controlled conditions of natural light (14 hr light and 10 hr dark) and temperature (25 ± 2 C^o). Commercial pelleted food and water were given ad libitum.

Experimental design

Animals were randomly divided in to (4) groups -6- mice each.

Group 1: received (0.2) ml of distilled water by oral intubation.

Group 2: was administered 80 mg/kg of hydroxy urea by oral intubation for (7) days.

Group 3: was administered 80 mg/kg of hydroxy urea by oral intubation for (7) days followed by 20 mg/kg of natural apple cider vinegar (Seaford, New York 11703) for (7) days.

Group 4 : was administered 20 mg/kg of natural apple cider vinegar and 80 mg/kg of hydroxy urea at the same time by oral intubation for (7) days.

On completion of experiments, animals were sacrificed by ether administration. The salivary gland (parotid, submandibular, sublingual) were removed, fixed in alcoholic lavdowsky fixative (12). For (24) hour, then dehydrated in ascending grades of alcohol using 70%, 90%, 96% and two changes of absolute alcohol respectively with a period of one hour for each then cleared by two changes of xylene with period of one hour for each.

Finally they were embedded in three changes of (60)C° melting point paraffin for two hour each.

The blocks were cut with an average thickness of (4 μ m) using microtome, mounted on slides and stained with delafied hematoxylin and Eosin(13) for general morphological study.

Morphometric analysis: The diameter of acini, intercalated duct, and the height of cells of acini, intercalated and striated duct were measured with afilar micrometer mounted in place of the eyepiece of amicroscope.

Diameter was measured from basement membrane to basement membrane of the cell.

Height was measured from center to basement membrane of the cell.

Data were analyzed statistically using one way analysis of variance (ANOVA) and groups differences were determined using Duncan multiple range test the results were expressed as mean \pm standard error. The level of significance was at $p < 0.05$ (14).

Results

Table (1): Shows the diameter and height of acinar cells and striated duct and intercalated duct cells of parotid gland. Hydroxy urea produced a significant ($p < 0.05$) decrease in diameter and height of acinar cells and striated duct cells and diameter of intercalated duct cells as compared to control group, while the height of intercalated duct cells did not show significant differences as compared to control group yet they tend to be declined.

Natural apple cider vinegar administered for (7) days to mice pretreated for (7) days with hydroxy urea caused a further significant decrease ($P < 0.05$) in diameter and height of acinar cells and intercalated duct cells and striated duct cells compared to control while the diameter of acini and striated duct decreased significantly ($P < 0.05$) as compared to hydroxy urea group.

Natural apple cider vinegar and hydroxy urea administered to mice at the same time for (7) days resulted in a significant ($P < 0.05$) decrease in diameter and height of acinar cells and striated duct cells and diameter of intercalated as compared to control group. While the height of intercalated duct cells show no significant changes as compared to control and hydroxy urea group.

Table (2): represent the diameter and height of acinar cells and intercalated duct cells and striated duct cells of submandibular gland. Hydroxy urea produced a significant ($P < 0.05$) decrease in the diameter of intercalated duct and diameter and height of striated duct cells as compared to control while the diameter and height of acinar cells and height of intercalated duct cells did not show significant differences as compared to control group yet they tend to be declined.

Natural apple cider vinegar administered for (7) days to mice pretreated for (7) days with hydroxy urea caused a significant ($P < 0.05$) decrease in the diameter and height of acinar cells and striated duct cells and diameter of intercalated duct as compared to control while diameter of striated duct show significant ($P < 0.05$) decrease compared to hydroxy urea group.

Natural apple cider vinegar and Hydroxy urea administered to mice at the same time for (7) days resulted in a significant ($P < 0.05$) decrease in the diameter and height of striated duct cells and diameter of intercalated duct as compared to control.

While diameter and height of acinar cells and height of intercalated duct cells did not show a significant differences as compared to control and hydroxy urea group.

Table (3): represent the diameter and height of acinar cells and intercalated duct cells and striated duct cells of sublingual gland.

Hydroxy urea produced a significant ($P < 0.05$) decrease in the diameter and height of acinar cell and intercalated duct cells and striated duct cells as compared to control.

Natural apple cider vinegar administered for (7) days to mice pretreated for (7) days with hydroxy urea produced a significant ($P < 0.05$) decrease in the diameter and height of acinar cells as compared to control and hydroxy urea group.

While the diameter and height of intercalated duct cells and striated duct cells show significant ($P < 0.05$) as compared to control. Hydroxy urea and natural apple cider vinegar administrated to mice at the same time for (7) days resulted in asignificant ($P < 0.05$) decrease in the diameter and height of acinar cells and intercalated duct cells and striated duct cells as compared to control.

Histological Study

The histological appearance of the major salivary glands (Parotid, submandibular and sublingual) in treated animals showed morphometric changes as shown in (table 1,2,3), acinar cells had lost their foamy appearance and became irregular in shape, smaller in diameter, striated ducts had altered in folded in membranes and were apparently smaller than in control glands.

- The general structure of the all salivary gland (parotid, submandibular and sublingual) remained similar to the control tissues, however, morphological changes were detected in the acinar cells and striated and intercalated ducts.
- It has been noticed that there is a significant decrease in the diameter and height of acini and ductal cells in the treated group than the control group (table 1,2,3).
- The morphological changes of acini had different manifestation represented by a shrinkage of acinar cells with an ill-defined cellular outline, the shrinkage and smaller in diameter of the acinar cells lead to an increase in the interstitial space, pyknosis of the nuclei and the presence of vacuoles inside the cytoplasm of the cells which differ in their size and location from cell to cell. In most of the tissues sections there were increase in the number of blood vessels.

Beside the above changes in the acinar cells there were a morphological changes in the striated and intercalated ducts which represented by atrophy and shrinkage of the duct cells which lead to changes of the cells from columnar to cuboidal cells, some of the nucleus of these cells showed pyknosis. The most important and clear changes is the presence of large space around all the striated ducts.

Table (1) : Effect of natural apple cider vinegar and hydroxy urea on morphometric changes of parotid gland in mice

Experimental groups	Diameter of acini (μm)	Height of acinar cell (μm)	Diameter of intercalated duct (μm)	Height of intercalated duct cells (μm)	Diameter of striated duct (μm)	Height of striated duct cells (μm)
Control	A 14.59 \pm 0.86	A 6.76 \pm 0.32	A 7.28 \pm 0.68	A 2.95 \pm 0.47	A 21.98 \pm 1.20	A 10.08 \pm 0.88
Hydroxy urea (80 mg/kg) for (7) days	B 6.82 \pm 0.69	B 2.48 \pm 0.45	B 4.34 \pm 0.38	A 2.73 \pm 0.44	B 8.07 \pm 1.76	B 2.60 \pm 0.48
Hydroxy urea (80 mg/kg) for (7) days followed by natural apple cider vinegar (20 mg/kg) for (7) days	C 5.88 \pm 0.51	B 2.49 \pm 0.44	B 4.44 \pm 0.47	B 1.82 \pm 0.00	C 5.86 \pm 0.60	B 2.36 \pm 0.43
Hydroxy urea (80 mg/kg) + natural apple cider vinegar (20 mg/kg) for (7) days	BC 6.61 \pm 0.61	B 2.64 \pm 0.47	B 4.65 \pm 0.47	AB 2.34 \pm 0.44	B 7.64 \pm 0.84	B 2.62 \pm 0.47

Values are mean \pm S.E
The different letters mean significantly at ($P < 0.05$)

Table(2): Effect of natural apple cider vinegar and hydroxy urea on morphometric changes of submandibular gland in mice

Experimental groups	Diameter of acini (μm)	Height of acinar cell (μm)	Diameter of intercalated duct (μm)	Height of intercalated duct cells (μm)	Diameter of striated duct (μm)	Height of striated duct cells (μm)
Control	A 8.39 \pm 0.21	A 4.92 \pm 0.85	A 7.28 \pm 0.70	A 2.60 \pm 0.45	A 19.81 \pm 0.61	A 8.00 \pm 0.90
Hydroxy urea (80 mg/kg) for (7) days	AB 7.01 \pm 0.24	AB 3.60 \pm 0.47	B 5.46 \pm 0.61	A 2.27 \pm 0.46	B 10.28 \pm 0.90	B 3.94 \pm 0.12
Hydroxy urea (80 mg/kg) for (7) days followed by natural apple cider vinegar (20 mg/kg) for (7) days	B 5.94 \pm 0.38	B 2.27 \pm 0.48	B 4.68 \pm 0.97	A 1.82 \pm 0.0	C 8.69 \pm 0.79	B 2.81 \pm 0.43
Hydroxy urea (80 mg/kg) + natural apple cider vinegar (20 mg/kg) for (7) days	AB 7.05 \pm 0.80	AB 3.08 \pm 0.41	B 5.46 \pm 0.12	A 2.21 \pm 0.16	B 11.33 \pm 0.50	B 3.64 \pm 0.61

Values are mean \pm S.E
The different letters mean significantly at (P < 0.05)

Table (3): Effect of natural apple cider vinegar and hydroxy urea on morphometric changes of sublingual gland in mice

Experimental groups	Diameter of acini (μm)	Height of acinar cell (μm)	Diameter of intercalated duct (μm)	Height of intercalated duct cells (μm)	Diameter of striated duct (μm)	Height of striated duct cells (μm)
Control	A 21.39 \pm 0.61	A 9.49 \pm 0.45	A 7.50 \pm 0.12	A 3.18 \pm 0.18	A 19.86 \pm 0.03	A 8.43 \pm 0.49
Hydroxy urea (80 mg/kg) for (7) days	B 14.56 \pm 0.81	B 6.06 \pm 1.10	B 5.15 \pm 0.33	B 2.14 \pm 0.42	B 9.46 \pm 0.75	B 2.33 \pm 0.67
Hydroxy urea (80 mg/kg) for (7) days followed by natural apple cider vinegar (20 mg/kg) for (7) days	C 12.01 \pm 0.75	B 4.18 \pm 0.87	B 4.63 \pm 0.65	B 2.31 \pm 0.45	B 8.08 \pm 0.95	B 2.54 \pm 0.94
Hydroxy urea (80 mg/kg) + natural apple cider vinegar (20 mg/kg) for (7) days	B 15.26 \pm 0.90	B 6.55 \pm 0.60	B 5.25 \pm 0.34	B 2.08 \pm 0.68	B 9.10 \pm 0.48	B 3.64 \pm 1.20

Values are mean \pm S.E
The different letters mean significantly at ($P < 0.05$)

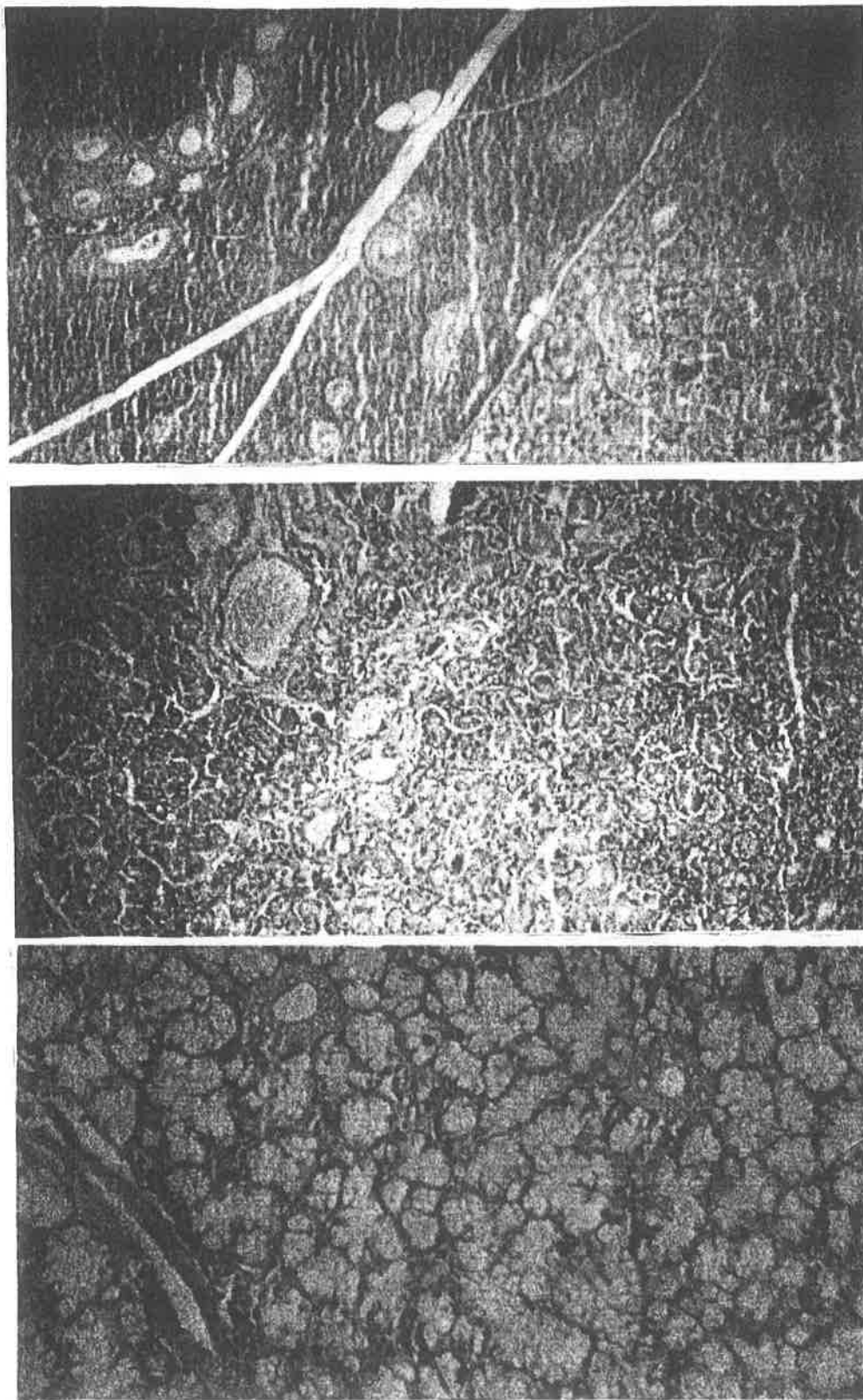


Fig. 1,2,3 : Light micrograph of control parotid, submandibular and sublingual salivary gland Hematoxyline and Eosin 1[X-125], 2 and 3 [X-250]

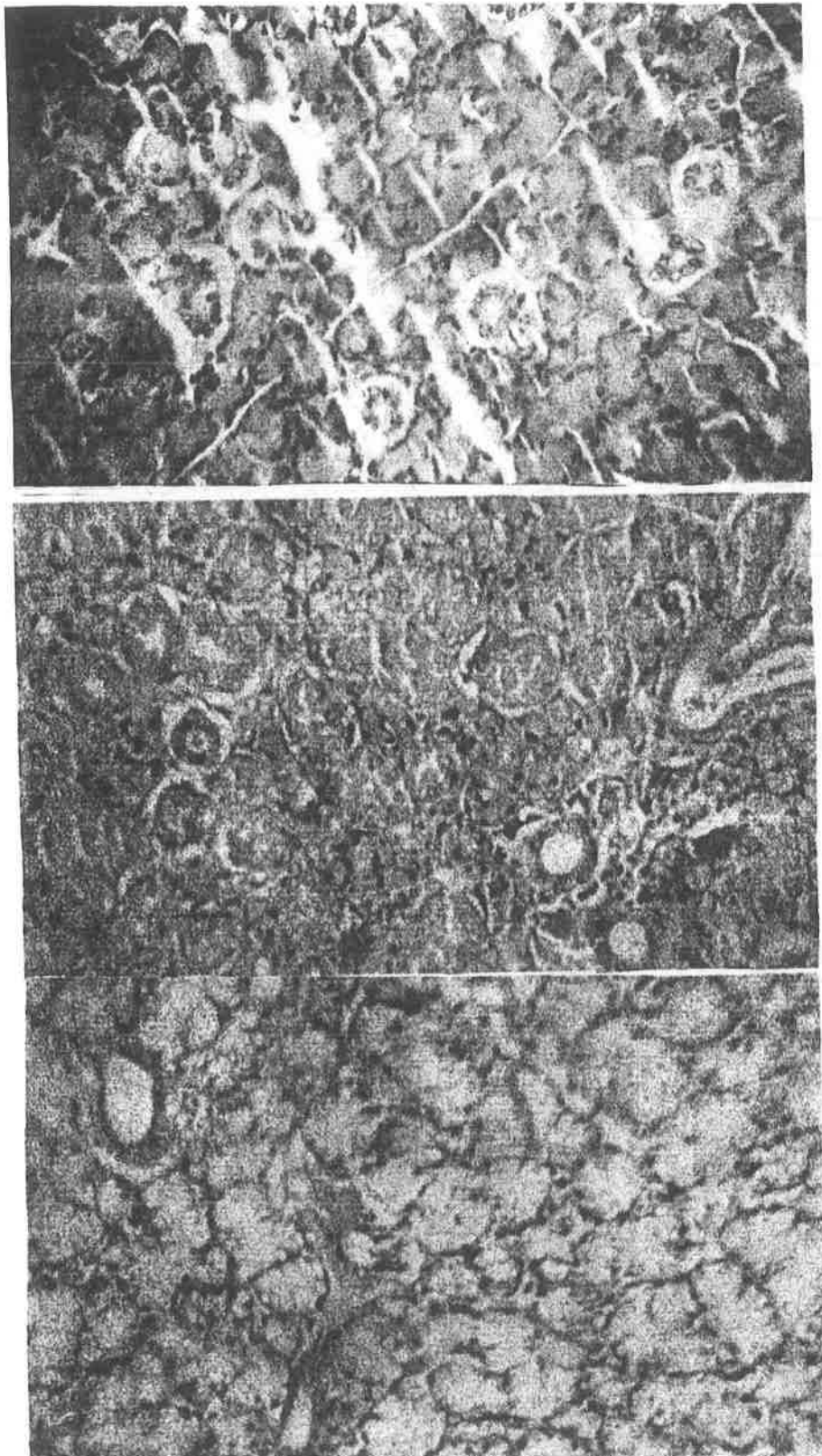


Fig. 4,5,6 : Light micrograph of parotid, submandibular and sublingual salivary gland treated with hydroxy yrea for 7 days followed by natural apple cider vinegar for 7 days Hematoxyline and Eosin 4,5,6 [X-250]

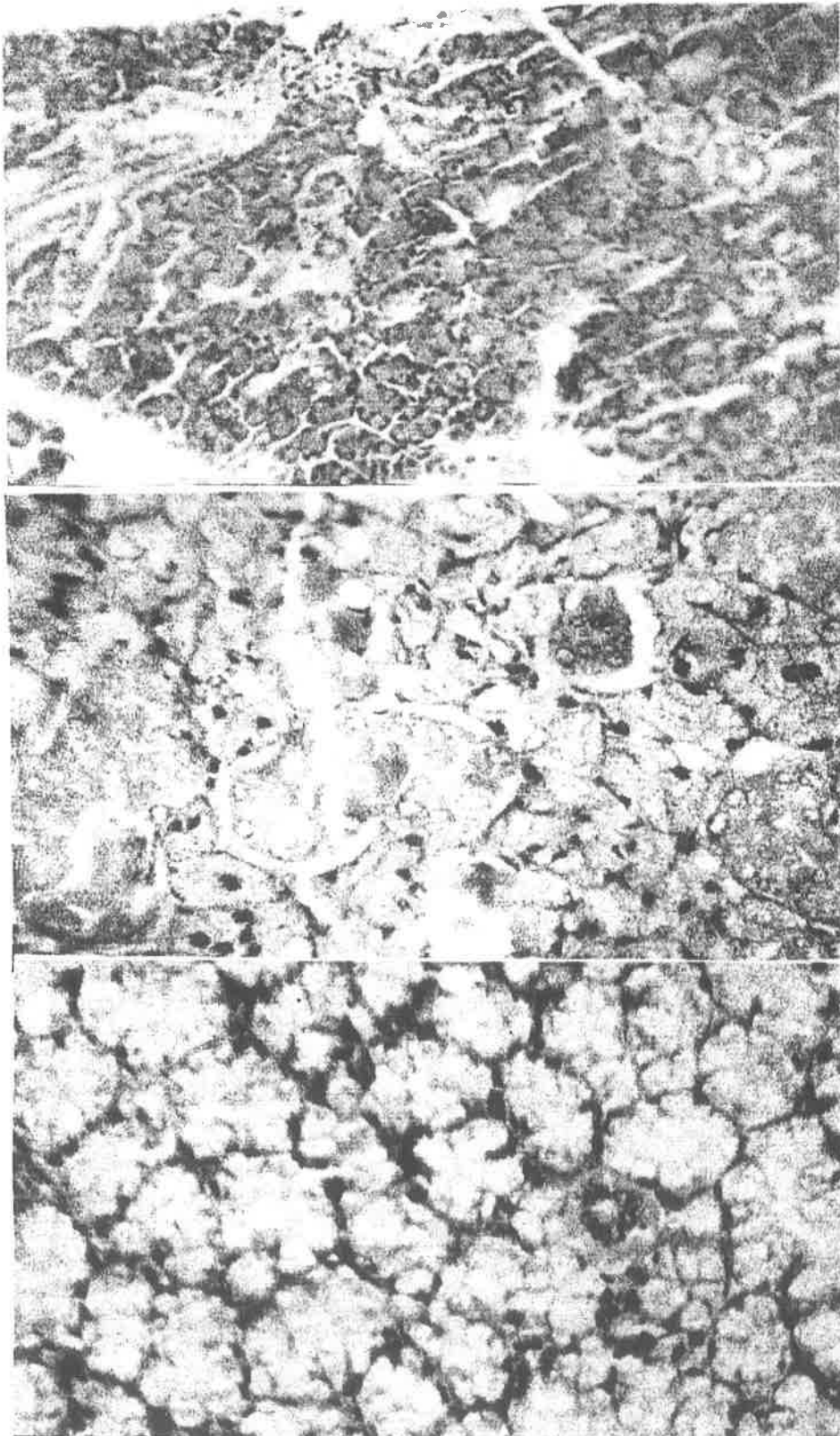


Fig. 7,8,9 : Light micrograph of parotid, submandibular and sublingual salivary gland treated with hydroxy yrea and natural apple cider vinegar for 7 days at the same time Hematoxyline and Eosin 7,9 [X-250] , 8 [X -500]

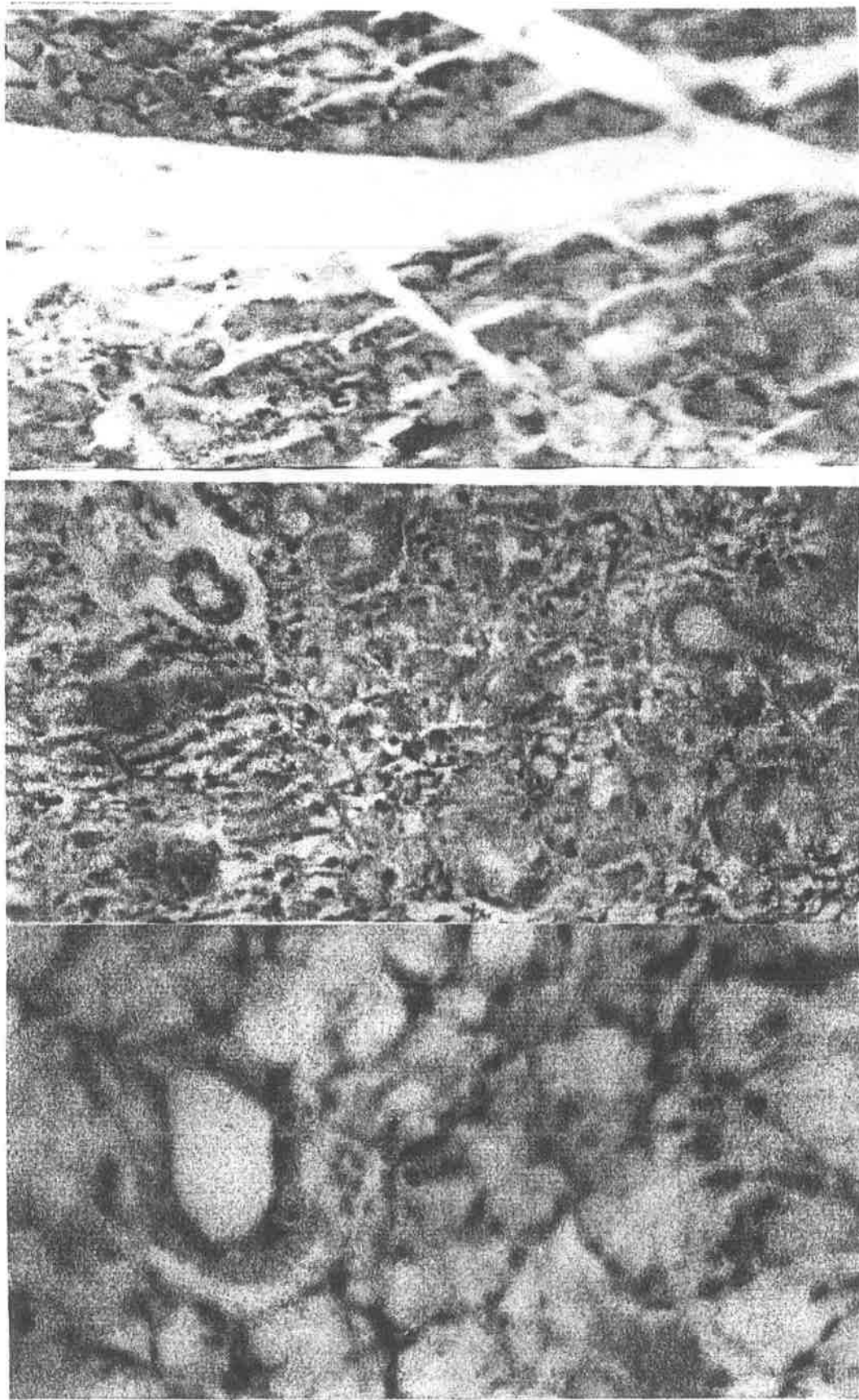


Fig.10,11,12: Light micrograph of parotid, submandibular and sublingual salivary gland treated with hydroxy yrea for 7 days Hematoxyline and Eosin 10 ,11 [X-250] , 12 [X -500]

Discussion

Submandibular gland in mice and rat is considered as the largest in size followed by parotid and sublingual glands which are the smallest. In this study the largest submandibular gland responded to chemotherapy by only decrease in the diameter of intercalated duct and diameter and height of striated duct cells but there is no significant changes in the acini cell of the gland. However, the smallest salivary gland which is the sublingual responded to hydroxy urea by a significant reduction in all the criteria measured. Similarly all the criteria measured were significantly reduced with a middle sized parotid gland. These changes could be explained by the fact that the smaller the size the salivary gland the higher the incidence of the damage. The salivary glands consist of acini, ducts, nerves, myoepithelial cells and mast cells and plasma cells.

Approximately 80% of each gland is acini which secrete electrolytes and proteins (2). Damage of salivary gland by hydroxy urea in this study was in accordance with Lockhart et al (1981) who demonstrated that cancer chemotherapy can induce minor salivary gland ductal dilation and acinar degeneration in 50% of patients studied (15). Whereas clinical studies of salivary flow rates have been inconsistent. Squier (1990) demonstrated sialochemistry changes in saliva such as loss of antibodies and antibacterial protein and altered secretion of glycoprotein (16).

50% of hydroxy urea is metabolized in liver to an inactive metabolite (CO_2 and urea) and active metabolite (Nitric oxide). Hepatic and renal is the main route of excretion 50%. In toxic doses hyperuricemia occurs (17) in sickle cell anemia JinJie (1997) demonstrated that the metabolism of hydroxy urea in rats lead to generation of (NO) based on the detection of HbNO in blood and nitrosylhemo protein complexes in liver from hydroxy urea treated rats at dose as low as 80% mg/kg hydroxy urea. The production of (NO) reaches its maximum in (3-4) hrs (18).

Pacelli et al (1996) demonstrated that hydroxy urea can be oxidized to nitroxide and ultimately (NO) (19). Urea can circulate harmlessly in blood stream throughout the body, it is called blood urea nitrogen (BUN). Urea is dispensed from the liver then degraded to NH_3 . The salivary gland concentrate and excrete urea in saliva (20). However (NO) generally lead to vasodilatation of blood vessels and may be responsible for no changes in height of intercalated duct cells in submandibular and parotid glands.

Natural apple cider vinegar produced no protective effect in this study due to the fact that degenerative changes occurred in the acinar cells of salivary gland were irreversible.

References

1. Abdolahi, M.; Dephour, A. and Kazemia, P. (2000). Alteration by cadmium submandibular gland secretory function and the role of the L-arginine / nitric oxide pathway. *Pharmacological research*. 42 (6) P:59.
2. Young, JA (1979). Salivary secretion of inorganic electrolytes *Int. Rev. Physical* 19, (1-58).
3. Schneyer, LH; Young, JA and Schneyer, CA (1972). Salivary secretion of electrolytes. *Physiol. Rev.* 52, 720-777.
4. Katzung, BC (2000). *Basic and Clinical Pharmacology* 8th ed. Lange medical book McGraw Hill publication New York P:482.
5. *Compendium of pharmaceutical and specialties* (2004), Hydrea, Canadian pharmacists association (cited by internet @yahoo.com).
6. Schubert, MM. (1991). Development of a staging system for chemotherapy-induced stomatitis western consortium for cancer nursing. *Research. Cancer. Nurs* 14: 6-12.
7. Dreizen S. (1990). Description and incidence of oral complication. *NCI Monogr.* 9 : 11-5.
8. Mandel, ID. (1980). Sialo chemistry in diseases and clinical situations affecting salivary gland, *Crit. Rev. Clin. Lab. Sci.* 86 : 321-366.
9. Ayoub, RS. Effect of apple cider vinegar and simvastatin on blood lipid profile in adult female rabbit. Ph. D. thesis college of veterinary medicine. University of Mosul. 2003.
10. Ayoub, RS, Al-Sandok, T and Youif, SW. (2005). protective effect of apple cider vinegar in hydroxy urea treated mice. *J. Education and Science* 17 (2) P:66-72.
11. Ayoub, RS, El-Nouri, A. (2005) spermatogenesis in mice exposed to hydroxy Urea: protective effect of natural apple cider vinegar. *J. Education and science*. Vol. (17) in press.
12. Humason, GL (1972). *Animal tissue technique* 3rd ed. San Francisco: W. H. Freeman and Company p:125 .
13. Luna, LG (1968). *Manual of Histological staining methods*. 3rd ed. New York : McGraw Hill book company p:34.

Effect of natural apple cider vinegar on morphometric changes of

14. Steel, RG ; Torrie, TH (1995). Principle and procedures of statistics. McGraw Hill book Co, Inc. New York p:60-120.
15. LockHart, PB; Sonis, ST (1981). Alteration in the oral mucosa caused by chemotherapeutic agent. J Dermatd surg on col 7 : (1019-1025).
16. Squier, CA. (1990) Mucosal alterations. NCI Monogr 9 : 169-172.
17. Dalton, RN; Turner, C.; Dick, M.; Height, SE and etc. (2005). The measurement of urinary hydorxy urea in sickle cell anemia. British J. of hematology 130 (1) : 138 July.
18. Jinjie, J; Sandra, JJ; David, PB; Michael, RG; Hiroshi, M and Ronald, PM. (1997). In vivo production of nitric oxide in rats after administration of hydroxy urea Molecular pharmacology 52(6) : 1081-1086.
19. Pacelli, RJ; Jaira, JA; Cook, DA and Krishna, MC. (1996). Hydroxy urea react with heme protein to generate nitric oxide. Lancet 347 : 900 [Med line].
20. Krehbiel, CR; Ferrell, Cl and Freetly, HC. (1998). Effect of Frequency of supplementation on dry matter intake and net portal and hepatic flux of nutrient in mature ewes that consume low quantity of orage J. Anim. Sci. 76 : 2464.