

PATHOLOGICAL CHANGES IN LIVER, SPLEEN AND LYMPH NODES IN MICE TREATED WITH HYDATID CYST FLUID OF HUMAN ORIGIN AND ITS TOXIN FRACTIONS

Omaima A. N. Abbu
Department of Biology
College of Education
Mosul University

Received
13/9/2004

Accepted
15/12/2004

الخلاصة

تم حقن الفأر الابيض السويسري *Mus musculus* ، داخل البريتون ، بسائل الاكياس العدرية من أصل انسان والاجزاء السامة المعزولة منه بالتركيزين 10 و 50 مايكروغرام/ملليتر. لوحظ وجود تغييرات واضحة في وزن ومعامل تضخم الكبد ، الطحال والعقد اللمفية في الفئران المحقونة ، فضلاً عن ظهور تغييرات مرضية نسجية. تشير النتائج التي تم الحصول عليها الى ان هنالك علاقة بين ظهور الآفات المرضية والتغيرات التي تحصل في وزن ومعامل تضخم العضو في الاعضاء المذكورة أعلاه.

ABSTRACT

Swiss albino mice *Mus musculus* were injected , intraperitoneally , with hydatid cyst fluid (HCF) of human origin and its toxin fractions (TFs) at two concentrations (10 and 50 µg/ml). Obvious changes in the weight and organ index of liver, spleen and lymph nodes of the injected mice , in addition to histopathological changes , were observed. Results obtained indicate that there is a relationship between appearance of pathological lesions and changes in weight and organ index of the above mentioned organs.

INTRODUCTION

Cystic echinococcosis is a zoonotic disease of global importance, distributed in most parts of the world, especially sheep and cattle rearing countries (1). More than 70 species of ungulates , in addition to man , act as intermediate hosts (2). They gain infection through ingesting food or drink contaminated with eggs of the tapeworm.

Pathogenic tissue damage is caused by replacement of host tissues by growing cysts and, in some instances, by vascular compromise. Organ

dysfunction results mainly from gradual process of space-occupying, or displacement of vital host tissues, vessels of organs (3). Histopathological changes which occur due to the presence of cysts in different organs have been studied by previous workers (e.g. 4-23). However, few studies have focused on the histopathology of tissues in hosts infected with hydatid disease and treated with immunomodulators of different sources. In the course of their studies, they took the changes occur in liver and spleen of infected hosts into consideration (24). However, as far as toxin fractions, isolated from cyst fluid, are considered, there seems to be no studies focused on the damage they may cause to host tissues, apart from their effect on macrophages (25-28) and microphages (29). The present study, therefore, deals with the damage caused by the toxin fractions, isolated from cysts of human origin, on liver, spleen and lymph nodes of mice injected with these toxin fractions.

MATERIALS & METHODS

Source of hydatid cysts

Hydatid cysts of human origin were obtained from surgically-proved positive patients, directly after surgery, from different hospitals in Mosul. Cysts were intact, not treated with any substance prior to surgery.

Isolation of cyst fluid

Protoscoleces were removed from the cysts, aseptically, according to Smyth (30). After centrifugation at 7600 g (10000 rpm), using a cryofuge 6-4 (Heraeus) for 10 minutes at 4°C, the supernatant (HCF) was separated and kept in sterile containers in refrigerators at -20°C until used.

Separation of cyst fluid fractions

Cyst fluid fractions (CFFs) were separated according to Janssen *et al.*(28). Ammonium sulphate was added to the cyst fluid (49.35 gm/100ml) and the fluid was left in the refrigerator at 4°C for 24 hrs to give enough time for precipitation of protein. The fluid was centrifuged at 37000g (22150 rpm) for 30 minutes at 4°C, using the above mentioned centrifuge. An equal volum of chloroform was added to the supernatant. Two layers were formed after centrifugation. The chloroform layer was separated and half volume of methanol (chloroform : methanol= 2:1, v/v) was added and centrifuged under the same conditions, mentioned above. The supernatant was dried by rotary evaporator. The chloroform-methanol soluble fractions (CMSFs), or TFs, were kept in refrigerator at-

20°C until used. At use, they were dissolved in few drops of chloroform and completed by phosphate buffer saline (PBS).

Experimental design

21 parasite-free, laboratory-bred, 5-6 weeks old, swiss albino male mice of the species *Mus musculus* (balb/C) were used in the present study. 3 mice were used as control group (not injected), and 18 were injected, intraperitoneally, with HCF and its TFs as follows:

Experiment 1

6 male mice were injected with crude hydatid cyst fluid (HCF) at a rate of 1ml/ mouse of human origin (from liver and lung). After 32 days mice were killed and their liver, spleen and lymph nodes were removed.

Experiment 2

Same number of mice, as in experiment 1, were injected with TFs at a concentration of 10 µg/ml and also mice were killed after 32 days and their liver, spleen and lymph nodes were removed.

Experiment 3

Same number of mice, as in experiment 1 and 2, were injected with TFs at a concentration of 50 µg/ml and also mice were killed after 32 days and their liver, spleen and lymph nodes were removed.

Estimation of organ index

Organ index was estimated according to Kroeze and Tanner (31) as follows:

$$\text{Organ index} = \frac{\text{Organ weight}}{\text{Body weight} - \text{Organ weight}} \times 1000$$

Tissue preparation

For light microscopy, tissues (liver, spleen and lymph nodes) of mice treated with HCF and its toxin fractions were fixed in 10% neutral buffered formalin, processed routinely in alcohol and , finally, embedded in paraffin. and 4-6µm thick-sections were prepared. The sections were stained with hematoxylin-eosin (H & E) (32).

Statistical analysis

Student t-test was applied to determine the significance between the means at $P < 0.05$ (33)

RESULTS

Weight and organ index

Cysts of liver origin (Table 1)

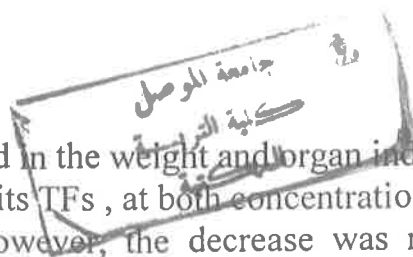
The weight and organ index of liver decreased significantly in mice treated with HCF and its TFs , at both concentrations, compared with the control group. The decrease in weight was also significant in mice treated with HCF compared with those treated with TFs at 50µg/ml. However, no significant difference appeared between mice treated with TFs at 10µg/ml and 50µg/ml . The organ index decreased, non significantly, in mice treated with HCF compared with those treated with TFs, at both concentrations, and in mice treated with TFs at 10µg/ml compared with those treated with TFs at 50µg/ml.

For spleen, a non-significant increase in its weight and organ index was noticed in mice treated with HCF and TFs at 50µg/ml compared with the control group and those treated with TFs at 10µg/ml.

The weight and organ index of lymph nodes increased significantly in mice treated with HCF, compared with those treated with TFs, at both concentrations, and the control group. A non-significant decrease was observed in mice treated with TFs at 10µg/ml compared with those treated with TFs at 50µg/ml.

Cysts of lung origin (Table 2)

A significant decrease was noticed in the weight and organ index of liver in mice treated with HCF and its TFs , at both concentrations, compared with the control group. However, the decrease was not



significant between mice treated with HCF and those treated with TFs, at both concentrations, and also between the two concentrations of the TFs.

For spleen, a non-significant increase was noticed in mice treated with TFs, at both concentrations, compared with control group whereas the opposite was noticed in mice treated with HCF compared with the control group. A non-significant increase in the organ index was also noticed in mice treated with HCF and its TFs, at both concentrations, compared with the control group. The opposite was observed in mice treated with HCF compared with those treated with TFs, at both concentrations, and in mice treated with TFs at 10 μ g/ml compared with those treated with TFs at 50 μ g/ml.

A significant increase in the weight and organ index of lymph nodes was observed in mice treated with HCF and its TFs, at 10 μ g/ml, compared with the control group. A non-significant decrease was noticed in mice treated with TFs, at 50 μ g/ml, compared with those treated with TFs, at 10 μ g/ml, and those treated with HCF.

Histopathological changes

Liver

A high degree of fatty change, foci of coagulative necrosis with enlargement of kupffer cells and infiltration of inflammatory cells around a central vein and the portal area when the concentration 10 μ g/ml of the TFs was used. The histopathological changes were more severe when TFs at 50 μ g/ml were used (Figs. 1 & 2). With HCF a fatty change in the cytoplasm of hepatocytes was observed with infiltration of lymphocytes in the portal area. In addition to necrotic areas (Fig. 2).

Spleen

When TFs at 10 μ g/ml were used, necrotic foci with depletion of lymphocytes and replacement by plasmacytoides were observed in the center of splenic sinusoids with proliferation of megakaryocytes, hemosiderine pigmentation in the cytoplasm of macrophages and precipitation of a substance, eosinophilic in color, around splenic sinusoids. When the concentration 50 μ g/ml was used, the changes observed were more severe. With HCF the changes observed were hemosiderine pigmentation, proliferation of plasmacytoides and congestion of blood vessels (Fig. 3).

Pathological Changes in Liver, Spleen

Lymph nodes

When TFs at 10 μ g/ml were used, a hemorrhage and congestion of blood vessels, proliferation of lymphocytes with thickening of the capsule and hemosiderine pigmentation were observed. At the concentration 50 μ g/ml, the changes observed were more severe (Fig. 4)

Table (1). Changes in weight and organ index of liver, spleen and lymph nodes in mice treated with HCF and its TFs, obtained from liver cysts of human origin.

Organ	Con. μ g/ml	Weight (gm)	Organ index
Liver	C.	1.8487 A	76.3363 A
	HCF	0.8130 C	42.4570 B
	TF 10	1.0447 BC	49.7353 B
	TF 50	1.1647 B	55.2700 B
Spleen	C.	0.1387 A	5.5340 A
	HCF	0.1507 A	7.5013 A
	TF 10	0.1117 A	5.0630 A
	TF 50	0.1543 A	6.9980 A
Lymph node	C.	0.0030 B	0.1153 B
	HCF	0.0077 A	0.3770 A
	TF 10	0.0020 B	0.0907 B
	TF 50	0.0023 B	0.0980 B

C. : control group , HCF : Hydatid cyst fluid , TF : Toxin fraction

Table (2). Changes in weight and organ index of liver, spleen and lymph nodes in mice treated with HCF and its TFs, obtained from lung cysts of human origin.

Organ	Con. $\mu\text{g/ml}$	Weight (gm)	Organ index
Liver	C.	1.8487 A	76.3363 A
	HCF	0.6500 B	39.3523 B
	TF 10	0.9227 B	51.3240 B
	TF 50	0.8250 B	51.0160 B
Spleen	C.	0.1387 A	5.5340 A
	HCF	0.1230 A	7.2413 A
	TF 10	0.1593 A	8.4353 A
	TF 50	0.1543 A	9.2250 A
Lymph node	C.	0.0030 B	0.1153 B
	HCF	0.0070 A	0.4037 A
	TF 10	0.0070 A	0.3820 A
	TF 50	0.0037 AB	0.2137 AB

Pathological Changes in Liver, Spleen




Fig. (1). Section in liver of a mouse treated with TFs at 50 μ g/ml showing fatty changes in hepatocytes with infiltration of lymphocytes around the central vein. H & E 400X . FC: Fatty change

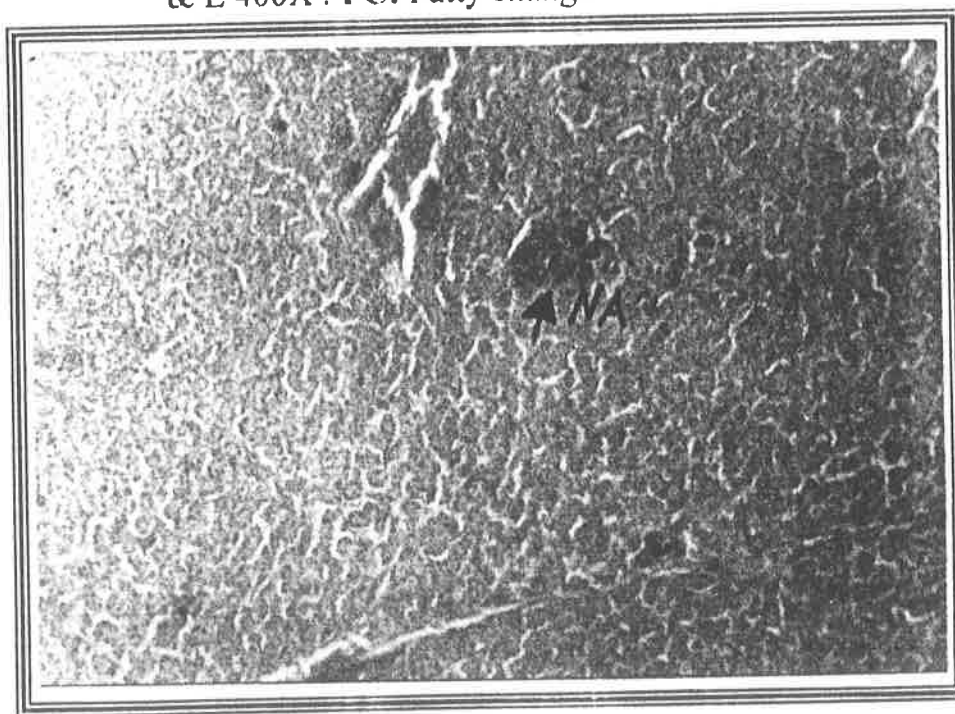


Fig. (2). Section in liver of a mouse treated with TFs at 50 μ g/ml showing focal necrotic areas in the tissues. H & E 200X
NA: Necrotic area.




Fig. (3). Section in the spleen of a mouse treated with TFs at $50\mu\text{g/ml}$ showing precipitation of substance, eosinophilic in color, around lymphoid sinusoids. H & E 400X . E: Eosinophilic

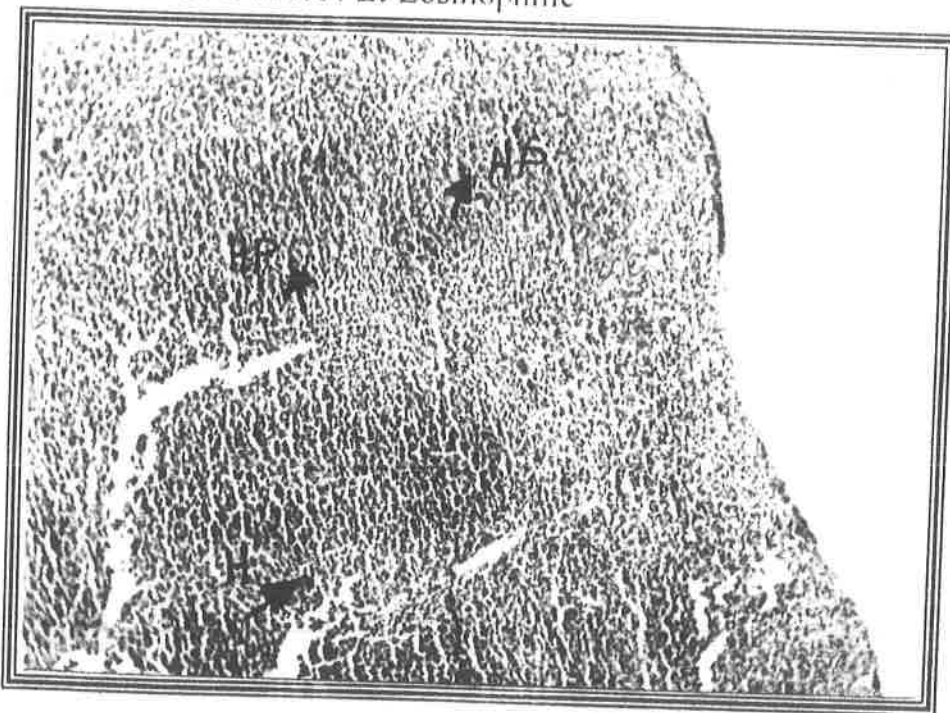


Fig. (4). Section in the lymph nodes of a mouse treated with TFs at $50\mu\text{g/ml}$ showing congestion in the blood vessels with hemorrhage and hemosiderine pigmentation. H & E 400X. H: Hemorrhage , HP: Hemosiderine pigmentation, V: Vacuolation

DISCUSSION

The present study was conducted to demonstrate the histopathological changes along with the changes in the weight and organ index of liver, spleen and lymph nodes which may occur in mice treated with TFs and HCF isolated from hydatid cysts of human origin, obtained from liver and lung of infected hosts, at two concentrations (10 and 50 μ g/ml).

The results obtained demonstrate that there is an obvious relationship between appearance of pathological lesions and changes in weight and organ index of liver, spleen and lymph nodes. This result is in agreement with those of Al-Kennany *et al.* (24) and Salih *et al.* (36) on hydatid cysts of sheep and cattle origin, respectively. The appearance of necrotic lesions along with infiltration of lymphocytes is an indication of inflammatory response due to the fractions which seem to have stimulated the reticuloendothelial system through stimulation of lymphocytes to divide. The fatty changes occurred ensures the increase in the amount of lipid which may refer to the lipid nature of the TFs, as has been demonstrated previously (34). This, in turn, helped in the precipitation of lipid exceeding, quantitatively, the need of the cell in the cytoplasm, leading to a deficiency in the oxygen required for liberation of energy. This seems to have played a role in the necrosis occurred in the liver tissues (Figs 1 & 2). The hemosiderine pigmentation indicates the lysis of the red blood cells, liberating the hemoglobin. The protein part of this substance finally changes to hemosiderine which is engulfed the macrophages.

The precipitation of a substance, eosinophilic in color, around the splenic sinusoids, causing damage to these sinusoids, may refer to the amyloides. These amyloides may be a result of the ability of TFs to stimulate the immune cells, including the plasma cells, to divide and liberate more antibodies leading to antibody-antigen reaction (35) and their precipitation in the areolar tissue around the sinusoids (Fig. 3). When compared with the results obtained from TFs of sheep (24) and cattle (36) origin, the present results supports the previous findings that TFs of different host origin differ in their effect on the same host tissues (25). However, this needs further investigation.

Finally, the appearance of lesions in the lymph nodes is an evidence of acute lymphadenitis (37) which is an inflammatory response to the TFs due to the known role played by lymph nodes in the elimination of these fractions.

ACKNOWLEDGEMENT

The author would like to express her thanks to Prof. Dr. Nabeel E. Salih, Department of Biology, College of Education and Dr. Entisar R. Al-Kennany, Department of Pathology, College of Veterinary for their assistance and Zaid T. Abbawi for his assistance in statistical analysis.

REFERENCES

1. Andersen F.L. , Ouhelli H. and Kachani M. Compendium on Cystic Echinococcosis. Brigham Young University Print Services, UT 84604. (1997).
2. Smyth J.D. Changing concepts in microecology , macroecology and epidemiology of hydatid disease . In : Geerts S, Kumar V, Brandt J (Eds.) Helminth Zoonoses . Martinus Nijhoff Publishers.1-11 (1987).
3. Gottstein B. and Hemphill A. Chem. Immunol., 66:177-208 (1997).
4. Webster G.A. and Cameron, T.W.M. Can. J. Zool., 39 : 877-891 (1961).
5. Ali-Khan Z. J. Parasitol., 60 (2) : 231-235 (1974a).
6. Ali-Khan Z. J. Parasitol., 60 (2) : 236-242 (1974b).
7. Ali-Khan Z. Z. Parasit. J., 58 : 47-54 (1978a).
8. Ali-Khan Z. Immunology, 34:831-839 (1978b).
9. Ali-Khan Z. Exp. Parasitol., 46 : 157-165 (1978c).
10. Ali-Khan Z. and Siboo R. Z. Parasit. J., 62: 241-254 (1980).
11. Chatterjee K.P. Parasitology (Protozoology and helminthology in relation to clinical medicine). 12th ed. Chatterjee medical publishers. 121-126 (1981).
12. Al-Karmi T. and Ali-Khan Z. Br. J. Exp. Path., 65 : 405-417, (1984).
13. Ali-Khan Z. and Rausch R.L. Ann. Trop. Med. Parasitol., 81(4) : 381-392 (1987).
14. Al-Kennany E.R., M.Sc. Thesis, Coll. Vet. Med., Univ. Baghdad, Iraq. (1988).
15. Du T. and Ali-Khan Z. J. Exp. Path., 71 : 313-335 (1990).
16. Fattah M.I. M.Sc. Thesis, Coll. Sci. Al-Mustansiriya Univ. Baghdad. (1990).
17. Mufarrij A.A. , Arnaut A. , Meshefedjian G and Matossian R.N. Helminthologia, 27 (4): 279-290 (1990).
18. Al-Maadhedi A.M.S., M.Sc. Thesis, Coll. Sci., Al-Mustansiriya Univ. Iraq (1994).
19. Al-Taei A.F.M. Ph.D. Thesis, Coll. Sci., Univ. Al-Mustansiriya. (1996).
20. Ali-Khan Z. , Li W. and Chan S.L. Parasitol. Today, 12 (8):297-302 (1996).

Pathological Changes in Liver, Spleen

21. Ali A.A. Riv. Parassitol., 17 (61) , 2:183-193 (2000).
22. Ali A.A. and Salih, N.E. Riv. Parassitol., 17 (61):195-202 (2000).
23. Salih N.E. , Al-Kennany E.R. and Al-Sabawi B.H.H. Derasat. Under publication. (2004).
24. Al-Kennany E.R. , Salih N.E. and Abbu O.A.N. I. J. Vet. Sci. In Press (2005).
25. Osuna A. , Gamarro F. , Janssen D. , Castanys S. and De Rycke, P.H. Abstracts of the joint meeting (Parasitology and Protozoology, Brussels) 81 A (1985).
26. Janssen D. , Osuna A. , Lazuen J. and De Rycke P.H. J. Helminthol., 66: 124-131 (1992).
27. Janssen D. , De Rycke P.H. and Osuna A. Fol. Parasitol., 40:109-113 (1993).
28. Janssen D. , Rueda, M.C. , De Rycke, P.H. and Osuna A. Parasit. Immunol., 19:149-160 (1997).
29. Salih N.E. and Abbu O.A.N. Riv. Parassitol., Vol. XX (LXIII)-N. (3):167-182 (2002).
30. Smyth J.D. *In vitro* culture of *Echinococcus* spp. Proc. 13th Int. Cong. Hydatid. Madrid :84-95 (1985).
31. Kroeze W.K. and Tanner C.E. Int. J. Parasitol., 17(4) : 873-883 (1987).
32. Drury R.A.B. and Wallington E.A. Cartton's histological technique. 5th ed. Oxford University Press. (1983).
33. Al-Rawi K.M. and Khalaf-Allah A.M. Design and Analysis of Agricultural Experiments. Mosul University Press. (1980).
34. Osuna A. , Gamarro F. , Janssen D. , Carreras M.A. , Castanys S. , Adroher F.J. and De Rycke P.H. Rev. Iber. Parasitol. , 47: 47-52 (1987).
35. Al-Kennany E.R.. Riv. Parassitol., Vol. XIX (LXIII) N1 (2002).
36. Salih N.E. , Al-Kennany E.R. and Abbu, O.A.N. Riv. Parassitol., In Press (2005).
37. Al-Kennany E.R. Al-Qadisya J. Vol. 11, No. 1 October (1996).