

Focal epithelial hyperplasia in Yemeni families: Three case reports.



Sulaimani Dental Journal

Salwa M. Al- Shaikhani*

Abstract

This is the first time to get the opportunity to report and study three cases from three families with focal epithelial hyperplasia (FEH) in Yemen. Clinically they presented as focal and/or diffuse papillomatous lesions in the oral mucosa in children. The purpose of this paper is to add information concerning clinical feature, the possible etiologic factors and diagnosis of this disease which is totally unknown to the general Yemeni medical professionals and to raise dentist's awareness about these rare conditions.

Keywords: *Focal epithelial hyperplasia, human papillomavirus, Hecks disease.*

Received: November 2013, Accepted: January 2014

Introduction

FEH or Heck's disease was identified as a distinct entity in 1965. The disease is a lesion that is always discussed under the category of verrucal papillary lesions, It is characterized by distribution of asymptomatic, multiple soft nodular tissue masses on oral mucosa of lips, buccal mucosa, gingiva and tongue ⁽¹⁾. The peculiar lesions are small (0.3-1.0) cm, discrete, well demarcated and discovered incidentally. They occur in clusters or isolated groups which eventually spontaneously regress .The lesion disappears as the mucosa is stretched ⁽²⁾.

The disease was first named by Archard et.al. and Witkop and Niswander in native Americans, US, Brazil and in Eskimos ⁽³⁾. Since then the disease was reported in many populations like Bolivia ⁽⁴⁾, Iraq ⁽⁵⁾, Egypt ⁽⁶⁾ Israel ⁽⁷⁾, Nicaragua ⁽⁸⁾, and many other countries. More recent studies identified the lesion in other populations ^(9,10, 11,12). The suggested etiologic factors include a genetic predisposition ⁽⁷⁾, a dietary factor and a viral infectious process associated with HPV serotypes 13 and 32 ^(13,14,15,16).

The diagnosis is based on clinical examination and confirmed by microscopical findings ⁽⁸⁾. The possibility of diagnostic confusion with other similar diseases should be born in mind ⁽¹⁴⁾. Biopsy specimens show constant features ; a benign epithelial growth that extends upward, not down into underlying connective tissues, hence, the lesional rete ridges are at the same depth as the adjacent normal rete ridges, acanthosis and

parakeratosis. Ultrastructurely 50 nm diameter viral particles may be seen in spinous layer ⁽¹⁾.

The lesions cause no significant problem unless occur on visible lip, they persist for many months then spontaneously resolve with age without treatment and do not have a tendency to recur ⁽¹⁷⁾, but lesions may be conservatively excised or treated with laser or cryotherapy if necessary ^(8,12,15).No case of focal epithelial hyperplasia has been reported to transform into carcinoma. It should be remembered that focal epithelial hyperplasia may be an oral manifestation of AIDS ⁽¹⁷⁾.

Cases description

First case:

A 14 years old female attended oral diagnosis clinic in faculty of dentistry in Ibb University coming from Taiz governorate /Yemen. She was complaining of asymptomatic, small soft tissue masses on the inner surface of her right upper lip since one year. She and her father claimed that the condition was constant without any changes and family history revealed that no one of the eight members of the family was affected. However, she claimed that her school friend had a similar condition. The girl was from a low economical Yemeni rural society in Taiz city.

* Department of Preventive Dentistry, Technical Institute /Presidency of Sulaimani Polytechnic University.
Author contact: dr-salwa60@yahoo.com

On general physical examination other body systems were found normal and there were no skin lesions. Oral examination showed a cluster of (10-12) sessile, pinkish, small sized (from 2-5 mm), well demarcated papules on the labial mucosa of the right upper lip. Multiple tiny papules were also scattered over the right labial alveolar mucosa from the right canine region till the labial frenum. Two or three masses were also present near the right retro commissure, and one of them was keratotic (whitish) with a history of traumatic biting. Tongue was not involved. The papules were soft, painless but firm on palpation (figure 1).

Second case:

A 10 years old girl from Ibb city in Ibb governorate was attending the same clinic above with her mother complained from some lumps scattered in her mouth spontaneously since 2 years. She tried many medications prescribed by several dentists but with no effect. No one of her six family members were affected. Physical examination showed no systemic abnormalities and no significant past medical history. Oral examination showed multiple small sized (0.2-4mm) nodules scattered all over the mouth mucosa (labial and cheek mucosa, lateral and ventral surface of the tongue and lips mucosa (but there was no palatal lesions) .The nodules had identical color to normal mucosa without any keratosis or inflammation. On palpation, no tenderness was felt by the patient. Some of the lesions were coalesced obviously on lower left lip mucosa (figure 2).

Third case:

Three young children (8 years girl , 6, and 4 years old boys) from a family of seven members residing in Al- Sheir village in Ibb governorate, brought by their relative parents to the faculty mentioned above complaining from identical lesions in their mouths for the last eight months. The youngest one gets it three months later then his sister and brother. They visited several dentists and physicians and tried many remedies but without any cure or assurance or a definite diagnosis. The parents were terrified because they were told that the case was malignant and they will not pass it safely. All the kids were systemically healthy on general examination and their mouths showed approximately similar and irregular distribution of the lesion that is multiple small (0.2-0.5 mm) nodular and some papular masses which have whitish to pinkish color ,most of the lesions were scattered on the buccal mucosa , lips and dorsum tongue tissues. Individual lesions are sessile with smooth flat surface. History indicates no other relatives had similar lesions. Unfortunately we lost the photographs.

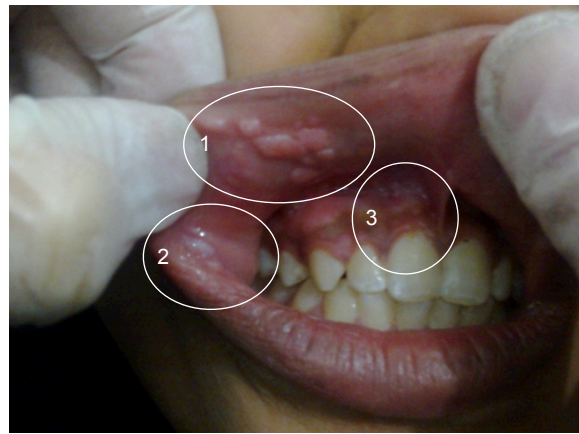


Figure 1: multiple, normal colour, sessile papules on labial mucosa (circle 1), Whitish papules on the retro commissural region (circle 2) and tiny masses (circle 3). The photograph is taken after scaling & polishing.

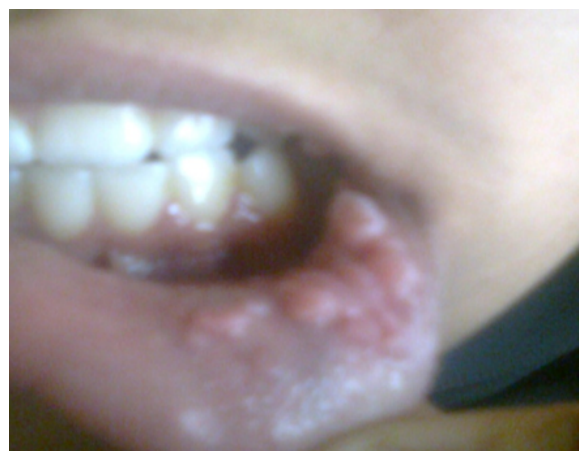

Figure 2: Multiple normal colored, (0.2-4mm) nodules scattered on lip mucosa.

Discussion

Focal epithelial hyperplasia (FEH) is a benign rare pathology that usually affects labial, buccal, tongue mucosa and gingiva of children ^(9,11) younger adults ⁽¹⁷⁾ and more unusually the elderly ⁽¹⁸⁾. FEH is caused by human papilloma virus subtype 13 or 32 ^(19,20). Lesions may persist for several months ^(9,16) or years ^(8,10,11,17) without change but finally, in most of the cases, self-regression takes place especially in children ⁽⁹⁾.

Examination of our young patients showed no systemic abnormalities, and their intraoral lesions had no inflammation or pustular processes which helped us to exclude other similar pathologies as follow: First; Crohn's disease that includes bowel inflammatory disorder, oral aphthae like ulceration, oral nodules and fissures. Second; Cowden's syndrome that includes multiple systemic and oral fibromas, papillomas in older ages. Third; Pyostomatitis vegetans that includes bowel involvement, recurrent pustulated nodules that affect lips, gingiva and palatal tissues, and affecting older ages (4th-6th decades). Fourth; Verruca vulgaris which appears mostly on skin

and in the mouth it is white keratotic with verrucal surface. Fifth; Squamous cell papilloma is exophytic papillary lesions with irregular surface projections. Usually other similar conditions like verruciform xanthoma, keratoacanthoma, pseudoepitheliomatous hyperplasia and child abuse lesions can be easily differentiated from FEH clinically ⁽¹⁾. Therefore, these lesions were biopsied for histopathological examination but unfortunately new advance technique for intracellular viral identification were not available in Ibb city, therefore cases were diagnosed clinically as FEH since the clinical pattern of the presented cases fulfill the criteria of the literature's described entities. FEH has a wide range of frequency from one geographic region to another (from 0.002 to 35%) ^(10,11).

To our knowledge these are the first three cases reported in Yemen .We had three cases from three different places; the first and third one assure that the disease is contagious and communicable. Moreover, the patients were of low socio-economical levels, and living in an economically poor population with deficient medical care and limited access to the health system, support the theory that a viral infection is the etiological agent. While the second case showed no affected members in her family although she got the lesions for two years and with no change leading us to what Stiefler RE, Solomon MP, Shalita AR. stated that 'the etiology of the condition remains controversial'.

The treatment, depending on number and distribution of the lesion, can be clinical or surgical, allowing clinical cure, because the virus remains in the epithelium of the mucosa even after the treatment ⁽²⁾. Therefore we suggest no medical treatment but assurance, good general & oral hygiene measures, good nutrition, regular recall and follow up.

Conclusion

FEH is an uncommon and unknown condition in Yemen, which should be included in the differential diagnosis for oral lesions; particularly that caused by HPV. As then is an Increase in immigration to Yemen from other countries. It is now more likely for physicians to encounter this condition in Yemen. The course of FEH is benign but these patients must be followed up.

References

1. Regezi JA and Sciubba JJ. *Oral pathology: clinical pathologic correlations*. 3rd ed. 1999. Philadelphia. Sanders Company. p:167
2. Castro TH, Neto CE, Scala KA, Scala WA. *Oral Manifestations related to HPV*. *Brazilian J Otorhinolaryngology*. 2004;70:546 -550.
3. Witkop CJ, Niswander JD. *Focal epithelial hyperplasia in Central and South American Indians and Ladinos*. *Oral Surg Oral Med Oral Pathol*. 1965;20:213-7.
4. Archard HO, Heck JW, Stanley HR. *Focal epithelial hyperplasia: An unusual oral mucosal lesion found in Indian children*. *Oral Surg Oral Med Oral Pathol*. 1965; 20: 201-12.
5. Periman A and Uthman A. *focal epithelial hyperplasia, report of seven cases from Iraq*. *Oral Surg Oral Med Oral Pathol*. 1971;31:221-5.
6. El-Khashab MM and Abd-El-Aziz AM. *Focal epithelial hyperplasia (Heck's disease)* *Oral Surg Oral Med Oral Pathol*. 1971;31:637-64.
7. Buchner A. *Focal epithelial hyperplasia in an Israeli family of Libyan origin*. *Oral Surg Oral Med Oral Pathol*. 1978;46:64-69.
8. Alijandro A, Gilberto M. John F.N. *Focal epithelial hyperplasia*. *Oral Surg Oral Med Oral Pathol*. 1981;51:524-6.
9. Ledesma-Montes C, Vega-Memije E, Garcés-Ortiz M, Cardiel-Nieves M, Juárez-Luna C. *Multifocal epithelial hyperplasia. Report of nine cases*. *Med Oral Patol Oral Cir Bucal*. 2005;10:394-401.
10. Omar M, Muhammad A, Randhawa A. *Case Report: Oral Focal Epithelial Hyperplasia (Heck's Disease)*. *JAMC*. 2009; Vol. 20, No. 1.
11. Hashemipour MA, Shoryabi A, Adhami S, Mehrabizadeh Honarmand H. *Extensive focal epithelial hyperplasia*. *Arch Iran Med*. 2010;13:48-52.
12. VanWyk CW. *Focal epithelial hyperplasia of the mouth: recently discovered in South Africa*. *British Journal of Dermatology*. 1977;96:381-8.
13. Tyldesby WR, Field EA. *Oral medicine*. 4th ed. Liverpool. Oxford Medical Publication; 1995.p.99.
14. Borborema-Santos CM, Castro MM, Santos PJ, Talhari S, Astolfi-Filho S. *Oral focal epithelial hyperplasia: report of five cases*. *Braz Dent J*. 2006;17:79 – 82.
15. Bodokh I, Lacour JP, Rainero C, Orth G, Perrin C, Hoffman P, Santini J, Ortonne JP. *[Focal epithelial hyperplasia. An unusual clinical aspect]*. *Ann Dermatol Vénereol*. 1993;120:555-7.
16. Silverman, Eversole, Truelove. *Essentials of oral medicine*. London. BC Decker; 2001.P.150.
17. Morrow DJ, Sandhu HS, Daley TD. *Focal epithelial hyperplasia (Heck's disease) with generalized lesions of the gingiva. A case report*. *J Periodontol*. 1993; 64:63-5.
18. Niebrugge B, Villiers E, Gerlach K, Franke I, Gollnick H. *Demonstration of HPV 24 in long-standing Heck's disease with malignant transformation*. *Eur J Dermatol*. 1999;9:477-9.
19. Stiefler RE, Solomon MP, Shalita AR. *Heck's disease (focal epithelial hyperplasia)*. *J Am Acad Dermatol*. 1979; 1:499-502.
20. Cuberos V, Perez J, Lopez CJ, Castro F, Gonzalez LV, Correa LA, Sanclemente G, Gaviria A, Müller M, Sanchez GI. *Molecular and serological evidence of the epidemiological association of HPV 13 with focal epithelial hyperplasia: A case-control study*. *Journal of Clinical Virology*. 2006;37:21-6.