

THE PROTECTIVE ROLE OF CALCIUM CHLORIDE AND VITAMIN C FOR THYROID FUNCTION IN ADULT MALE RATS EXPOSED TO SODIUM FLUORIDE

*Sumayah Faruq Kasim, **Jassim M. A. Alkalby

* Department of Anaesthesia, College of health and Medical Technology,
Middle Technical University, Baghdad, Iraq.

** Department of Physiology, Pharmacology and Chemistry, College of
Veterinary Medicine, University of Basrah, Basrah, Iraq.

(Received 14 November 2017, Accepted 28 November 2017)

keywords: calcium chloride, vitamin C , thyroid

Corresponding author E.mail: jassimmohammed604@gmail.com.

ABSTRACT

This study was carried out to investigate the role of both calcium chloride and Vitamin C in protection against the deterioration effect of sodium fluoride (NaF) exposure on thyroid function .Fifty adult male rats were used, which divided randomly into five equal groups, the first group: The animals of this group served as control group administrated distilled water orally by gavage. Second group: administrated NaF (5.2mg/kg.bw/day) orally by gavage. Third group: administrated NaF (5.2mg/kg.bw/day) + Calcium Chloride (20mg/kg.bw/day) orally by gavage. Fourth group: administrated NaF (5.2mg/kg.bw/day) + Vitamin C (100mg/kg.bw/day) orally by gavage. Fifth group: administrated NaF (5.2mg/kg.bw/day) + Calcium Chloride (20mg/kg.bw/day) + Vitamin C (100mg/kg.bw/day) orally by gavage . The treatment continued for 45 days. At the end of the experiment, animals were sacrificed under anesthesia. Blood samples were taken and the serum was separated for the study of the thyroid hormones, and tissue samples of the thyroid gland were taken for histological changes. The study showed a significant elevation in thyroid stimulation hormone (TSH), and a significant reduction in tri-iodothyronine (T3) and thyroxin (T4) hormones

concentration in NaF treated group compared with control, however a significant improvement were recorded in above cited parameters in all treated groups. Histopathological study revealed hyperplasia include presence of large number of small follicles in NaF treated group whereas a significant amelioration were found in all other treated groups which appeared semi-normal compared with control group.

INTRODUCTION

Thyroid hormones are essential for the development, growth and reproduction of all cells of the body with metabolic activity (1). The thyroid gland consists of circular follicles of varying sizes and lined with a single row of epithelial cells that surround a cavity filled with colloid material. The size and shape of these follicles depends largely on thyroid activity (2). Chemicals circulating in the environment may affect the endocrine glands and inhibit or alter their functions, such substances are called endocrine disruptors (3). There is still a need to investigate the effect of many environmental contaminants on the thyroid axis remains in order to gain a clear understanding of how these compounds interfere with thyroid function. Fluoride inhibits the synthesis and secretion of thyroid hormones as it interferes with the activity of the enzyme that stimulates the conversion of thyroxin(T4) into active thyroid hormone(T3) (4; 5). The increased consumption of fluoride in food leads to thyroid enlargement and causes structural and functional changes (6).

The thyroid tissue appears to be one of the most sensitive to fluoride, as the increased fluoride intake increases the concentration of thyroid stimulating hormone and decreases the concentration of thyroxine and triiodothyronin, thus leading to hypothyroidism, as observed in populations consuming water containing a high concentration of fluoride for a long time which may cause the inhibition of both thyroid function and brain (7). This study aimed to investigate the protective effect of calcium chloride, vitamin c and their combination on thyroid function in adult male rats exposed to sodium fluoride.

MATERIALS AND METHODS

Animals

The experiment was done at the animal house of the Faculty of Veterinary Medicine/ University of Basrah, Iraq. At the beginning of the study, the rats were housed in plastic cages with metal covers measuring (15×35×50), containing bedding of fine wood which was changed twice per week. They were kept three weeks without any treatment for an adaptation period before the onset of the experiment.

The animals were maintained under controlled environment, light dark cycle (12/12) hours, at a temperature (21±3) C°. Food and water were supplied *ad libitum* with tap water and fed with standard commercial rat chow.

Experimental Design

Fifty male rats were divided randomly into five equal groups as the following: First group: The animals of this group were given distilled water orally by gavage and served as control. Second group: The animals of this group were given Sodium Fluoride (1/10 of LD50) (5.2mg/kg.bw/day) orally by gavage. Third group: The animals of this group were given Sodium Fluoride (5.2mg/kg.bw/day) + Calcium Chloride in a dose of 20mg/kg.bw/day orally by gavage. Fourth group: The animals of this group were given Sodium Fluoride (5.2mg/kg.bw/day) + Vitamin C in a dose of 100mg/kg.bw/day orally by gavage. Fifth group: The animals of this group were given Sodium Fluoride (5.2mg/kg.bw/day) + Calcium Chloride in a dose of 20mg/kg.bw/day + Vitamin C in a dose of 100mg/kg.bw/day orally by gavage. The experiment was continued for 45 days. At the end of the experiment the animals were anaesthetized by putting them in a closed container containing cotton soaked with chloroform. Once the rats were anaesthetized, blood samples were collected between 9.00 to 11.00 A.M in order to minimize the diurnal variation of hormones level directly by heart puncture using a disposable syringes of 5 ml capacity. The collected blood was poured into test tubes free from anticoagulant and centrifuged at 3000 rpm for 15 minutes.

Serum samples were collected after centrifugation and kept in Eppendorf tubes and stored at -20 C° until using for thyroid hormonal analysis. Moreover thyroid

gland have been removed, and kept in 10% formal saline for histological examination.

Hormonal assay:

T₃ and T₄ concentrations were assayed by using ELISA kits from Monobind Inc.lake forest CA 92630; USA, Product code : 125-300. TSH also was measured by using ELISA kit from (Calbiotech Inc. a life science company, USA), Product Code: TS227T.

Histopathological study:

Samples of the thyroid gland were taken and fixed in 10% formalin and then embedded in paraffin and sectioned at thickness of 6 micrometers and then carried on glass slides. It was stained with hematoxyline-eosin and was examined under a light microscope (8).

RESULTS

The table (1) shows that there was a significant ($P\leq 0.05$) increase in serum TSH concentration of the NaF treated group as compared with the control group, while there were significant ($P\leq 0.05$) decrease in serum TSH concentration of the NaF + CaCl₂, NaF + vitamin C and NaF + CaCl₂ + Vitamin C treated groups as compared with the NaF treated group.

The treatment with NaF + Vitamin C was able to brought TSH serum concentration to normal limits with no significant differences as compared to the control group. On the other hand, a significant ($P\leq 0.05$) decrease in serum T3 concentration was observed in NaF treated group as compared with the control group. While both NaF + vitamin C and NaF + CaCl₂ + Vitamin C treated groups were showed significant ($P\leq 0.05$) increase in serum T3 concentration compared to NaF treated group. Also there were no significant differences observed in serum T3 concentration in both of NaF + vitamin C and NaF + CaCl₂ + vitamin C treated groups compared to the control group.

Moreover, a significant ($P\leq 0.05$) decrease in serum concentration of T4 was recorded in NaF treated group as compared to the control group, While treatment with NaF + CaCl₂, NaF + vitamin C and NaF + CaCl₂ + Vitamin C treated groups were resulted in a significant ($P\leq 0.05$) increase in serum T4 serum concentration as compared with the NaF treated group. Finally, no significant differences were

observed in serum T4 concentrations in NaF + vitamin C compared to the control group.

Table (1). Effect of CaCl₂, Vitamin C, and their Combination on Serum Concentrations of TSH, T₃ and T₄ of Adult Male Rats Treated with NaF (M±SD) (n=10).

Parameters Groups	TSH μIU/ml	T ₃ ng/ml	T ₄ μg/dl
Control	0.10 ± 0.01 d	2.17 ± 0.20 a	4.81 ± 0.49 a
NaF	0.25 ± 0.03 a	1.83 ± 0.10 c	3.33 ± 0.33 c
NaF + CaCl ₂	0.18 ± 0.02 b	1.98 ± 0.21 bc	4.22 ± 0.42 b
NaF + Vit. C	0.11 ± 0.01 cd	2.16 ± 0.13 a	4.74 ± 0.32 a
NaF + CaCl ₂ + Vit. C	0.13 ± 0.01 c	2.04 ± 0.11 ab	4.39 ± 0.40 ab
LSD	0.02	0.17	0.43

The different letters refer to significant differences among groups at level of (p≤0.05).

Thyroid histopathological examination

As shown in Figure (1), the thyroid gland of control rats were appeared normal architecture consisting of normal follicles of different sizes lined by single layer of epithelial cells and filled with homogenized colloid surrounded by normal parafollicular cells. On the other hand, the thyroid gland of NaF treated rats showed a histopathological changes including an increase in the number of small follicles as shown in Figure (2), Whereas the thyroid gland of NaF + CaCl₂ treated rats showed the presence of small follicles mostly in the center as shown in Figure (3). Moreover histologically, thyroid section of rats treated with NaF + Vitamin C showed normal follicles filled with colloid as shown in Figure (4).

Finally, the thyroid gland of rats group treated with (NaF + CaCl₂ + Vitamin C) showed returning of thyroid nearly to its normal function and appearance, the gland consists mostly of follicles filled with colloid, and parafollicle cells as shown in Figure (5).

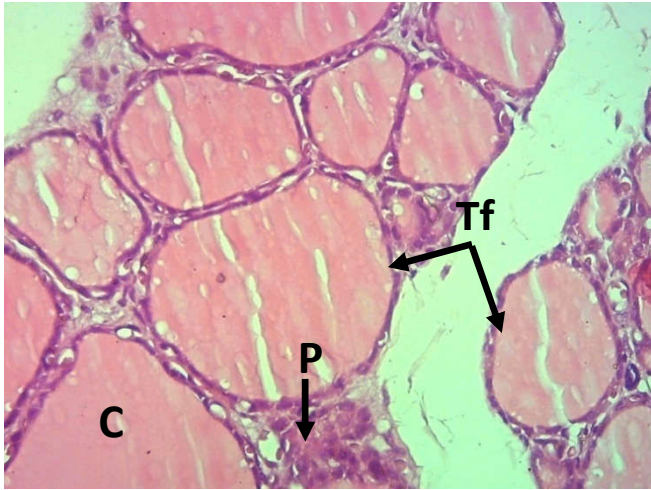


Fig. 4-1: Thyroid of control rat. Showing normal architecture of different sizes thyroid follicle (Tf) filled with homogenized colloid (C) surrounded by normal parafollicular cells (P). (Hematoxylin-Eosin stain) 40X.

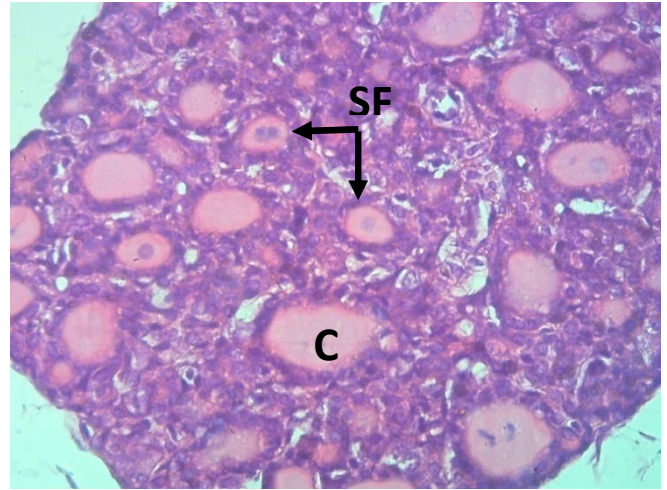


Fig. 4-2: Thyroid of rat treated with NaF. Showing small follicles (SF), which indicating proliferation of thyroid follicles. (Hematoxylin-Eosin stain) 40X.

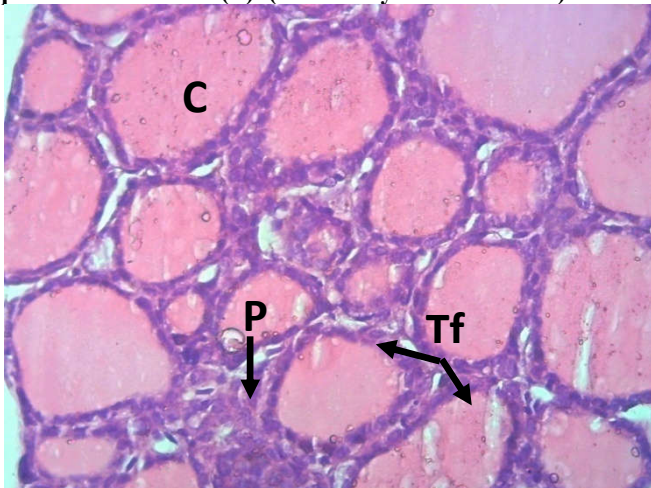


Fig. 4-3: Thyroid of rat treated with NaF + CaCl₂. showing normal architecture of different sizes of thyroid follicle (TF) filled with homogenized colloid (C) surrounded by normal parafollicular cells (P). (Hematoxylin-Eosin stain) 40X.

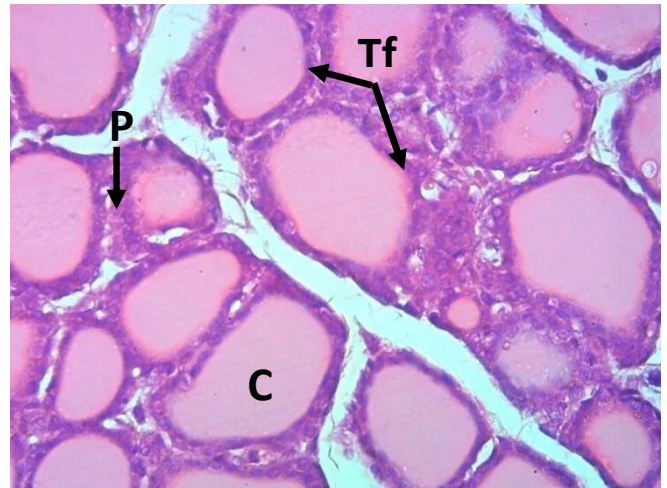


Fig. 4-4: Thyroid of rat treated with NaF + Vitamin C. showing normal thyroid follicles filled with homogenized colloid (C), surrounded by normal parafollicular cells (P). (Hematoxylin-Eosin stain) 40X.

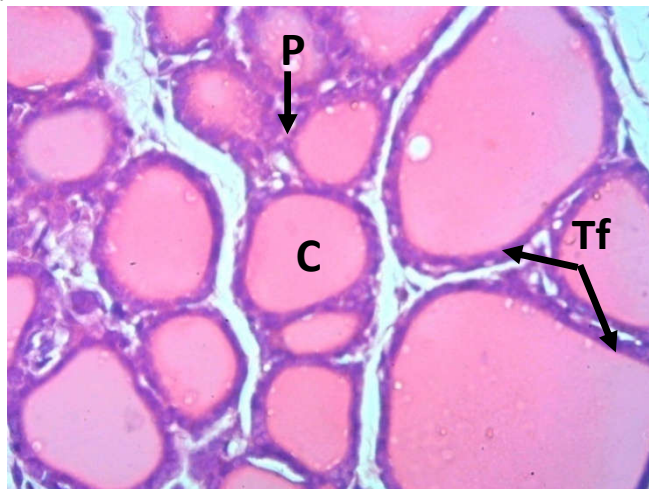


Fig. 4-5: Thyroid of rat treated with NaF + CaCl₂ + Vitamin C. Showing normal thyroid follicles (Tf) filled with homogenized colloid (C). (Hematoxylin-Eosin stain) 40X.

DISCUSSION

Table (1) of the present study showed that there were significant increase in the serum TSH and a significant decrease in T₃ and T₄ concentrations of the NaF treated group as compared with the control group. These results are consistent with (9) and (10) who reported that fluoride exposure` is clearly associated with reduction in T₃ and T₄ hormones .Our results are parallel to those mentioned by (7) who demonstrated that high F increases the concentration of TSH and decreases the concentration of T₃ and T₄ hormones. The present results are also in line with those of (11) who found that rats treated with different doses of fluoride (15, 30, and 60 ppm) resulted in a significant reduction of T₃ and T₄ concentrations, however no significant differences were observed in TSH concentration among any groups compared with control.

The significant increase in the concentration of the hormone TSH in the present study may be an attempt by the body to stimulate the thyroid gland to increase the synthesis and secretion of T₄ hormone to compensate the deficiency in the level of thyroid hormones. While the significant decrease in T₄ concentration may be due to histopathological changes in thyroid tissue due to the oxidative stress induced by fluoride as seen in figure (2). Moreover the significant decrease in the concentration of T₃ hormone may attribute to the reduction in the activity of 5' deiodinase enzymes which is responsible for conversion of T₄ to T₃ which is more biologically active hormone in peripheral tissues.

It is found that thyroid gland has a strong capacity for absorbing and accumulating fluoride. Fluoride disturbs the synthesis and secretion of thyroid hormone, interferes with the activity of enzymes that catalyze the conversion of thyroxin into the active thyroid hormone (T₃) leading to perturbation of circulating thyroid hormone (12). It has been observed that fluorine exposure inhibits both thyroid Na/KTPase and peroxidase enzyme (13). Fluoride is considered to interfere with thyroid hormone levels mainly through three mechanisms: impairing normal structures of the thyroid gland, disrupting iodine metabolism in thyroid glands, and interfering with tissue-specific metabolism of thyroid hormones (14). Iodine is essential in the biosynthesis of thyroid hormones .Therefore, any factor that

influences the uptake, transport, and metabolism of iodine will affect the normal biosynthesis and utilization of thyroid hormones (14).

Moreover, the present study also indicated the amelioration effect of co-administration of CaCl₂ and Vitamin C alone or both together against the negative effect of sodium fluoride on serum concentrations of TSH, T₃ and T₄. The co-administration of calcium with NaF resulted in mild improvement in thyroid hormones concentration which may attribute to a chelating agent of calcium for fluoride results in formation of calcium-fluoride complex and therefore reduces fluoride toxicity (15).

Vitamin C has the ability to protect the thyroid cells from oxidative damage resulting from the effect of NaF and thus helps to maintain the synthesis of thyroid hormones and vitamin C also considered as a source of energy activating different types of enzymes. The co-administration of both CaCl₂ + vitamin C with NaF showed a significant improvement in thyroid hormones levels compared with control. These results are similar to those recorded by (16) who recorded that a significant improvement were observed in skeletal, clinical and biochemical parameters in children consuming water containing 4.5 ppm fluoride when treated with vitamins C, D and calcium.

Microscopic findings of the present study on the thyroid gland of NaF treated rats were mainly presence of microfollicles which were characterized by high cellularity and very small lumen, and concentrated mainly in the center of the gland, which mostly associated with thyroid activation due to reduction in T₃, and T₄ levels, and the above changes quite often associated with an elevation in TSH level. There was no evidence of reduced colloid or changes in the epithelial linings of thyroid follicles as mentioned by (6); (9); (17). A proliferation of microfollicles mainly in the center of thyroid gland of NaF + CaCl₂ treated group is indicated the continuous activation of thyroid gland in response to the hormonal reduction of T₃, and T₄ levels that associated with an elevation of TSH.

In NaF treated animals co-administered with calcium chloride (NaF in a dose of 10mg/kg bw/day followed by calcium chloride in a dose of 20mg/kg bw/day once daily for the same period (35 days) 4 hours after NaF treatment), the follicles were

lined by cuboidal cells and most of them contained colloid when examined by light microscopy (4).

Thyroid section of NaF + Vitamin C treated group in the present study Figure (4) showed normal follicles filled with colloid, and complete recovery of thyroid hormones, in which T₃, T₄ levels returned to normal without increase in TSH level. Also, in NaF + CaCl₂ + Vitamin C treated group figure (3), the gland consists mostly of follicles filled with colloid, and there was no evidence of the presence of small follicles , this refers to returning of thyroid nearly to its normal function and appearance.

CONCLUSION

Exposure of adult male rats to NaF resulted in significant changes in the thyroid hormone levels accompanied with histopathological changes in thyroid gland. On the other hand co-administration of calcium, Vitamin C, each alone or both together reduce to some extent of these changes.

الدور الوقائي لكلوريد الكالسيوم وفيتامين C لوظيفة الغدة الدرقية في ذكور الجرذان البالغة المعرضة لفلوريد الصوديوم

*سمية فاروق قاسم , **جاسم محمد أحمد الكلي

*الجامعة التقنية الوسطى،كلية التقنيات الصحية والطبية، بغداد، العراق.

**جامعة البصرة،كلية الطب البيطري،فرع الفلسجة والأدوية والكيمياء ،البصرة ، العراق.

الخلاصة

أجريت الدراسة الحالية في البيت الحيواني العائد لكلية الطب البيطري / جامعة البصرة لتقييم دور كلوريد الكالسيوم وفيتامين C كل واحد منهما لوحده أو كليهما معا في التغيرات الوظيفية والنسجية للغدة الدرقية في ذكور الجرذان المعرضة لفلوريد الصوديوم (NaF). أستخدم خمسون من ذكور الجرذان البالغة في هذه الدراسة قسمت عشوائيا إلى خمس مجموعات متساوية على النحو الآتي: المجموعة الأولى (مجموعة السيطرة): جرعت حيوانات هذه المجموعة ماء مقطر عن طريق الفم . المجموعة الثانية: أعطيت حيوانات هذه المجموعة فلوريد الصوديوم (5.2mg / kg.bw/day) عن طريق الفم بوساطة مجرعة. المجموعة الثالثة: أعطيت حيوانات هذه المجموعة فلوريد الصوديوم (5.2mg / kg.bw/day + كلوريد الكالسيوم (mg / 20 kg.bw/day) عن طريق الفم. المجموعة الرابعة: أعطيت حيوانات هذه المجموعة فلوريد الصوديوم

المجموعة (Vitamin C (100mg / kg.bw/ + (5.2mg / kg.bw/day) عن طريق الفم. المجموعة الخامسة: أعطيت حيوانات هذه المجموعة فلوريد الصوديوم (5.2mg/kgbw/day) + كلوريد الكالسيوم (20mg/kg.bw/day + فيتامين C (100mg/kg.bw/day) عن طريق الفم. استمرت التجربة لمدة ٤٥ يوما وفي نهاية التجربة، تم التضحية بحيوانات الدراسة تحت التخدير. أخذت عينات الدم وتم فصل المصل لدراسة هرمونات الغدة الدرقية، وأخذت عينات من أنسجة الغدة الدرقية لدراسة التغيرات النسجية وأظهرت الدراسة النتائج الآتية:

لوحظ ارتفاع معنوي في تركيز الهرمون المحفز للدرقية (TSH) وانخفاض معنوي في تركيز كل من هرمون الدرقيين (T₄) و هرمون الثايرونين ثلاثي اليود (T₃) في المجموعة المعاملة بالفلوريد مقارنة مع مجموعة السيطرة، ومع ذلك تم تسجيل تحسن معنوي في المعايير المذكورة أعلاه في جميع المعاملات مقارنة بمجموعة الفلوريد. أشارت نتائج الدراسة النسجية المرضية إلى أن المعاملة بالفلوريد أدت إلى تكوين عدد كبير من الجريبات الصغيرة خصوصا في مركز الغدة الدرقية. فيما أدت المعاملة بكلوريد الكالسيوم وفيتامين C كل منهما لوحده أو كليهما معا إلى بقاء هرمونات الدرقية وتركيبها النسجي ضمن الوضع الطبيعي مقارنة بمجموعة السيطرة.

REFERENCES

1. Zoeller TR, Dowling AL, Herzig CT, Iannacone EA, Gauger KJ and Bansal R. (2002). Thyroid hormone, brain development and the environment. Environmental Health Perspective 110 355-361.
2. Parchami A and Dehkordi RAF (2012). Histological structure of the thyroid gland in duck: A light and electron microscopic study. World Applied Sciences Journal 16(2) 198-201.
3. Colborn T (2002). Clues from wildlife to create an assay for thyroid system disrupters. Environmental Health Perspective 110 363-367.
4. Abdul Rahman M. M. and Fetouh F. A., (2013). Effect Of Sodium Fluoride On The Thyroid Follicular Cells And The Amelioration By Calcium Supplementation In Albino Rats: A Light And An Electron Microscopic Study, Journal of American Science; 9(10):107-114]. (ISSN: 1545-1003).
5. Shashi A and Singla S (2013). Syndrome of low triiodothyronine in chronic fluorosis. International Journal of Basic and Applied Medical Sciences 3(1) 152-160.

6. **Patil V. V. and Dhurvey V. T.,** (2015). Exposure to Sodium Fluoride Affects Thyroid Follicular Cells in Albino Rats. *International Journal of Plant, Animal, and Environmental Sciences*, 5(1): 56-61.
7. **Wang J.; Ge Y.; Ning H.; and Niu R.,** (2009b). DNA Damage in Brain and Thyroid Gland Cells due to High Fluoride and Low Iodine. In: Preedy V, Burrow G, Watson R, editors. *Comprehensive Handbook of Iodine*. Elsevier; p. 643-649.
8. **Luna L. G.,** (1968). *Manual of histological staining methods of the armed forces institute of pathology*. 3rd edition. New York, Mcgraw-Hill.
9. **Wang H.; Yang Z.; Zhou B.; Gao H.; Yan X.; and Wang J.,** (2009a). Fluoride-induced thyroid dysfunction in rats: roles of dietary protein and calcium level. *Toxicol Ind Health*; 25(1):49-57.
10. **Sarkar C. and Pal S.,** (2014). Ameliorative Effect of Resveratrol Against Fluoride-Induced Alteration of Thyroid Function in Male Wistar Rats. *Biol Trace Elem Res*, 162(1-3):PP, 278–287
11. **Jiang Y.; Guo X.; and Sun Q.,** (2016). Effects of Excess Fluoride and Iodide on Thyroid Function and Morphology, *Biol Trace Elem Res*. 170(2):382-389.
12. **Cinar A. and Selcuk M.,** (2005). Effects of chronic fluorosis on thyroxin, triiodothyronine, and protein-bound iodine in cows. *Fluoride*;38: 65-68.
13. **Zhan,X., Li,J., Wang,M., Hangzhou, Z.X China**(2006). Effect of fluoride on growth and thyroid function in young pigs. *Fluoride* 39(2): 95–100.
14. **Long H.; Jin Y.; Lin M.; Sun Y.; Zhanga L.; and Clinchb C.,** (2009). Fluoride toxicity in the male reproductive system, Research review, *Fluoride* 42(4)260–276.
15. **Das (Sarkar) S. Maiti R. and Ghosh D.** (2006): Management of fluoride induced testicular disorders by calcium and vitamin- E coadministration in the albino rat. *Reproductive Toxicology*; 22: 606-612.
16. **Gupta,SK; Gupta,RC; Sheth,AK; Gupta,A** (1996). Reversal of fluorosis in children. *Acta Paediatrica Japonica*, 38(5):513-519.
17. **Krishnamoorthy P.; Gowda N.K.S.; Vallesha N.C.; Rajendran D.; Maya G.; Verma S.; and Rahman H.,** (2015). Effect of Subchronic Fluoride Exposure on Immune Status and Histopathology in Rats and its Amelioration. Research report, Bangalore, India , *Fluoride* 48(2)123-130.