

## **AMELIORATIVE EFFECT OF SELENIUM ON REPRODUCTIVE EFFICIENCY IN ADULT MALE RATS WITH THYROID DISTURBANCE**

Muna H. AL-Saeed\* , Ikbal A.H.AL-Rufaei\*\*

\*Department of Physiology, Pharmacology and Chemistry, College of Veterinary Medicine, University of Basrah, Basrah, Iraq.

\*\*Department Biology, College of Science, University of Basrah. Basrah, Iraq.

(Received 29 October 2017 ,Accepted 6 December 2017)

Keywords: Hypothyroidism, (PTU), Selenium.

*Corresponding author E.mail: muna.mahmood@uobasrah.edu.iq*

### **ABSTRACT**

This study was designed to evaluate the ameliorative effect of selenium on reproductive efficiency of adult male rats with thyroid disturbance.

Hypothyroidism state was induced by administration of antithyroid drug propylthiouracil (PTU) (50mg/kg.B.W.) and hyperthyroid state was induced by administration of L-Thyroxine(L-T<sub>4</sub>) (50µg/kg.B.W.). Selenium (Se) treated rat group was given sodium selenite (10 µg/kg.B.W.).

Sixty adult male rats of (180-200 gm) body weight were used in this study and divided into six main groups. Control group, PTU treated group, L-T<sub>4</sub> treated group, Se treated group, Se+PTU treated group and Se+L-T<sub>4</sub> treated group. All these groups were drenched orally by gavage tube for two months.

The obtained results revealed that hypothyroidism is accompanied by significant (P<0.05) decrease in serum T<sub>3</sub>, T<sub>4</sub> concentrations compared with control and another treated groups and significant increase (P<0.05) in hyperthyroidism group a compared with control. On the other hand, TSH concentration showed a significant (P<0.05) increase in hypothyroidism group and significant decrease (P<0.05) in hyperthyroidism group as compared with control and another treated group.

A significant decrease in serum concentrations of FSH, LH and testosterone have been shown in serum of hyper- and hypothyroidism groups.

Semen analysis showed a significant decrease (P≤0.05) of epididymal sperm concentration, sperm motility, and viability and a significant increase (P≤0.05) of sperm

abnormalities were recorded in PTU and L-T<sub>4</sub> groups compared with control and another treated group. While a significant increase ( $P \leq 0.05$ ) of epididymal sperm concentration, sperm motility and viability and a significant decrease ( $P \leq 0.05$ ) of sperm abnormalities were recorded in Se alone, Se+PTU group and Se+L-T<sub>4</sub> group. Also, histological examination on the testis showed that rats treated with Se, Se+PTU and Se+L-T<sub>4</sub> had normal architecture of seminiferous tubules with different stage of spermatogenesis. Whereas, rats treated with L-T<sub>4</sub> alone or with PTU exhibited vacuolation of spermatogonia and suppression of spermatogenesis.

## INTRODUCTION

Thyroid hormone level can severely affect reproductive functions including fertility, pregnancy and postnatal development in human and rat [1]. Thyroid hormones play a critical role in testicular development, testicular function and spermatogenesis[2]. Whereas [3] indicated that thyroid disorder is accompanied with sexual dysfunction and or morphological testicular degeneration.

Abnormal supply of thyroid hormones may trigger alterations in the number of steroli cells and consequently alter testis size and number of sperm leading to reproductive impairment[4].

Messoudi *et al*[5] mentioned that selenium is an important antioxidant element and plays a vital role in testicular development, spermatogenesis and spermatozoa motility and functions. This study aimed to evaluate the ameliorative effect of selenium on reproductive efficiency of adult male rats disturbance thyroid gland.

## MATERIAL AND METHODS

This study was carried out on sixty adult male rats (*Rattus norvegicus*) weighing (180-200gm). There rats were housed in the animal house of College of Veterinary Medicine / University of Basrah.

They housed with meta covers measuring (15× 35×50) and had a bedding of fine wood which was changed twice a week. Rats were housed in these plastic cages with food and drinking *ad libitum* under 20-25°C controlled temperature condition and alternate 12 hours light/dark period.

Animals were divided into six main groups, each of 10 rats. Control group treated with normal saline, second group treated with 50 mg/Kg B.W. of PTU dissolve in 1ml of normal saline, third group treated with 50 µg/Kg B.W. of L-T<sub>4</sub> dissolve in 1ml of normal saline , fourth group treated with 10 µg/Kg B.W. of sodium selenite dissolve in 1ml of normal saline, fifth group treated with both PTU+Se, and the sixth group treated with both L-T<sub>4</sub> +Se.

All these were drenched orally by using gastric tube for two months. At the end of the treatment period, rats were euthanized by chloroform and sacrificed, and testis and epididymis were removed. The tail of epididymis was kept in concave watch glass contain 5 ml of normal saline to be used for semen analysis. Epididymal sperm were counted as described by [6]. The individual epididymal sperm motility was then estimated as described by [7]. Massive epididymal sperm motility was measured. Abnormal and dead sperms percentage were then recorded in the stained slide by eosin-nigrosin stain as described by[6].

#### **Histological study.**

After removing the testes, the testes were immediately fixed in Bouin's fluid for 12 h and the Bouin's fixative was washed from the samples with 70% alcohol. The tissues were then cut in slabs of about 0.5cm transversely and dehydrated once by passing through different grades of alcohol: 70% alcohol for 2 h, once in 95% alcohol for 2 h, once in 100% alcohol for 2 h, once in 100% alcohol for 2 hours and finally 100% alcohol for 2 hours. The tissues were then dipping in xylene for 6 h. The tissues were then filtrated in molten Paraffin wax for 2 h at 57°C in an oven. Serial sections were cut using rotary microtone at 5 microns (5µm). The satisfactory ribbons were picked up from a water bath (50 -55°C) with microscope slides that had been coated on one side with egg albumin as an adhesive and the slides were dried in an oven. Each section was deparaffinized in xylene for 1minute before immersed in absolute alcohol for 1 minute and later in descending grades of alcohol for about 30seconds each to hydrate it. The slides were then rinsed in water and immersed in alcoholic solution of hematoxylin for about 18 min. After that, the slides rinsed in water, differentiated in 1% acid alcohol, put inside a running tap water to blue, counterstained in alcoholic eosin for 30 seconds and rinsed in water for a few seconds, and then immersed once in 70%, once in 90% and

twice in absolute alcohol for 30 seconds each to dehydrate the preparations. The preparations were cleared of alcohol by dipping them in xylene for 1 minute. Each slide was then cleaned, blotted and mounted with DPX and cover slip, and examined under the microscope. Photomicrographs were taken at 40X, 100X, and 400X magnifications [8,9].

### **Statistical Analysis**

was performed by one-way covariance (ANOVA) test. Using SPSS (statistical packages for the social sciences) program V. 21.

## **RESULT**

### **-Effect of PTU, L-Thyroxine, Selenium alone, Co-Treatment with PTU+Se and L-T<sub>4</sub>+Se on Physical Properties of Semen Analysis in Male Rats:**

The current study in Table (1) revealed a significant increase ( $P \leq 0.05$ ) in semen volume, mass activities, sperm concentration, total sperm and live sperm of male treated with Se alone compared to control group and another treated groups. However significant decrease ( $P \leq 0.05$ ) were noted in semen volume, mass activities, sperm concentration, total sperm and live sperm of male treated with PTU and L- T<sub>4</sub> compared to control group and another treated groups.

There are a significant decrease ( $P \leq 0.05$ ) in sperm abnormalities of male treated with Se alone compared to control group and another treated groups. However, significant increase ( $P \leq 0.05$ ) were observed in sperm abnormalities of male treated with PTU and L- T<sub>4</sub> compared to control group and another treated groups.

**Table(1):Effect of PTU, L-Thyroxine, Selenium alone, Co-Treatment with PTU+Se and L-T<sub>4</sub>+Se on Physical Properties of Semen Analysis in Male Rats. N= 10**

Groups	Control	PTU	L-thyroxine	Selenium	PTU+Se	L-T <sub>4</sub> +Se
<b>Semen volume(ml)</b>	0.60 ± 0.031 <b>b</b>	0.35±0.0 17 <b>c</b>	0.39±0.013 <b>c</b>	0.90±0.003 <b>a</b>	0.71±0.025 <b>b</b>	0.69±0.018 <b>b</b>
<b>Semen colour</b>	Creamy	yellowish	yellowish	Creamy	Creamy	Creamy
<b>Mass activities</b>	++	----	----	+++++	++++	+++
<b>Sperm motility%</b>	78.15 ±2.31 <b>b</b>	50.89 ± 9.36 <b>c</b>	55.26 ±9.36 <b>c</b>	95.14±7. 41 <b>a</b>	95.35±8.44 <b>a</b>	80.52±11.49 <b>b</b>
<b>Sperm concentration (×10<sup>6</sup>/ml)</b>	6.12 ± 0.24 <b>c</b>	4.20±0.14 <b>d</b>	6.42±0.28 <b>b</b>	9.98 ± 0. 68 <b>a</b>	8.94±0.13 <b>a</b>	7.83±0.56 <b>b</b>
<b>Total sperm cell / ejaculate(×10<sup>6</sup>/ml)</b>	3.74±0.36 <b>c</b>	2.54±0.03 <b>d</b>	3.40±0.005 <b>c</b>	7.98±0.69 <b>a</b>	5.24±0.08 <b>b</b>	4.91±0.03 <b>b</b>
<b>Live-dead sperm ratio</b>	70:30 ±4.89 <b>b</b>	40:60 ±7.49 <b>c</b>	46:54 ±3.87 <b>c</b>	95:5±9.82 <b>a</b>	90: 10±5.63 <b>a</b>	85:15±3.46 <b>ab</b>
<b>Sperm abnormalities</b>	15.69 ±3.7 <b>b</b>	60.76±7.95 <b>a</b>	65.97±8.43 <b>a</b>	6.94 ±0.68 <b>c</b>	14.81±2.86 <b>b</b>	20.94±6.29 <b>b</b>

N=number of animals., small letters denote differences between groups,P≤0.05 vs. control, NS=non-significant.

Results are expressed as mean± SD of the mean of the ten replicates.

#### **-Effect of PTU, L-Thyroxine, Selenium alone, Co-Treatment with PTU+Se and L-T<sub>4</sub>+Se on Sperm morphology:**

**Bent tail:-** The rats in each of the treated groups with PTU and L-T<sub>4</sub> were observed to have significantly (P<0.05) more spermatozoa bent tail abnormality when compared with control rats and Se alone group and combination groups.

**Curved mid-piece and tail:-** Fewer spermatozoa of rats in the control group (P<0.05) had curved tail sperm abnormality than those of the rats in each of the treated groups with PTU and L-T<sub>4</sub>.

**Normal head without tail/tailess head:-** The rats in the control group had lesser number of spermatozoa with normal head without tail abnormality compared with rats in each of the treated groups. The percentage of this abnormality in the rats in treated group

with PTU and L-T<sub>4</sub> was higher than that of the control rats. The differences of the means were significant (P<0.05) for both groups.

**Normal tail without head/headless tail:-** The spermatozoa of rats in each of the treated groups with PTU and L-T<sub>4</sub> were observed to slightly have more of the normal tail without head/ headless tail abnormality than those of the control rats.

**Table (2):-Effect of PTU, L-Thyroxine, Selenium alone, Co-Treatment with PTU+Se and L-T<sub>4</sub>+Se on Sperm morphology. Mean ± SD N= 10**

Groups	Control	PTU	L-T <sub>4</sub>	Selenium	PTU+Se	L-T <sub>4</sub> +Se
<b>Bent tail</b>	3.75 ±0.026 <b>b</b>	8.12±0.05 <b>a</b>	8.23±0.26 <b>a</b>	1.21 ±0.04 <b>c</b>	3.81±0.06 <b>b</b>	4.34±0.019 <b>b</b>
<b>Curved mid-piece and tail</b>	3.40 ± 0.051 <b>b</b>	11.43±0.29 <b>a</b>	9.31±0.04 <b>a</b>	1.73±0.03 <b>c</b>	2.25±0.02 <b>b</b>	3.25±0.07 <b>b</b>
<b>Normal head without tail (Live)</b>	3.28± 0.032 <b>b</b>	10.0±0.61 <b>a</b>	11.32±0.1 <b>a</b>	1.30±0.08 <b>c</b>	2.13±0.05 <b>b</b>	3.15±0.016 <b>b</b>
<b>Tailless head (Dead)</b>	2.87± 0.021 <b>b</b>	11.10±0.27 <b>a</b>	12.11±0.2 <b>a</b>	1.22±0.01 <b>c</b>	3.02±0.01 <b>b</b>	4.10±0.08 <b>b</b>
<b>Normal tail without head (Live)</b>	2.56± 0.09 <b>b</b>	10.06±0.18 <b>a</b>	12.0±0.18 <b>a</b>	1.48±0.02 <b>c</b>	2.30±0.06 <b>b</b>	3.10±0.02 <b>b</b>
<b>Headless tail (Dead)</b>	0.0±0.00	10.05±1.35 <b>a</b>	13.01±0.9 <b>a</b>	0.0±0.0	1.30±0.06 <b>c</b>	3.0±0.021 <b>b</b>

N=number of animals., small letters denote differences between groups,P≤0.05 vs. control, NS= non-significant.

Results are expressed as mean± SD of the mean of the ten replicates.

**-Effect of Propylthiouracil, Thyroxine, Selenium alone, Co-treatment with PTU+Se and L-T<sub>4</sub>+Se on TSH, T<sub>3</sub> and T<sub>4</sub>in Male Rats:**

The obtained results in Table (3) revealed significant decrease (P≤0.05) of T<sub>3</sub>, T<sub>4</sub> in serum of males rats treated with PTU compared with the control group and another treated groups while the results showed significant increase (P≤0.05) TSH in serum of males rats treated with PTU compared with the control group and another treated groups. On another hand the results revealed significant increase (P≤0.05) of T<sub>3</sub>, T<sub>4</sub> in serum of males rats treated with L-T<sub>4</sub> compared with the control group and another treated groups

while the results showed significant decrease ( $P \leq 0.05$ ) TSH in serum of males rats treated with L-T<sub>4</sub> compared with the control group and another treated groups.

**Table (3): Effect of PTU ,L-thyroxine, Selenium alone,Co-treatment with PTU+Se and L-T<sub>4</sub>+Se on TSH, T<sub>3</sub> and T<sub>4</sub> in Male Rats. N=10**

Parameters Treatment	TSH (mIU/ml)	T <sub>3</sub> (mIU/ml)	T <sub>4</sub> (ng/ml)
Control (Normal saline 0.9%NaCl)	2.09 ± 0.016 <b>b</b>	1.48 ± 0.02 <b>ab</b>	11.97 ± 0.27 <b>b</b>
Propylthiouracil	4.45 ± 0.073 <b>a</b>	0.43 ± 0.07 <b>c</b>	6.85 ± 1.46 <b>c</b>
L-Thyroxin Sodium	0.52 ± 0.031 <b>c</b>	2.14 ± 0.028 <b>a</b>	18.74 ± 1.79 <b>a</b>
Sodium Selenite	2.23 ± 0.009 <b>b</b>	1.51 ± 0.073 <b>ab</b>	12.96 ± 2.03 <b>b</b>
Selenium+Propylthiouracil	3.57 ± 0.012 <b>ab</b>	0.98 ± 0.035 <b>b</b>	9.82 ± 1.42 <b>b</b>
Selenium+ Thyroxine	1.69 ± 0.025 <b>b</b>	1.69 ± 0.001 <b>ab</b>	13.73 ± 1.03 <b>b</b>

N=number of animals., small letters denote differences between groups, $P \leq 0.05$  vs. control, NS=non-significant.

Results are expressed as mean ± SD of the mean of the ten replicates

#### **-Effect of PTU, L-thyroxine, Selenium alone, Co-treatment with PTU+Se and L-T<sub>4</sub>+Se on FSH, LH and Testosterone in Male Rats:**

The obtained results in Table (4) revealed significant decrease ( $P \leq 0.05$ ) of FSH, LH, and testosterone in serum of males rats treated with PTU and L-T<sub>4</sub> compared with the control group and another treated groups while the results showed no significant differences in FSH, LH, and testosterone in serum of males rats treated with PTU +Se and L-T<sub>4</sub>+Se compared with the control group and Se group alone.

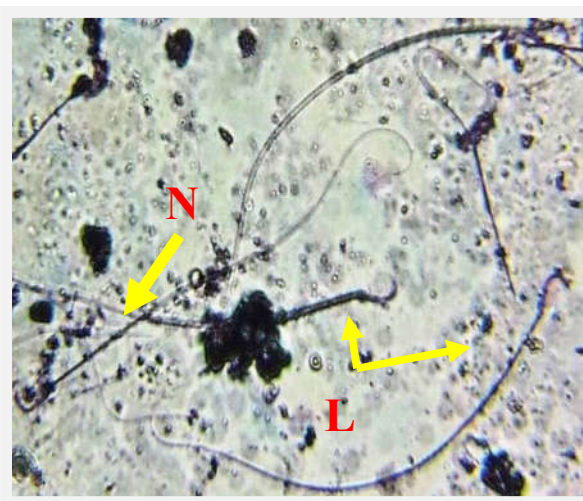


**Table (4): Effect of PTU, L-thyroxine, Selenium alone, Co-treatment with PTU+Se and L-T4+Se on FSH, LH and Testosterone in Male Rats. N=10**

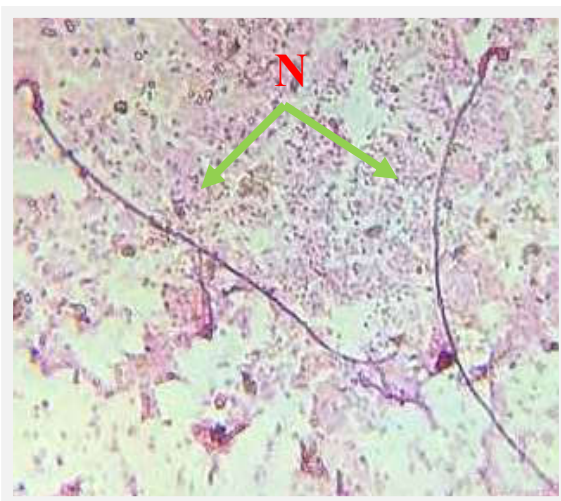Parameters Treatment	FSH (mIU/ml)	LH (mIU/ml)	Testosterone (ng/ml)
Control (Normal saline 0.9%NaCl)	6.53±1.43 <b>a</b>	8.31±2.79 <b>ab</b>	9.27±2.91 <b>a</b>
Propylthiouracil	2.95±0.14 <b>b</b>	4.23±1.83 <b>b</b>	5.73±1.69 <b>b</b>
L-Thyroxin Sodium	3.61±0.52 <b>b</b>	4.09±0.67 <b>b</b>	5.95±1.84 <b>b</b>
Sodium Selenite	6.98±2.09 <b>a</b>	10.67±2.15 <b>a</b>	10.98±2.30 <b>a</b>
Selenium+Propylthiouracil	5.78±1.93 <b>a</b>	7.86±1.93 <b>ab</b>	8.69±2.62 <b>ab</b>
Selenium+ Thyroxine	5.91±1.56 <b>a</b>	7.13±1.01 <b>ab</b>	8.93±0.78 <b>ab</b>

N=number of animals., small letters denote differences between groups,P≤0.05 vs. control, NS=non-significant.

Results are expressed as mean± SD of the mean of the ten replicates

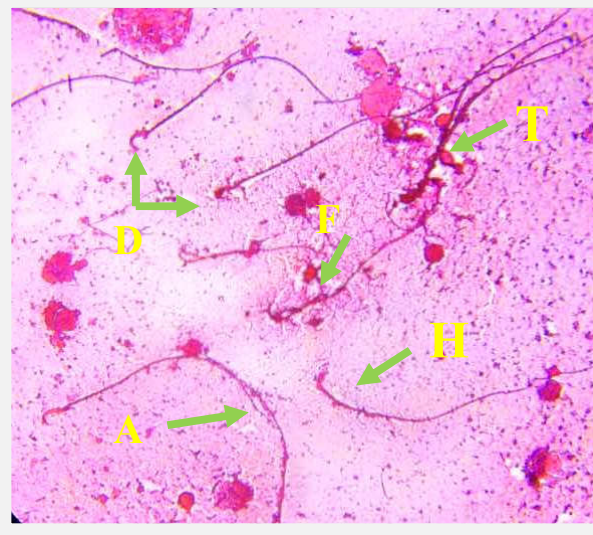


**Fig.( 1):-Sperm of rats (control). Showing normal sperm(N), Live(L), Stain with(N&E) 400X.**

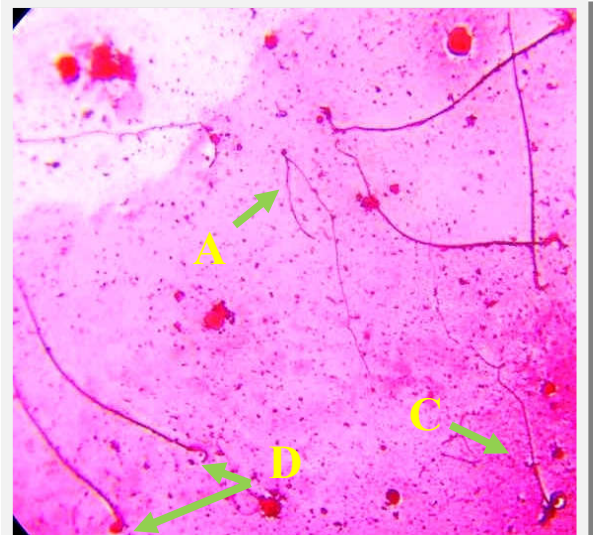


**Fig.( 2):-Sperm of rats treated with Se. Showing normal sperm(N), Live(L), Stain with(N&E) 400X.**

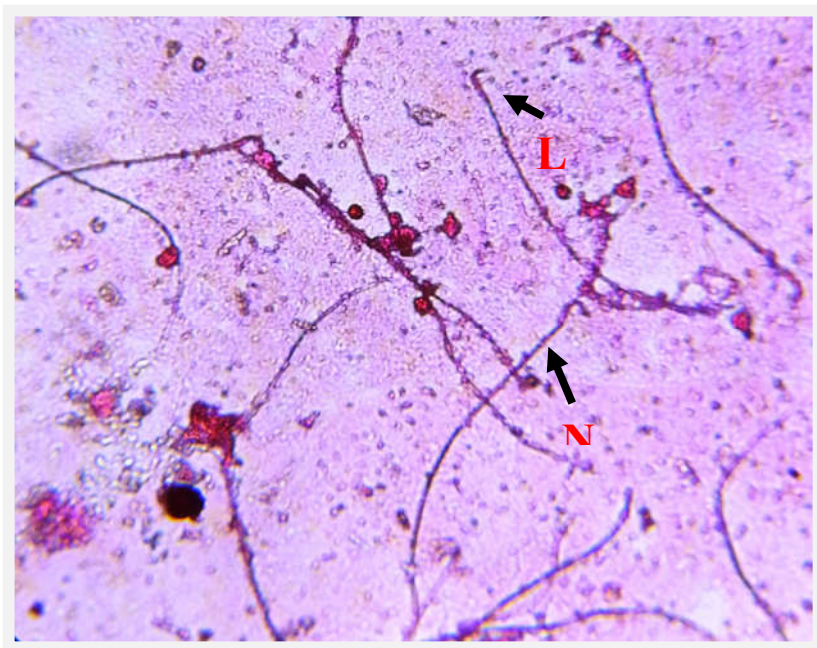




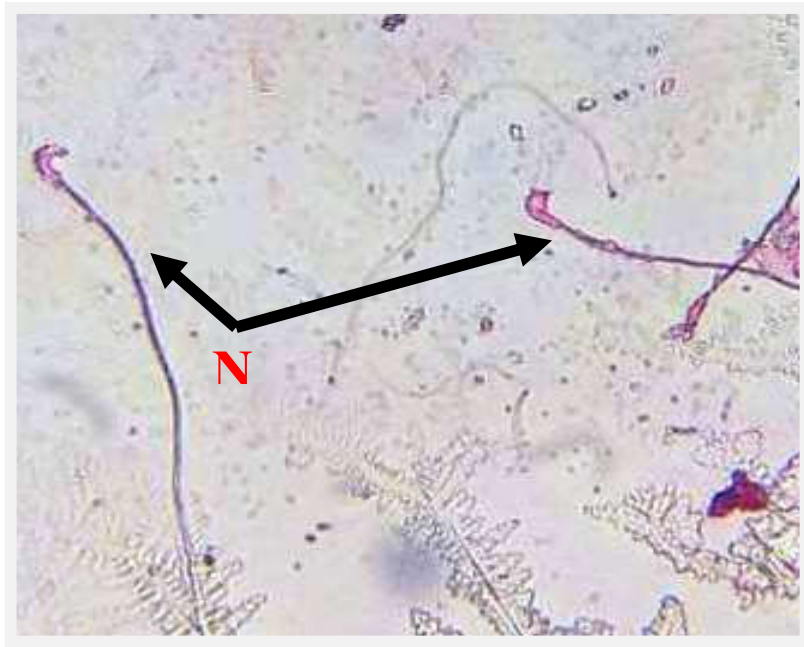
**Fig.(3):-Sperm of rats treated with PTU. Showing abnormal shape sperm(A), most sperms dead (D), some sperm headless, few with big head(B), hookless(H), sperm presented with Double tail(T), some sperm fused(F), Stain with(N&E) 400X.**



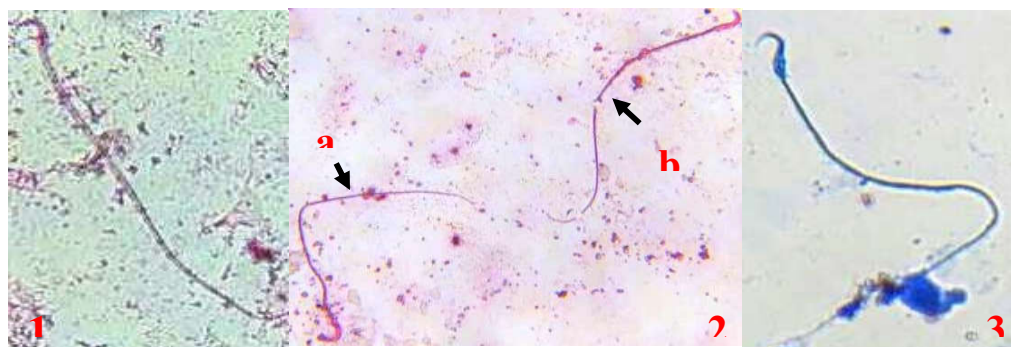
**Fig.(4):-Sperm of rats treated with L-T4. Showing abnormal shape sperm(A), most of the sperms dead (D), some sperm headless, few sperm with coiled tail (C), some sperm with tail only, Stain with(N&E) 400X.**



**Fig.( 5):- Sperm of rats treated with Se + PTU. Showing normal sperm(N), Live(L) Stain with (N &E), 400X.**



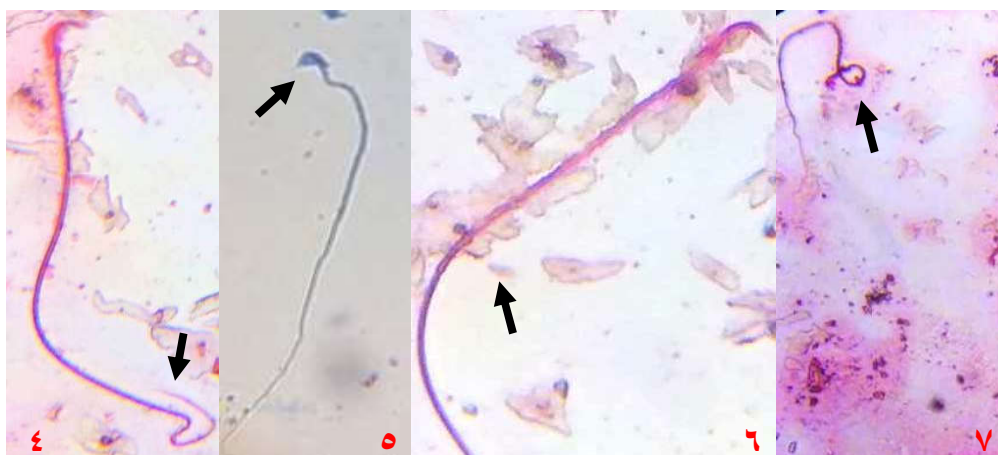**Fig.(6):- Sperm of rats treated with Se+L-T<sub>4</sub>. Showing normal snerm (N). Stain with (N&F).400X.**



**(1) Normal Sperm**

**(2)Abnormal Sperm(Dead )a-  
Amornhous**

**(3)Abnormal Sperm  
(Amornhous)**



**4- Bent Tail**

**5- Hookless**

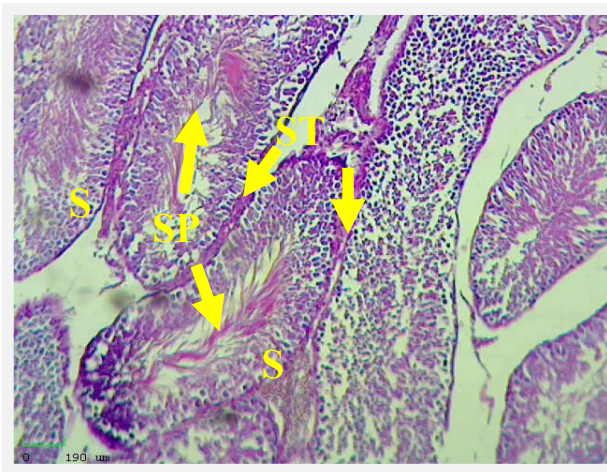
**6- Hummer shape**

**7- Headless**

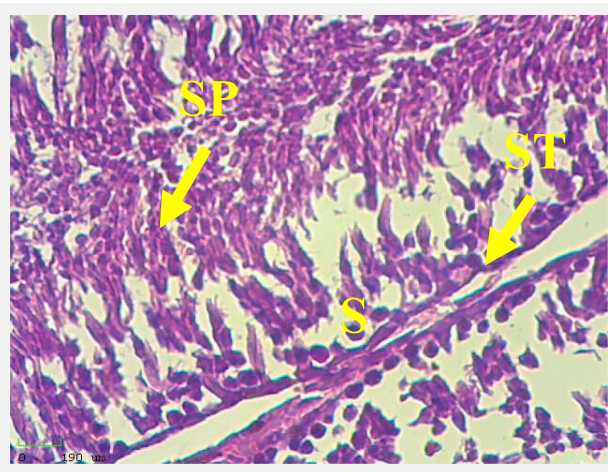


### **-Testes**

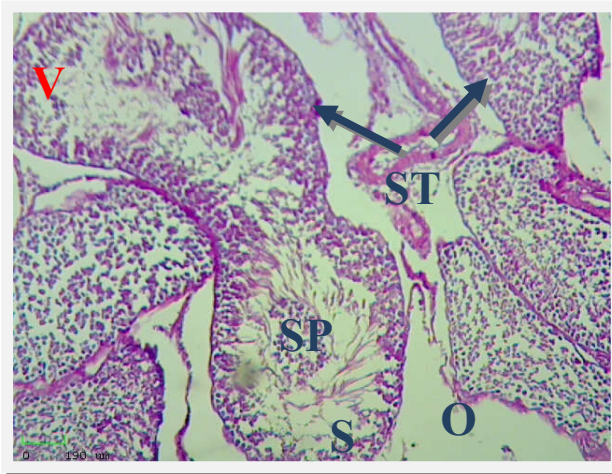Section of testis of control group rats showed normal architecture of seminiferous tubules with different stage of spermatogenesis, primary spermatocyte, and normal sertoli cells as shown in figure (8). Also section of testis of rats treated with Se showed normal architecture of seminiferous tubules with spermatogenesis as shown in Figure (9). While section of testis of rats treated with PTU alone showed vacuolation of spermatogonia and suppression of spermatogenesis, widening of inter seminiferous tubules, arrested of spermatogenesis and decrease in the number of interstitial leydig cells as shown in figure (10). Also section of testis of rats treated with L-T4. Showed suppression of spermatogenesis in seminiferous tubuled and mild vacuolation of spermatogonia as shown in figure(11). But section of testis of rats treated with PTU+Se showed normal seminiferous tubules and spermatogenesis, interstitial leydig cells and present sertoli cells as shown in figure.(12). Also section of testis of rats treated with L-T4+Se, showed normal seminiferous tubules, spermatogenesis, Interstitial leydig cells between seminiferous tubules and present primary spermatocyte as shown in figure.(13).



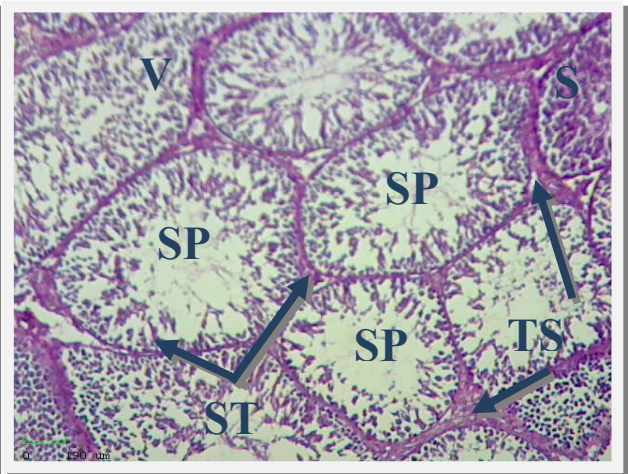
**Fig.(8):-Section of testis of rats (control). Showing normal sertoli cells(S), normal architecture of semeniferous tubules (ST) with different stage of spermatogenesis, normal spermatogonia (SP), stain (H&E) 100X.**



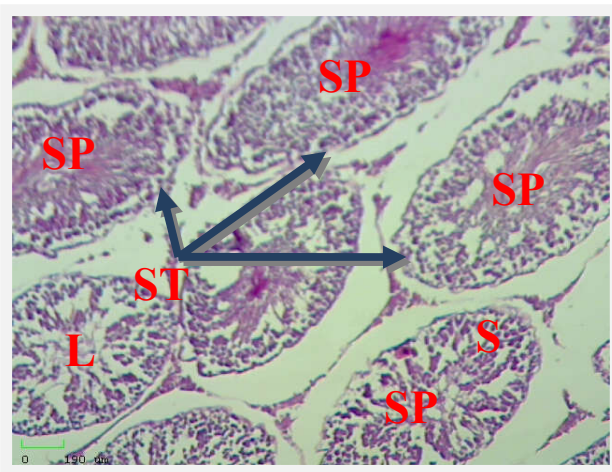
**Fig.(9):- Section of testis of rats treated with Se. Showing normal sertoli cells(S), normal architecture of semeniferous tubules (ST) with different stage of spermatogenesis, normal spermatogonia (SP), stain (H&E) 400X.**



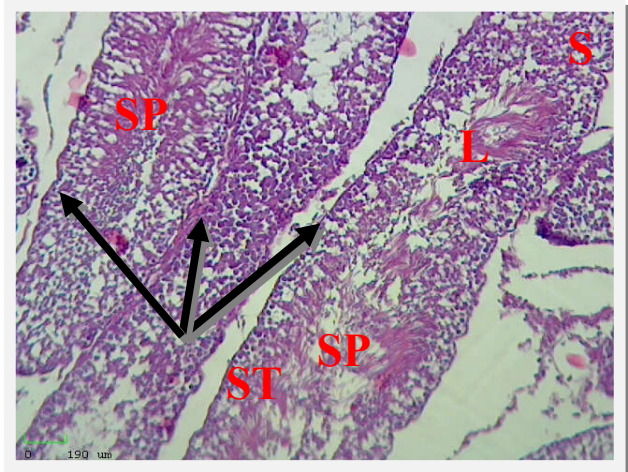
**Fig.( 10):-** Section of testis of rats treated with PTU. Showing vacuolation (V) of spermatogonia and widening of inter seminiferous tubules (ST), decrease in the number of interstitial leydig cells, reduced sertoli cells (S) and oedema (O) in interstitial tissue, stain (H&E) 100X.



**Fig.(11):-**Section of testis of rats treated with L-T<sub>4</sub>. Showing suppression of spermatogenesis (SP) in seminiferous tubuled (ST), mild vacuolation (V) of spermatogonia, reduced sertoli cells (S) and thickened wall of some seminiferous tubules (TS) , stain (H&E) 400X.



**Fig.(12):-**Section of testis of rats treated with PTU+Se. Showing present sertoli cells(S), normal architecture of semeniferous tubules (ST) with spermatogenesis (SP), lumen of semeniferous tubules (L) and present vacuolation in spermatogonia, stain (H&E) 400X.



**Fig.( 13):-**Section of testis of rats treated with L-T<sub>4</sub>+Se. Showing normal sertoli cells (S), normal architecture of semeniferous tubules (ST) with spermatogenesis (SP), lumen of semeniferous tubules(L) and present vacuolation in spermatogonia, stain (H&E) 400X.



## DISCUSSION

The results of this study indicate that the thyroid disturbance affect on reproductive efficiency attributed to thyroid disturbance lead to decrease concentration of Se, LH , FSH and testosterone. Also the results of histological examination of testes indicate the thyroid disturbance affect on reproductive efficiency. This finding is in agreement with previous study [10] , in which the hypothyroidism affect on pituitary-testes axis via its effect on testis. It has been noticed that hypothyroid male albino rats revealed reduction in live sperm percentage and in sperm number in both testis and epididymis[11]. Whereas both testis and epididymis revealed increases in the percentage of dead and abnormal sperms which is similar to our present result. On the other hand, a significant reduction in sperm morphology while other sperm parameters weren't affected in subclinical hypothyroid adult male rats[12].

It has been found that selenium administration decreases sperm abnormalities which induced by several chemical and this finding support our result[5]. In the current study, administration of selenium improved the sexual desire, semen characteristics and serum testosterone levels of rats as compared to the control as well as to the pre- treatment data. These results are in agreement with those of Baiomy *et al.* [17]. The reaction time became obviously shortened with production of good quality semen containing high concentration of normal, motile and alive sperm cell. Selenium has a complementary effect as biological antioxidants, protecting the body against the damage done by the production of free radicals and consequently enhance the general health condition and fertility [18, 19]. Moreover, selenium is involved in the synthesis of prostaglandins [20], improved the performance of immune system and synthesis of testosterone from the testis [18].

The result of the present histological study revealed many pathological changes in testis in hypothyroid and hyperthyroid rats. This finding is in agreement with previous study[13,14] in which the hypothyroidic rats testicles experienced maturation arrest of spermatogenesis, a reduced number of sertoli and leydig cells, interstitial oedema and thickening of basal membrane [14]. It has been found obvious exfoliation of germ cells into seminiferous tubules lumen, germinal epithelium disorganization and an increase in

interstitial space in hyperthyroid rats[13,14]. Previous study[15,16] support our result about histological effect of selenium on testis, whereas [15] noticed that rat testis treated with selenium showed normal seminiferous tubules which are uniform in their size and shape. Both spermatogenic cells and sertoli cells in seminiferous tubules had normal structure. In addition, testicular tissues in selenium treated rats showed seminiferous tubules lined by layers of spermatogenic cells up to sperm formation and these tubules surrounded by thin basement membrane[16].

### التأثير المحسن للسيلينيوم على الكفاءة التناسلية في ذكور الجرذان البالغة المضطربة الغدة الدرقية

\* منى حميد محمود ، \*\* إقبال عبد العزيز حزام

\* فرع الفلسفة والأدوية والكيمياء ، كلية الطب البيطري ، جامعة البصرة، البصرة ، العراق.

\*\* قسم علوم الحياة ، كلية العلوم ، جامعة البصرة، البصرة ، العراق.

### الخلاصة

صممت هذه الدراسة لتقييم التأثير المحسن للسيلينيوم على الكفاءة التناسلية في ذكور الجرذان المضطربة الغدة الدرقية اذ استحثت القصور الدرقي بوساطة اعطاء عقار البروبيل ثيوبوراسيل المضاد للدرقية (٥٠ ملغم/كغم من وزن الجسم) واستحث فرط الدرقي بوساطة اعطاء عقار الثايروكسين (٥٠ مايكروغرام/كغم من وزن الجسم) اما مجموعة السيلينيوم فقد تم اعطاؤها ملح الصوديوم سلينيت (١٠ مايكروغرام/كغم من وزن الجسم).

اجريت هذه الدراسة على ٦٠ من ذكور الجرذان البالغة والتي يتراوح اوزانها ما بين (١٨٠ - ٢٠٠ غم) مقسمة الى ست مجاميع هي: مجموعة السيطرة اذ تم تجريعها المحلول الفسلجي ١ مل ، والمجموعة الثانية معاملة بالبروبيل ثيوبوراسيل (٥٠ ملغم/كغم من وزن الجسم) مذاب في امل من المحلول الفسلجي ، المجموعة الثالثة معاملة الثايروكسين (٥٠ مايكروغرام/كغم من وزن الجسم) مذاب في امل من المحلول الفسلجي ، المجموعة الرابعة معاملة ملح الصوديوم سلينيت (١٠ مايكروغرام/كغم من وزن الجسم) المذاب في امل من المحلول الفسلجي ، المجموعة الخامسة معاملة بالبروبيل ثيوبوراسيل+ ملح الصوديوم سلينيت والمجموعة السادسة معاملة الثايروكسين + ملح الصوديوم سلينيت.

وجميع هذه الجرذان جرعت عن طريق الفم بوساطة التغذية الانبوبية لمدة شهرين.

اظهرت نتائج قياس الهرمونات: انخفاض معنوي ( $p \leq 0.05$ ) تراكيز هرمونات الغدة الدرقية ثلاثي ورباعي اليود لمصل دم الجرذان للمجموعة القصور الدرقي بينما لوحظ ارتفاع معنوي في تركيز الهرمون المحفز للغدة الدرقية في مصل دم الجرذان التي تعاني من القصور الدرقي في حين لوحظ العكس في مصل دم الجرذان للمجموعة الفرط

الدريقي انخفاض معنوي ( $p \leq 0.05$ ) في تركيز الهرمون المحفز للغدة الدرقية في مصلى دم الجرذان وارتفاع معنوي ( $p \leq 0.05$ ) في تركيز هرمونات الغدة الدرقية ثلاثي ورباعي اليود لمصلى دم الجرذان. كذلك انخفضت معنوياً ( $p \leq 0.05$ ) تراكيز هرمونات الغدة النخامية (LH,FSH) وكذلك هرمون التستسترون الخصوي لمصلى دم ذكور الجرذان لمجموعتي القصور وفرط الدريقي. اظهرت نتائج تحليل السائل المنوي : انخفاض معنوي لعدد النطف البربخية وحركة وحيوية الحيوانات المنوية وزيادة معنوية في الحيوانات المشوهة في ذكور الجرذان التي تعاني قصور وفرط الدريقي مقارنة بمجموعة السيطرة والمجاميع الاخرى بينما سجلت زيادة معنوية في عدد النطف البربخية وحركة وحيوية الحيوانات المنوية وانخفاض معنوي في الحيوانات المنوية المشوهة في مجاميع الجرذان المعاملة بالسيلينيوم لوحده والمعاملة بالسيلينيوم بالإضافة الى البروبايل ثايويوراسيل والمجموعة المعاملة بالسيلينيوم بالإضافة للثروكسين. اما الفحص النسيجي للخصى اظهر تحطم النبيبات المنوية وإيقاف تم في عملية تخليق الحيوانات المنوية للجرذان المعاملة بالبروبايل ثايويوراسيل وكذلك بالجرذان المعاملة بالثايركسين بينما خصى الجرذان المعاملة بالسيلينيوم فقد لوحظ التركيب النسيجي للأنايبب المنوية طبيعي ولوحظ مراحل مختلفة من عملية تكوين الحيوانات المنوية وكذلك لوحظ تحسن في التركيب النسيجي للأنايبب المنوية ووجود مراحل مختلفة من عملية تخليق النطف للجرذان المعاملة بالبروبايل ثايويوراسيل بالإضافة الى السيلينيوم و الجرذان المعاملة بالثايركسين بالإضافة الى السيلينيوم.

## REFERENCES

- 1-Chiao, C.Y.; Lin, H.; Wang, W.S. and Wang, S.P. (2000). Direct effects of propylthiouracil on testosterone secretion in rat testicular interstitial cells. *Br. J. Pharmacol.*, 130: 1477-1482.
- 2-Tousson,E.; Ali,E.M.M.; Ibrahim,W. and Mansour,M.A.(2011).Treatment with folic acid ameliorated the histopathological alterations caused by propylthiouracil-induced hypothyroid testes. *Toxicol Indust Health*.28(6): 566-576.
- 3-Krassas,G.E.; Papadopoulous,F.; Tziomalos,K.; Zeginiadou,T. and Pontikides, N.(2008). Hypothyroidism has an adverse effect on human spermatogenesis: a prospective, controlled study. *Thyroid*. 18(12):1255-1259.
- 4-Hadley, M.E. (1992). Endocrinology. Prentice-Hall, Inc. New Jersey, U.S.A.
- 5-Messoudi,I.; Banni,M.; Said,L.; Said.K.; and Kerkeni,A.(2010). Involvement of selenoprotein P and GPx<sub>4</sub> gene expression in cadmium-induced testicular pathophysiology in rat. *Chem Bio Interact*. 188:99-101.
- 6-Evan, G. and Maxwell, W. M. C. (1987). Salamona artificial insemination of sheep and goat. Butter woth, Sydney, Australia.



- 7-**Chemineau, p.; Cagine, y.; Orguer, p. and Nalet, J.C.(1991)**. Training manual on artificial insemination in sheep and goat in animal production and health, FAO. Roma: 83p.
- 8-**Luna,L.G. (1993)**. Manual of histology staining methods of the Armed Forces Institute of Pathology.3<sup>rd</sup> ed., New York, Mc grawHill.
- 9-**Bancroft,J.O.: Stevens,A. and Turner.D.R.(1990)**. Theory and practice of histological techniques. 3<sup>rd</sup> . Churchill living stone. 221-226.
- 10-**Yousofvand,N.; Kazemi,M. and Mohamadizadeh,E.(2013)**. Effect of induced hypothyroidism by propylthiouracil (PTU) on serum levels of testosterone leuteinzing hormone and follicle-stimulating hormone. *J Ilam Uni Med Scie*. 21(6): 1-8.
- 11-**Taha,M.N.; Mahmoud,S.M. and Yahia,G.A.K.(2012)**. Effect of hypothyroidism on sperms characteristics in testes and epididymes of male albino rats. *Ibn AL-Haitham J Pure Appl Sci*. 25(3):62-72.
- 12-**Trummer,H.;Ramschak-Schwarzer, S.; Haas,J.; Habermann,H.; Pummer,K. and Leb, G.(2001)**. Thyroid hormones and thyroid antibodies in infertile males. *Fertil Steril*. 76:254-257.
- 13-**Tahmaz, L.; Gokalp,A.;Kibar,Y.;Kocak,I.;Yalcin,O. and Ozercan,Y.(2000)**. Effect of hypothyroidisim on the testes in mature rats and treatment with levothyroxin and zinc. *Andrologia*. 32(2):85-89.
- 14-**Sahoo,D.K.; Roy,A.; Bhanja,S. and Chainy,G.B.N.(2005)**. Experimental hyperthyroidism-induced oxidant stress and impairment of antioxidant defence system in rat testis. *Indian J Exp Bio*. 43:1058-1067.
- 15-**EL-Gerbed,M.S. A.(2013)**. Histopathological and ultrastructural effects of methylparathion on rat testis and protection by selenium. *J App.Pharmace.Sci*.3(1);53-63.
- 16-**Hamza,R.Z. and AL-Harbi,M.(2014)**. Monosodium glutamate induced testicular toxicity and the possible ameliorative role of vitamin E or Selenium in male rats. *Toxic Rep*.1:1037-1045.
- 17- **Baiomy, A.A.; Mohamed, A.E.A and Mottelib, A.A. (2009)**. Effect of dietary selenium and vitamin E supplementation on productive and reproductive performance in rams. *Bs. Vet Med J.*, 19: 39-43.
- 18- **Kolb, E. and Seehawrer, J.(1998)**. Nutritional biochemical aspects of the use of beta-carotene, vitamin A, D and E as well as ascorbic acid in domestic animals and influence on the secretion and activity of hormones. *Tierarztliche Umschau*, 53: 150-156.

- 19- Surai, P.F.; Brillard, J.P.; Speaeake, B.K.; Bakiblesbois, E.; Seigneurin, F. and Sparks, N.H.C.( 2000).** Phospholipid fatty acid composition, vitamin E content and susceptibility to lipid peroxidation of duck spermatozoa. *Theriogeno.*, 53: 1025-1039.
  
- 20- Ahmed, W.M.; Sabra, H.A. and Hamam, A.M. (2001).** Effect of administration of vitamin A, D , E and selenium during prepartum period on the reproductive function of native cows in Egypt. *Beni-Suef Vet. Med. J.*, 11: 81-91.