

HISTOCHEMICAL STUDY OF MUCOPOLYSSACHARIDES IN STOMACH OF BUFFALO(*BUBALUS-BUBALIS*)

Sawsan Gafoori Ahmed, Fawzi S.Al-Asadi ,

(Received 15 November 2015 , Accepted 7 December 2015)

Keywords: Mucopolyssacharide, stomach, Baffulo.

ABSTRACT

Ten samples of baffula stomach including rumen, reticulum, omasum Abomasum were collected from slaughter of Basrah .Tissue sections were done and stained with alcian blue and acridin orange dyes then photographed by light and fluorescent microscope .The histochemical study showed that all four parts of stomach consist of mucosa,submucosa ,muscular and serosal layer .The histochemical study showed that mucopolysacchrides distributed in all histological layers but with high density in the mucosal layer.

INTRODUCTION

The Buffalo(*Bubalus-bubalis*) were used to study because of economic benefit to the people of marshes. The histochemical comparative studies reveals the presence of similar complexes of polysaccharides (glycoconjugates) in stomach of apes, dogs , cats, desert rats , bobons , rabbits , pigs , guinea pigs , hamsters , mice and humans . (1,2) .The tegumentary mucosa of deer rumen appeared neutral mucopolyssaccharides from 67 days. (3).

In the ruminant, ruminal fermentation transforms most of the polysaccharides of cell wall , all of the intracellular carbohydrates present in the forage in to short-chain volatile fatty acids, which are then absorbed by the rumen epithelium (4).

The carbohydrates of plant tissues are primarily polysaccharides, cellulose, hemicellulose, pectins, fructans and starches , with minor amounts of other compounds (5) .

The aim of the study is to demonstration of mucopolyssaccharides using light and fluorescent microscope.

MATERIAL AND METHOD

Ten samples of buffalo stomach (rumen,reticulim,omasum and abomasums) Were collected from slaughter house of Basrah, the samples were fixed in 10% formalin, washing, dehydration ,clearing, infiltration, embedding , and sectioning were done.

The sections were stained with the following dyes:

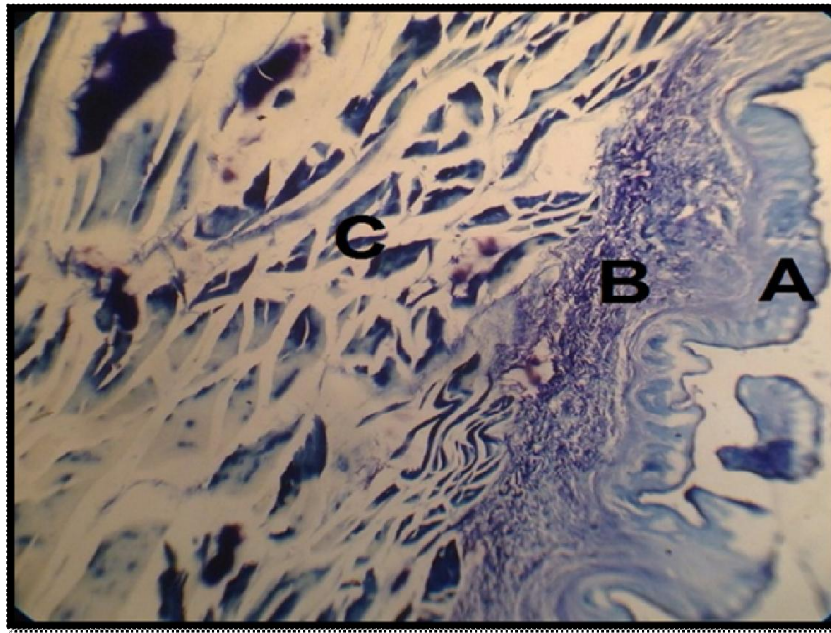
1- Acridin orange dye and photographed under fluorescent microscopy using excitation light of 500 micron . according to(6).

2- Alcian blue dye and photographed under light microscope . (7).

RESULTS

The study showed that all four regions of stomach (rumen , omasum ,reticulum and abomasum) .consist of four histological layer (mucosa, submucosa ,muscular layer and serosa). This mucosa of rumen characterized by papillae which are different in length, while the mucosa of reticulum involved several fold . The mucosa of omasum contain papillae while mucosa of abomasums characterized by presence of several gastric pit fig (1,2,3,4). The histochemical study using light microscope showed t hat mucopolyssacharides distributed in all histological layer but in higher density in the mucosal layer in all four parts of stomach (rumen, reticulum , omasum ,and, abomsum.). fig (1,2,3,4)

On the other hand the Histochemical study using fluorescent microscope showed that mucopoly-ssacharides distributed in all histological layers but in higher density in the mucosal layer . fig (5,6,7,8) .



Fig(1): Section of rumen shows presence of mucopolysaccharides in rumen tissue, denser in mucous layer,(A)Mucosa layer(B)Submucosa layer(C)Muscular layer (alcin blue 400X)

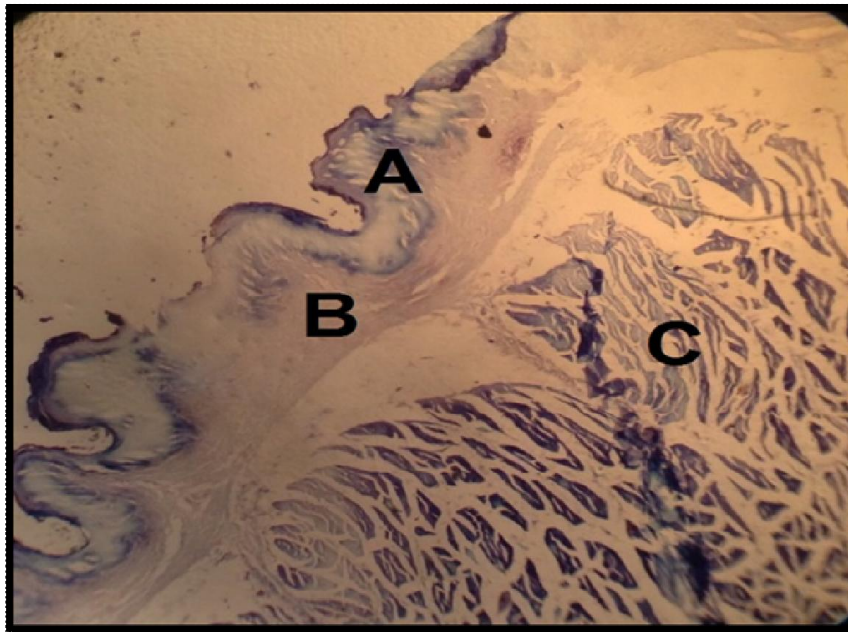


Fig. (2): Section of reticulum shows presence of mucopolysaccharides in reticulum tissue,denser in mucous layer,(A)Mucosa layer(B)Submucosa layer(C)Muscular layer(Alcin blue400X)

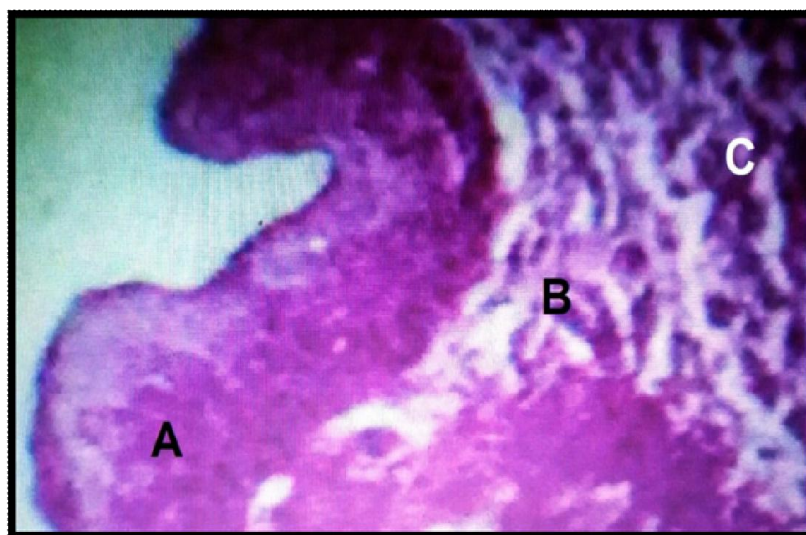


Fig. (3): Section of Omasum shows presence of mucopolysaccharides in omasum tissue,denser in mucos layer,(A)mucosa layer(B)submucosa layer(C)Muscular layer(alcin blue400X)

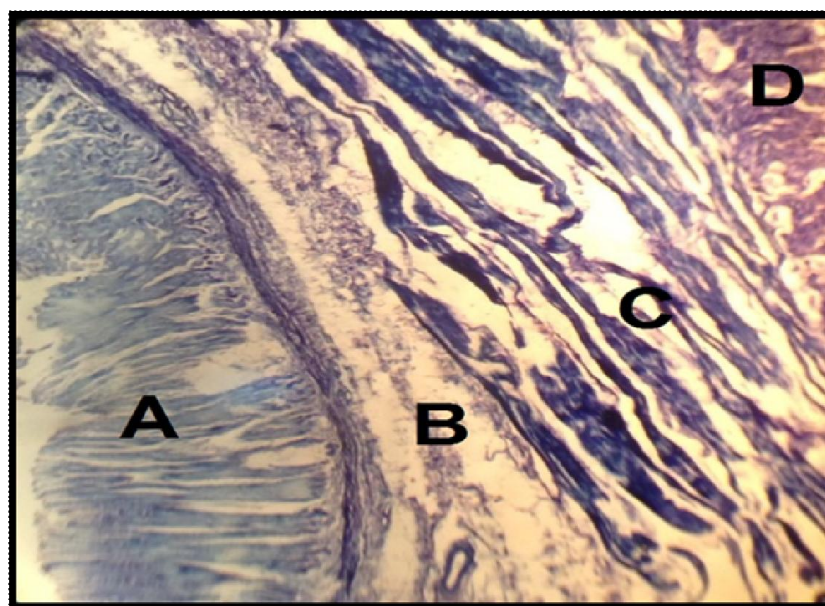


Fig. (4): Section of abomasums shows presence of mucopolyssacharides in abomasums tissue ,denser in mucous layer,(A)mucosa layer(B)submucosa layer(C)muscular layer(D)serosa layer(alcian blue400X)

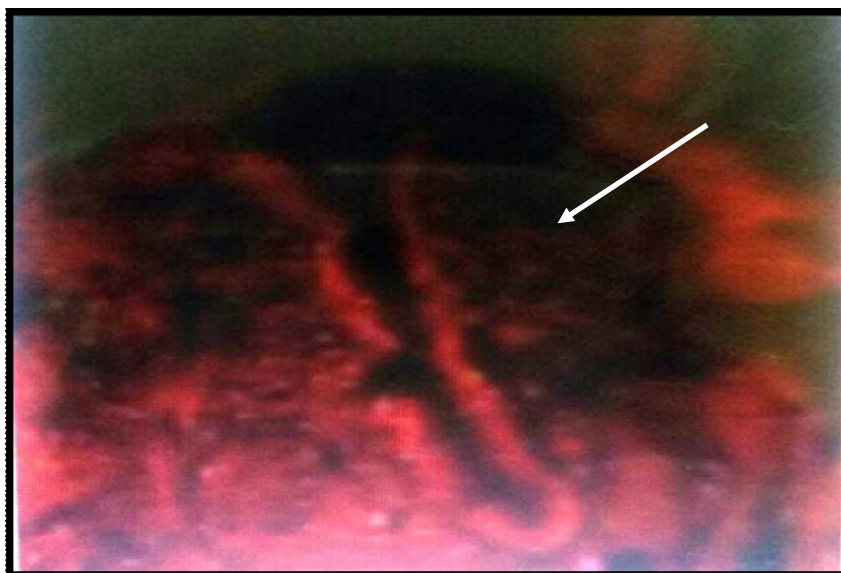


Fig.(5): Section of rumen shows presence of mucopolysaccharides in rumen tissue,denser in mucous layer(acridin orang400X)

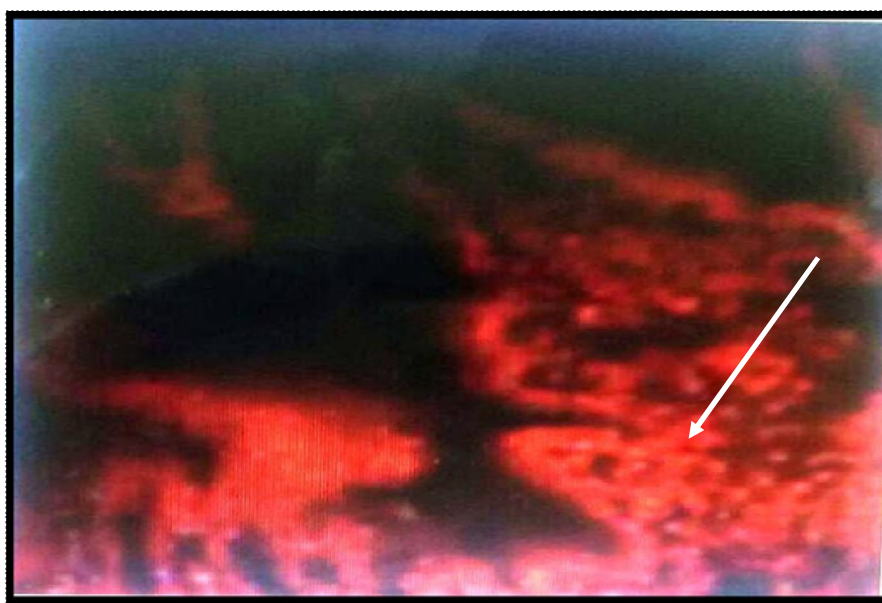


Fig.(6): Section of reticulum shows presence of mucopolysaccharides in reticulum tissue,denser in mucous layer(acridin orange)40X

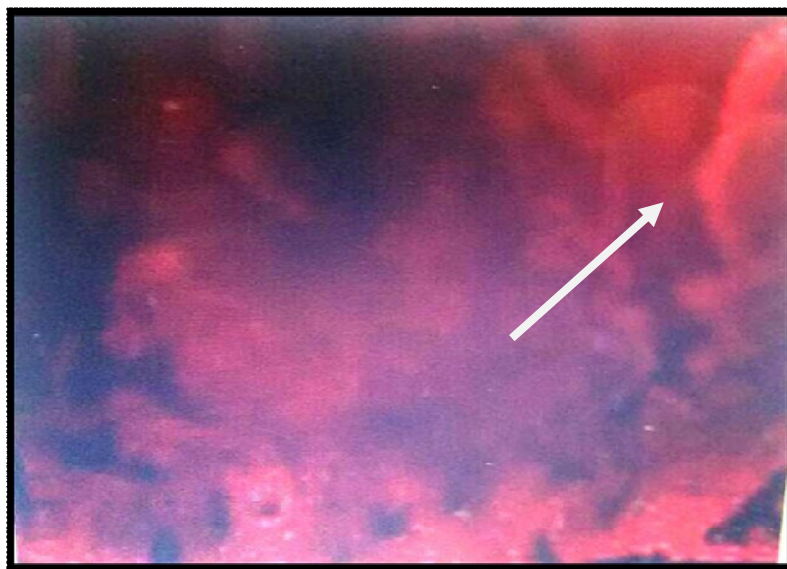


Fig.(7): Section of Omasum shows presence of mucopolysaccharides in Omasum tissue,denser in mucous layer(Acridin orange400X)

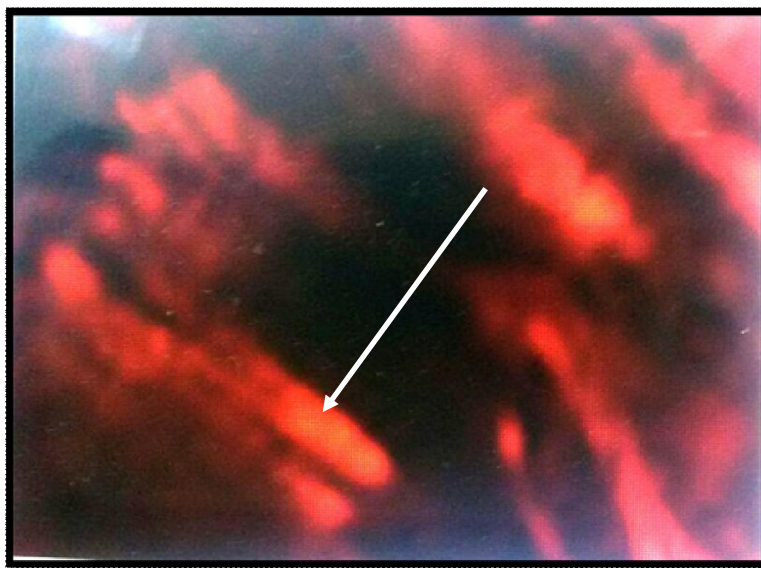


Fig.(8): Section of Abomasum shows presence of mucopolysaccharides in abomasum tissue,denser in mucous layer(acridin orange400X)

DISCUSSION

The results showed that all four parts of Buffalo Stomach consist of four histological layers(mucosa, submucosa ,muscular and serosa) , this results coincided with finding of (8)In Camel , (9)in sheep.

Our Results showed that mucopolyssacharides distributed in all histological layers of stomach with high densities in the mucosal layer, this result is agreement with result of (10) on their study on Red deer and (11) in sheep.

Several authors described the presence of mucopolyssacharide in the rumen, reticulum, omasum, of cattle and the fore stomach of sheep. (12).

The mucopolyssacharide formed a resistant mucosal barrier to protect the mucosal epithelium from acid and enzyme secreted by glands.(13).

The secretion of mucopolyssacharides containing sugar residue in gastric epithelium may serve protect the stomach epithelium from auto digestion caused by HCL enzymes (14).

دراسة كيميائية نسيجية للسكريات المتعددة المخاطية في المعدة للجاموس المحلي

سوسن غفوري احمد ، فوزي صدام الاسدي

فرع التشريح والانسجه، كلية الطب البيطري، جامعة البصرة، البصرة، العراق.

الخلاصة

جمعت عشرة عينات من معدة الجاموس تضمنت (الكرش، الشبكية، القبة، المنفحة) من مجزرة البصرة. تم عمل مقاطع نسيجية. وصبغت تلك المقاطع بصبغة الاليشين الزرقاء وصبغة الاكريدن الحمراء وتم تصوير المقاطع النسيجية بالمجهر الضوئي والفلورسنتي. اوضحت النتائج بأن المناطق الاربعة للمعدة تتكون من الطبقة المخاطية، الطبقة تحت المخاطية، الطبقة العضلية، والطبقة المصلية. اوضحت الدراسة الكيميائية النسيجية بأن السكريات المخاطية المتعددة تتوزع في كل طبقات المعدة وبكثافة عالية في الطبقة المخاطية.

REFERENCES

- 1-Willems,G.& Gerard,D. (1969) .Etude histochemiquedecoparee Desglycoproteines et polysaccharides intracellulaires de l'epithelium et desgladesgastriques chez l'homme et chezdiversesespecies animales. *Acta Gastro-Enterologica*, 32:211-25.
- 2-Sheaahan ,D .G.& Jervis , H.R .(1976) . Compartative histochemistry of gastrointestinal mucosubstances.*AM.J.of Anat.*, 146;103-32.
- 3-Franco¹A J, Masot²A J, Aguado³ma ,Gomez² Land Redondo ²E (2004). Morphometric and immune histoChemical study of the rumen of red deer during prenatal development *Journal of Anatomy*, 204(6): 501-513.

- 4- Bird AR ,Croome WJJ, FanYK , Back BL;Mc Bride BW, Taylor IL (1996) .
Peptide regulation of intestinal glucose absorption . *J.Anim .Sci* 74:2523-2540 .
- 5-heander.O(1981).Chemical composition of low quality roughages as related to alkali treatment In kategile J.A,Said AN ,Sandstol F(Eds.) Utilization of low quality roughages in Africa .Agricultural Development Report 1.*The Agricaltural University Of Norway.pp.1-27.*
- 6-Hicks and matthael,(1958). A Selective fluorescence stain for mucin.*The Journal of pathology and Bacteriology.*473-476.
- 7-Steeman, (1950) . " Chloromethylated copper selective dye for mucins.*Microsc.Sci.*, v.91,477-479.
- 8-Naghani ES and L Akradi.(2012) . Histogenesis of rumen in one-humped Camel (Camelus dornedarius) . *pak Vet J*,32(2):269-272.
- 9- Poonia A , Kurmur pawan and Kurmar parveen. (2011). Histomorphological studies on theramen of the sheep(ovisaries).*HaryanaVeterinary*, 50:49-52.
- 10-Inese Zitare^{1*} ,Mara pilmane² , and Aleksandr Jemeljanove¹.(2013). Histomorphology of the digestive system of red deer *journal of Veterinarg medicin and Animal Health* , p p .9 9-106. [http://www. Accademic journals.org/JVMAH](http://www.Accademicjournals.org/JVMAH).
- 11-Franco A, Regodon S, Robina A,Redondo E. (1992). Histomorphometric analysis of the rumen of theSheep during development .*AM. J.vet. Res.*,53: 1209-1217.
- 12-Masot A.T., Franco A.T., and Redondo E. (2007).Comparative analysis of the for stomach mucosa in red deer during prenatal development.*Revue med. Vet*,158,7,397-409.
- 13-Leizhu;Tun Tie Wang (2013).Histological observation of stomach of the yellow – billed Grosbeak .*int.T.morphed.*,31(2):512-515.
- 14- Arellano T.M ., Storch.V and Sarasque C.S. (2001) . Histological and histochemical observation in the stomach of the Senegal sole, solea senegalensis . *Histol Histopathal* 16:511-521.