

A comparison of conjunctival rotation flap and autoconjunctival graft techniques in pterygium surgery at aldiwaniah teaching hospital from 2007_2013

Hassanen abdalameer hadi *, Hassanen hassan alrikabi**

* Ophthalmic senior, Diwanyia teaching hospital, ** Lecturer in ophthalmology, Department of surgery, college of medicine, Al-Qadissiyah university
E-mails: hassnainophthalmic@yahoo.com, hassanainattar@yahoo.com

(Received 19 / 3 /2015 , Accepted 8 / 6 / 2015)

الخلاصة:

الهدف:مقارنه بين حالات رجوع الظفرة بعد عمليات تدوير وترقيع المنظمة والمضاعفات الطريقة 06 مريض أجريت لهم عملية رفع ظفره في مستشفى الديوانية التعليمي 52 رجل و 52 امراه من قبل نفس الجراح 52مريض بطريقه الترقيع و 52 مريض بطريقه التدوير وتم متابعتهم لمدته سنه ونصف 5605. - للفترة بين5662 لملاحظه رجوع المرض والمضاعفات والمقارنة حصلت. النتائج8%:نسبه الرجوع في الترقيع% 8.0 في التدوير والمضاعفات اقل في التدوير. الاستنتاج: رجوع المرض تقريبا نفسه في الحالتين ولكن المضاعفات وسهوله وسرعه العملية كان في طريقه التدوير

Abstract

purpose: to compare the result of conjunctival flap and autograft in term of recurrence rate and complication in Pterygium surgery.

Methods: A total of sixty patients(twenty five male and thirty five female) operated for pterygium with conjunctival autografts(in 25 eyes) or conjunctival flap(in 35 eyes) technique at diwanyia teaching hospital and with 18 months follow-up were registered. Patients were called for voluntary examinations of their respective ocular surface status .

Result: Mean age was 42.5 years (range, 23–75), 58.33% of the patients were male, and 75% worked predominantly outdoors. Mean follow-up was 12 months (range, 3–18)

Recurrence rate was 8%in graft,8.6%in flap, however edema was less in flap and granuloma was nil in both.

Conclusions: After a long follow-up period for autograft and conjunctival flap pterygium surgery, there were no statistically significant differences in recurrence rates ,as well as flap is faster and easier technique with less postoperative edema.

Introduction:

Pterygium is Greek word means wing ,it is a wing-like fibro vascular degenerative condition of subconjunctival tissues extending from the conjunctiva to the cornea¹.

Pterygium consider as a cause of concern for both the patient because of its unsightly appearance and the surgeon because of its tendency to recur².

There is a direct proportional relationship between its prevalence and the proximity to the equator⁴.

The prevalence of Pterygium is 5.2% world wide but in warm dry climate it raise up to 22%³ .

There is no definitive causative factor but occur more in uv sun light exposure with higher incidence in male, this may be due to more hours that men spent outdoors⁵.

Pterygium is more common in farmers and those who do not wear sun-glasses².

Prevalence and incidence rate differ with respect to the age .The elderly have the highest prevalence rate but rare in those below 20 years⁶.

The symptom associated with pterygium include the presence of cosmetically noticeable blemish, intermittent episode of inflammation during which pterygium became hyperaemic and may produce photophobia, watering and foreign body sensation and decrease in visual acuity because of astigmatism, increased glare and decrease in contrast sensitivity^{2,3,5}.

Pterygium surgery eliminate the abnormal tissue from the cornea and sclera.

Before contemplating any surgery, the treating ophthalmologist should explain to the patient about its high percentage of recurrence^{4,6}.

Surgical management of pterygium should not be undertaken causally because of the high probability of recurrence⁷.

The old techniques is to left bare area were pterygium was removed, unfortunately this lead to high recurrence rate⁸.

Newer technique is to fill the flap with conjunctival graft removed from under the eye lid, sutures can cause edema and discomfort for weeks⁴. The latest advanced is to use glue with rapid healing.⁵

Another procedure is to use amniotic membrane instead of auto conjunctival graft in case of large defect that is created by conjunctival dissection⁶. Several authors have noticed that this decrease postoperative inflammation and speed up re-epithelialization of the surface⁶.

The other technique is the anchored conjunctiva rotational flap and preservation of inferior limbal anchoring point 1mm by in complete cutting of limbal area⁷.

Aim : to compare conjunctival auto graft and anchored flap in term of recurrence rate and complications regarding granuloma and post operative discomfort and edema.

Material and Methods:

Sixty patient who underwent Pterygium surgery, which was performed on one eye of 25 male and 35 female. autograft in 25 eyes and flap in 35 eyes; this was done in Diwanya teaching hospital by same surgeon and same techniques afte Data were obtained

preoperatively and at the first, third, eighth, and 15th day, and at the first, third, sixth, 12th and 18th postoperative month using a standardized protocol that included age, sex, working environment, previous ocular surgeries, pterygium location, surgical technique, and outcomes.

Surgical Technique:

Under topical anesthesia with proparacaine, the pterygium head was dissected from its central corneal edge toward the limbal one with a 15-degree disposable knife, aiming at liberating the healthy but tractioned nasal bulbar conjunctiva so as to finally remove as little of it as possible; the body of the pterygium and its accompanying Tenon capsule were resected.

Any remaining episcleral tissue and the exposed Tenon capsule under the free edges of bulbar conjunctiva were removed.

The free conjunctival graft was obtained from the same eye as follows: a pair of radial incisions were made on the superior bulbar conjunctiva with a 15-degree disposable knife encompassing an area similar to that of the conjunctival defect created while resecting the pterygium down to the limbal area but not including it. The underlying Tenon capsule was removed with Wescott scissors and toothed Colibri Barraquer forceps. The graft was sectioned at 1 mm from the limbus and placed over the receptor bed; it was anchored with 2 interrupted conjunctival (graft)-episcleral-conjunctival 10-0 nylon sutures, 2 mm from on the corneal border, and 5 interrupted conjunctival (graft)-conjunctival sutures at its free borders. Finally, the upper bulbar conjunctiva was anchored to the limbus with two 10-0 nylon sutures to preserve a healthy, nonscarred donor site for future surgeries.

On finishing surgery, cycloplegia with cyclopentolate and polymyxin, neomycin, and dexamethasone ointment were applied, and the eye was occluded for 24 hours. On the following day, fluorometholone drops three times daily and artificial tear (preservative free) were started for 2

weeks. Sutures were removed between the 12th and 15th postoperative.

Results:

The charts of 60 patients were reviewed. Ten patients had a history of fellow eye pterygium surgery, one of them recurrent.

Mean age was 42.5 years (range, 23–75), 58.33% of the patients were male, and 75% worked predominantly outdoors. Mean follow-up was 12 months (range 3–18months).

Table(1) demographic data of study:

variable	number	percent
Sex		
Male	35	58.33
female	25	41.67
Primary ptrygium	59	98.34
Recurrent ptrygium	1	1.66
Ptrygium type		
Grade 1	18	30
Grade 2	42	70
Mean age	42.5	

There was a total of 60 surgeries: 25 using a free conjunctival autograft technique and 35 using a conjunctival flap technique.

Intraoperative complications included recipient bulbar conjunctiva tear (1 case) and graft buttonhole (1 case).

Early postoperative discomfort was common in both groups, as well as mild subconjunctival haemorrhage was observed. Edema occur in (18) patients from 25 patients in graft surgery and in flap surgery

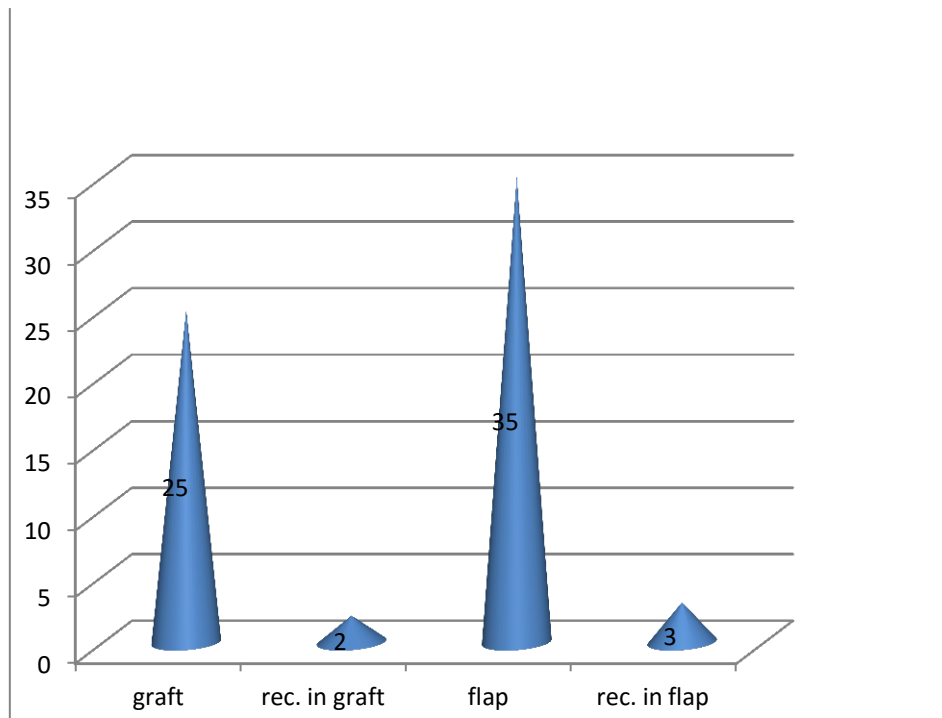
there are 5 patients had edema . Granuloma was nil in both groups.

Late postoperative complications were limited to pterygium recurrences (5 cases, 8.33%):two of them undergone conjunctival autograft surgery while the remaining were from anchored flap surgery.three of those patients showing recurrence after six months while the other after one year. None of these patients had any previous ophthalmic surgery

Table (2)number of patients in the two process and the recurrence rate

Type of surgery	Number of patients	Number of recurrent cases
Conjunctivalautograft	25	2
Conjunctival flap	35	3

Figure(1) show the number of cases in the two process and the recurrence rate



Discussion:

There are many attempts to optimize Pterygium surgery. Today wide variety of techniques are use from bare sclera to more complex amniotic membrane transplantations⁸.

While removing the pterygium only leaving the sclera bare with short procedure time ,it has found to be associated with highest recurrence rate reported in most of studies¹². Using chemical e.g. mitomycin and 5FU found to decrease the recurrence rate but there are many complications might result from this intervention like scleral melting and necrosis².

MMC is still a less than perfect known non-cell cycle specific alkylating agent that forms linkages with guanine residues in DNA⁴. It pertains to a class of drugs known as radiomimetic in that their mode of action mimics that of ionizing radiation, with complications similar to those seen after beta irradiation^{7,8,9}. If one considers the main objectives of pterygium surgery to be the reconstruction of the anatomic bed and the

subsequent functional limbal barrier restoration then the use of antimetabolites such as MMC and 5-FU is not sound for the management of pterygia^{11,12} ; eventhough, their use has resulted in lower recurrence rates but more frequent and severe complications, as previously mentioned. Additionally, it is not clear that their action is restricted to fibroblasts, which means that they could affect other cell lines such as the limbal stem cells, which are responsible for the second objective of this surgical procedure, restoration of the functional limbal barrier, in a disease already expressing a gradual loss of these cells due to the additive effect of UV radiation, microtrauma, and a poor generation and amplification of the transitorily amplified cells^{4,6,13,14}.

On the other hand, autografting procedures recently consider the procedure of choice for pterygium removal as it associated with very low recurrence rate(3%-5%) and also reduces the risk of necrosis and melting of

chemotherapy but at the cost of time and discomfort⁹.

The patients included in this study were essentially consecutive cases but the retrospective nature of this study may induce unrecognized bias .

Prospective series in the literature report recurrence rates 2-39% in sutured autograft¹⁰, in accordance with our study it was 8%

which consider within the accepted rate of recurrence by most studies^{11,13}.

There was also difference in sex distribution between group ;however we are not aware of any results for male and female recurrences¹¹.

We believe that no late recurrences were missed ,because during period of study all Pterygium surgery was carried out by same surgeon.

In our study we found recurrences rate in flap group was 8.6% which was comparable with study done by young al et al 15%.,narsani ak et al 19%.manniget al 10.5 % while the recurrence rate were 8% in graft group compare to kenyon et al 5.3%de Keizer et al6.6%⁸.

Conclusion:

Conjunctival flap surgical procedure of Pterygium was similar recurrence rate and easier with less edema and faster and more comfortable compared to auto flap technique.

References:

- 1) American academy of ophthalmology,section8 external disease and cornea chapter21,431 ,2009-2010
- 2) Textbook of ophthalmology volume2 sunita agarwal ,2002 3)Mackenzie fd ,hirst lw ,battistutta d,green a, riskanalysis in the development of pterygia.ophthalmology1992;99:1056
- 4)detorakis et,zafiropoulous a,arvanitis da,et detection of point mutation at codon 12 of kl-ras in ophthalmic pterygia.eye 2005;19:210-4.
- 5)yanoff m,duker j. text book of ophthalmology.2nd edition Elsevier publication;2008.p.446-7
- 6)youngson recurrence of pterygia after excision. Journal ophthalmol.1972;56:120
- 7)koranyi g,seregard s,kopp ed.cut and paste;a no suture,small incision approach to Pterygium.arq.bras.oftalmol.2006;69;161-4

8)schellini sa,hoyama e,oliviera de ,et al.matrixmetalloproteinase -expression in Pterygium.arq.bras.oftalmol.2006;69:161-4

9) rasool a.u,ahmedc.n,khan a.a. recurrences of pterygia inpatient have conjunctival autograft and bare sclera surgery.annals 2010;16;242-6

10)nazallah,shah a,ahmedm,baser a,marwat sk ,saeed n recurrence rate of Pterygium j.med.sci.2010;18:36-9

11) Solomon ,pires ,tsengscg .amniotic membrane transplantation a 12)sihotar r,tendon r,parson diseases of the eye .21 edition.elsevierpublication;2011.p.181

12) Singh G, Wilson MR, Foster CS. Long-term follow-up study of mitomycin eye drops as adjunctive treatment of pterygia and its comparison with conjunctival autograft transplantation. Cornea. 1990;9(4):331-4.

13) Hirst LW. Recurrent pterygium surgery using pterygium extended removal followed by extended conjunctival transplant. Recurrence rate and cosmesis. Ophthalmology.2009;116(7):1278-86.

14)Tan DT, Chee SP, Dear KB, Lim AS. Effect of pterygium morphology on pterygium recurrence in a controlled trial comparing conjunctival autografting with bare sclera excision. Arch Ophthalmol. 1997;115(10):1235-40.