

Original paper

No Tie Technique Using Harmonic Scalpel for Thyroidectomy Versus Conventional Technique (A Prospective Study)

Ali Azeez Ali^{^*}, Ali Mossa Jafar Al-Mayali[^]

[^]Dept. of surgery- Al-Hussain medical city

Abstract

Background: The pioneers of thyroid surgery, Theodor Kocher and Theodor Billroth, developed an acceptable technique of standardized thyroid surgery in the nineteenth century. It includes three basic principles: identification and ligation of the feeding vessels, identification and preservation of the laryngeal nerves and identification and preservation of the parathyroid glands. The basic surgical instruments have not significantly changed, the main innovations are new methods of coagulation and vascular section.

Aim: to compare the outcomes of total thyroidectomy and lobectomy, utilizing the conventional hemostatic technique (CH) and harmonic scalpel technique (HS).

Patients and Methods: This study was carried at Al-Husseini medical city. In one group the tie and ligature technique was applied and the new harmonic scalpel technique was applied to the other group.

The study variables are: operative time, post-operative drainage volume, recurrent laryngeal nerve (RLN) status and total serum calcium level in total thyroidectomy group.

Student's t test was used to compare quantitative variables, chi square test was to compare qualitative variables.

Results: Seventy patients were included in this study, 40 patients had total thyroidectomy, and 30 patients underwent lobectomy.

The mean operative time, in the total thyroidectomy group, was 83.4 ± 13.2 minutes versus 60.3 ± 5.3 minutes in the CH and HS respectively. And it was statistically significant. In the lobectomy group, the mean operative Time was 47.8 ± 7.3 minute versus 38.8 ± 6.8 minute in the CH and HS respectively. It was statistically significant.

Post-operative drainage, in the total thyroidectomy group, was 128.6 ± 11.1 ml versus 98.1 ± 10.3 ml in the CH and HS group respectively. In the lobectomy group, it was 116.4 ± 21.1 ml versus 62.8 ± 8.6 ml in the CH and HS group respectively. And both are highly significant.

Regarding RLN palsy, in the total thyroidectomy group, 2 patients out of 20 with CH versus 3 out of 20 with HS, sustained RLN palsy but statistically was non-significant. In the lobectomy group, 2 patients out of 14 with CH versus zero out of 16 patients with HS sustained RLN palsy also was non-significant.

Regarding hypocalcaemia, in the total thyroidectomy group, 4 patients out of 20 with CH versus 3 patients out of 20 in the HS group developed post-operative hypocalcaemia and was statistically non-significant.

Conclusion: Harmonic scalpel is a relatively safe, effective hemostatic tool in thyroid surgery. Complications are no more than that of conventional hemostatic technique.

Keywords: Harmonic scalpel, thyroidectomy, hypocalcaemia, RLN injury.

*For Correspondence: E-Mail ahmed4222000@yahoo.co.uk

Introduction

The principles in thyroid surgery depends on 3 steps, identification and ligation of the vascular supply to the thyroid, identification and safeguarding the RLNS, identification and preservation of the parathyroid glands ⁽¹⁾.

Thyroid gland is one of the most vascular organs in the body ⁽²⁾. It is closely related to two important structures, the recurrent laryngeal nerves and parathyroid glands.

Recurrent laryngeal nerve injury may be unilateral or bilateral, transient or permanent. Permanent paralysis is rare if the nerve has been identified at the operation. Hypoparathyroidism may be due to removal of the parathyroid glands or infarction through damage to the parathyroid end artery; often, both factors occur together.

Bleeding remains one of the major complications of thyroid surgery. Intraoperatively, bleeding can obscure the operative field and make safe dissection difficult with increased risk to the nearby structures. Postoperatively, it has the potential to cause life threatening airway obstruction.

The use of electrocoagulation for hemostasis carries the risk of lateral heat dispersion ⁽³⁾. Effective vessel hemostasis can be achieved by using the conventional tie technique.

During the last two decades, new methods for improving operative time, safety, and even invasiveness of thyroidectomy have been proposed, including harmonic scalpel (HS), Laser and Liga-Sure ^(4,5,6,7). The harmonic scalpel has been used in solid organs surgery e.g. pancreatic surgery ⁽⁸⁾, adrenalectomy ⁽⁹⁾ and thoracic surgery as a safe and effective hemostatic technique.

The aim of the study is to compare the outcomes after thyroidectomy using the conventional hemostatic technique and the harmonic scalpel technique.

Patients & methods

Seventy patients were enrolled in our study. Forty (57.1%) patients were subjected for total thyroidectomy {20 (50%) patients were operated on using harmonic scalpel, the other 20 (50%) were subjected to conventional tie technique} and thirty for lobectomy {harmonic scalpel technique was used in 16 (53.3%) patients and conventional tie technique was used in 14 (46.7%) patients}. The study was carried out between 1/1/2013 and 31/12/2013.

All the operations were performed by the same surgical team after consent the patients.

All patients who required total thyroidectomy (bilateral total lobectomy plus isthmusectomy) and lobectomy (total lobectomy plus isthmusectomy) were included while those

1. with low preoperative serum calcium.
 2. with vocal cord palsy on preoperative assessment.
 3. with need for cervical lymph node dissection.
 4. with previous thyroid surgery.
 5. with history of head and neck irradiation.
 6. with coagulopathy.
- were excluded.

The study variables were

- 1-Operative time.
- 2-Post-operative drainage volume.
- 3-Recurrent laryngeal nerve (RLN) status
- 4-Total serum calcium level in total thyroidectomy group.

In addition to the routine pre-operative Investigations, patients were investigated for

1. Thyroid function test (T3, T4, TSH)
2. Pre-operative Laryngoscopy for vocal cords assessment.
3. Ultrasound thyroid gland assessment.
4. Fine needle aspiration for cytology.
5. Pre-operative serum calcium.

Hyperthyroid patients were prepared with antithyroid drugs. The patients had general anesthesia with endotracheal intubation

with collar incision two finger breadth above the suprasternal notch. In the conventional technique of tying and knotting absorbable vicryl suture was used. The superior, inferior thyroid pedicles and the middle and inferior plexus of veins were ligated.

In no tie technique, we used focus ultracision harmonic scalpel (SORING CE0123, Made in Germany) (figure 1) for cutting and coagulation where the generator can be adjusted from level 1 to 4 to increase cutting speed and decrease coagulation by increasing the blade's lateral excursion.

Redivac drain was used to evacuate post-operative collection over 48 hours.

Vocal cords were checked preoperatively and during recovery by the anesthetist and if any sort of paralysis was found, the patient was followed up at monthly intervals until 6 months.

During the first post-operative day, patients were examined for Chvostek's sign, Trousseau's sign and Serum calcium was estimated. Serum calcium level of 8 mg/dl (2mmol/l) was considered as a threshold value for hypocalcaemia. If hypocalcaemia was found, the patient would be put on calcium and vit. D preparations.

Hypocalcaemia and RLN palsy were considered transient if resolved within 6 months and permanent if they persist after 6 months.

Results

Seventy patients were enrolled in this study, 40 (57.1%) patients of them had been subjected to total thyroidectomy and the other 30 (42.9%) patients had been subjected to lobectomy (Fig. 2).

Type of Hemostasis

Figure 3 shows the numbers of patients according to the type of operation distributed according to the technique of hemostasis, as it is shown in this figure, patients in the total thyroidectomy group were equally distributed on harmonic and ligation hemostasis; 20 patients (50%) in each type. In the lobectomy group, ligation was performed in 14 patients (46.7%) and the harmonic hemostasis in 16 patients (53.3%).

Operative time

The mean operative time in total thyroidectomy with ligation hemostasis was 83.4 ± 13.2 min., which was longer than (60.3 ± 5.3) min. with harmonic hemostasis. Statistically the difference was highly significant, $P < 0.001$.

In the lobectomy group, the mean operative time with ligation hemostasis was also longer than that with harmonic hemostasis, (47.8 ± 7.3) min. vs. (38.8 ± 6.8) min., respectively. And the difference was statistically significant, ($P = 0.002$).

These findings indicate that in both types of operations the operative time was longer with ligature hemostasis than with the harmonic technique (Table 1).



Figure 1. The harmonic scalpel used (Soring CE 0123 made in Germany)

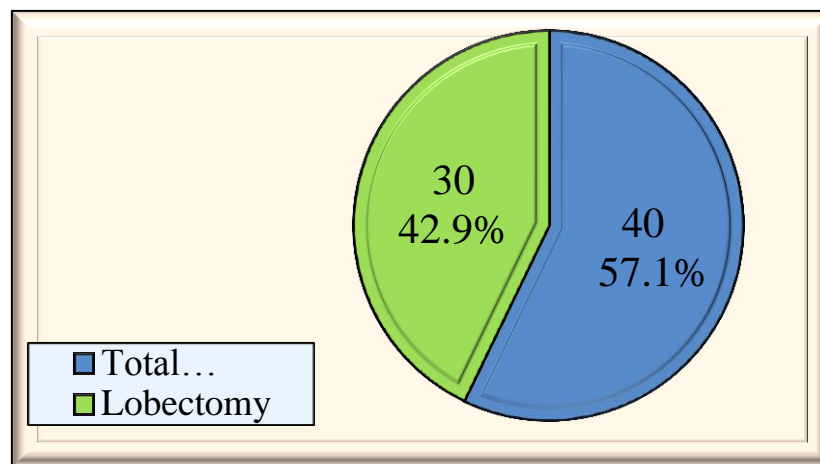


Figure 2. Distribution of patients according to the type of operation

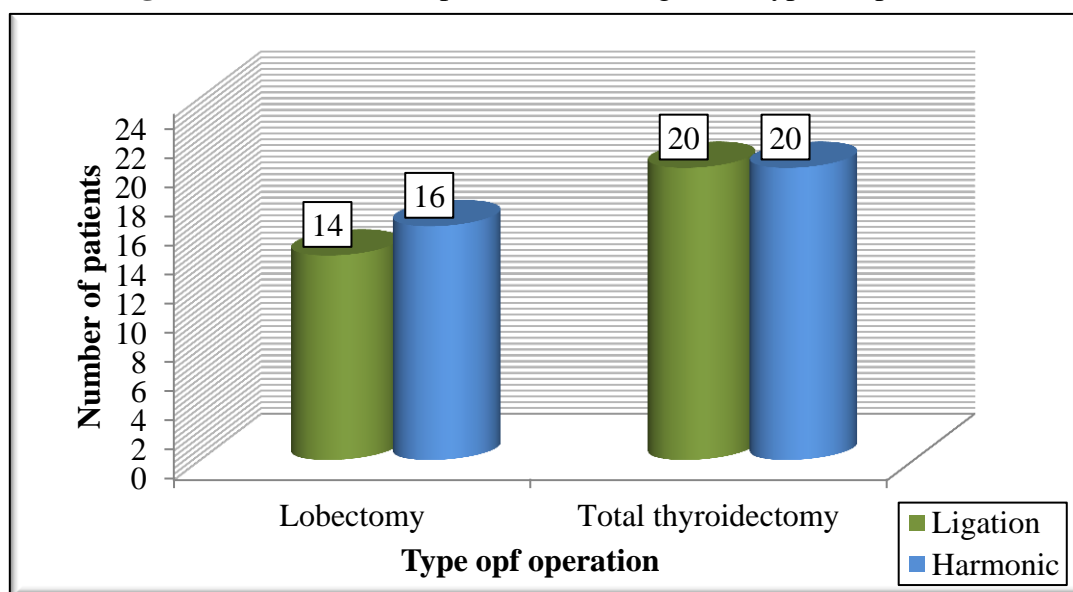


Figure 3. Distribution of hemostatic procedure according to the type of operation

Post-operative drainage:

In the total thyroidectomy group the mean volume of post-operative drainage was more with ligation hemostasis than in the harmonic technique 128.6 ± 11.1 cc versus 98.1 ± 10.3 cc respectively as shown in table 2.

The same was found in the lobectomy group, the mean volume of postoperative drainage was more with ligature hemostasis than in the harmonic technique, 116.4 ± 21.1 vs. 62.8 ± 8.6 cc, respectively. In both the P.value was highly significant; <0.001 , (table 2). These findings indicate that the drainage volume

was more when ligature hemostasis was applied.

Recurrent laryngeal nerve palsy:

In total thyroidectomy group, recurrent laryngeal nerve palsy was reported in 5 (12.5%) patients, 2 of them with ligation hemostasis represent 10% of the 20 patients with ligation, and the other 3 patients represent 15% of the 20 patients with harmonic hemostasis, however, the difference was statistically not significant (P.value= 0.743), (Table 3).

In lobectomy group, recurrent laryngeal nerve palsy was reported in 2 patients only, in both ligation hemostasis was performed, they represented 14.3% of the

14 patients with ligation. None of the patients in whom the harmonic hemostasis was performed had RLN palsy, however, the difference was statistically not significant (P.value=0.21) indicating no statistical correlation between the type of hemostasis and RLN palsy, (Table 3).

Hypocalcaemia

Among the 40 patients with total thyroidectomy, hypocalcaemia was reported in 7 patients (17.5%), 4 of them with ligation hemostasis represent 20% of the 20 patients with ligation, and the other 3 represent 15% of the 20 patients with harmonic hemostasis, however, the difference was statistically not significant , P. Value =0.677, (table 4).

Table 1. Comparison of operative time according to the technique of hemostasis used.

Type of operation	Technique of hemostasis	Number of patients	Operative time(m)		P. value
			Mean \pm SD	Range	
Total Thyroidectomy	Ligation	20(50%)	83.4 \pm 13.2	60– 105	<0.001
	Harmonic	20(50%)	60.3 \pm 5.3	50 – 70	
	Total	40(100%)	71.1 \pm 15.1	50 - 105	
Lobectomy	Ligation	14(46.7%)	47.8 \pm 7.3	35 – 60	0.002
	Harmonic	16(53.3%)	38.8 \pm 6.8	25 - 50	
	Total	30(100%)	43.0 \pm 8.3	25 - 60	

SD=standard deviation

m=minute

Table 2. Post-operative drainage volume according to the type of operation and technique of hemostasis.

Type of operation	Technique of hemostasis	Number of patients	Post op. drainage volume(cc)		P. value
			Mean \pm SD	Range	
Total Thyroidectomy	Ligation	20(50%)	128.6 \pm 11.1	50 - 200	<0.001
	Harmonic	20(50%)	98.1 \pm 10.3	50 - 150	
	Total	40(100%)	112.3 \pm 7.9	50 - 200	
Lobectomy	Ligation	14(46.7%)	116.4 \pm 21.1	30 - 300	<0.001
	Harmonic	16(53.3%)	62.8 \pm 8.6	25 - 150	
	Total	30(100%)	87.8 \pm 11.7	25 - 300	

SD=standard deviation

Table 3. Distribution of RLN injuries according to the type of operation and technique of hemostasis.

Type of operation	Technique of hemostasis	number of patients	RLN palsy	P. Value
Total Thyroidectomy	Ligation	20(50%)	2(10%)	0.743
	Harmonic	20(50%)	3(15%)	
	Total	40(100%)	5(12.5%)	
Lobectomy	Ligation	14(46.7%)	2(14.3%)	0.21
	Harmonic	16(53.3%)	0(0.0%)	
	Total	30(100%)	2(6.7%)	

Table 4. Distribution of hypocalcaemia according to the technique of hemostasis used.

Type of operation	Technique of hemostasis	number of patients	Hypocalcaemia	P. value
Total Thyroidectomy	Ligation	20(50%)	4(20%)	0.677
	Harmonic	20(50%)	3(15%)	
	Total	40(100%)	7(17.5%)	

Discussion

Thyroidectomy is an operation which needs meticulous dissection and effective hemostasis. Morbidity mainly results from postoperative RLN palsy and hypocalcaemia. The incidence of RLN palsies varies from 0.9% to 7%, while transient hypocalcaemia after total thyroidectomy may reach 60%⁽¹⁰⁾

Over the last two decades new hemostatic techniques were introduced into the surgical field by which hemostasis is secured. One of these advances is the harmonic scalpel^(3,4,11), in this device, ultrasound vibrations at frequency of 55.5KHZ cut and coagulate tissue at the same time⁽¹²⁾, by denaturing the protein of the muscular layer and the endothelium of the blood vessel forming a coagulum sealing vessels up to 3 mm in diameter⁽¹³⁾. It differs from other modalities through its minimal lateral heat dispersion which does not exceed 1-2 mm⁽¹⁴⁻¹⁷⁾ which is half the heat spread caused by other means^(18,19), thus there will be less damage to nearby vital structures such as the RLN and the parathyroid glands^(18,19,11,12).

Harmonic scalpel has been used in different surgical procedures depending on the same principles (4).

The dissection, ligation, and division of the thyroid vessels are time consuming. We showed it is possible to shorten operative time by using harmonic scalpel. In our study, the operative time was found to be shorter compared to the conventional tie technique.

In the total thyroidectomy group, the operative time was 83.4 ± 13.2 (the mean \pm S.D) minutes versus 60 ± 3 (the mean \pm S.D) minutes in the tie technique and harmonic scalpel respectively, P value (<0.001) was statistically highly significant. In the lobectomy group, it was 47.8 ± 7.3 (the mean \pm S.D) minutes versus 38.3 ± 6.8 (the mean \pm S.D) minutes in the tie technique and harmonic scalpel respectively, P value (0.002) was statistically significant. While a study by

Leonard and Timon⁽²⁰⁾ concluded that the use of harmonic scalpel was not superior to the conventional techniques with respect to operative time many other studies reported 6 to 76 minutes decreases in the operative time,^(6,4,21-25).

In our study we found lower post-operative drainage volume over 48 hours in the harmonic versus the tie technique in both the total & the lobectomy groups. Thus it was 128.6 ± 11.1 ml (mean \pm SD) versus 98.1 ± 10.3 ml in the tie technique and the harmonic group respectively in the total thyroidectomy group. P value (<0.001) was statistically highly significant.

In the lobectomy group, we achieved the same findings, it was 116.4 ± 21.1 ml (mean \pm SD) versus 62.8 ± 8.6 ml in the tie technique & harmonic scalpel technique respectively where the P value (<0.001) was highly significant statistically. The result of our study is similar to other studies^(29,30,31,32), which may be due to more precise control of small blood vessels⁽²⁴⁻²⁷⁾.

Two of the major complications after thyroidectomy are hypocalcaemia and RLN palsy, they may be attributed to lateral thermal effect of harmonic scalpel^(4,23,6). However, several studies show that harmonic scalpel can be used safely in thyroid surgery with no increase in these complications^(29,25,30,31). In some other literatures transient hypoparathyroidism was more in the harmonic scalpel group⁽²⁸⁾. Our results seem to support the hypothesis that reduced lateral thermal conduction (<2 mm) might lead to no increase in these complications.

One thing about the harmonic scalpel is that it is costly but this may be neutralized by the shorter operative time allowing for more thyroid surgery on the same list⁽³²⁾.

Conclusion

For thyroidectomy, harmonic scalpel is a relatively safe hemostatic tool. Operative time is shorter, post-operative drainage

volume is lower. Complications (recurrent laryngeal nerve palsy and hypocalcaemia) are no more than with conventional hemostatic technique.

Recommendation

Probably we may need more multi-center studies and more experience in this new modality of hemostasis to give accurate conclusions about the outcome, even though the early results are encouraging.

References

1. Becker WF. Presidential address: pioneers in thyroid surgery. *Annals of surgery*. 1977 May;185:493.
2. Gluckman JL. Total thyroidectomy. In: Bailey BJ, Calhoun KH Atlas of head and neck surgery: otolaryngology, 2nd ed. Philadelphia: Lippincott Williams & Wilkins. 2001;228–9.
3. Miccoli P, Materazzi G, Miccoli M, Frustaci G, Fosso A, Berti P. Evaluation of a new ultrasonic device in thyroid surgery: comparative randomized study. *The American Journal of Surgery*. 2010 Jun 30;199:736–40.
4. Siperstein AE, Berber E, Morkoyun E. The use of the harmonic scalpel vs conventional knot tying for vessel ligation in thyroid surgery. *Arch Surg*. 2002; 137:137–42.
5. Yildirim O, Umit T, Ebru M, Bulent U, Belma K, Belma K, et al. Ultrasonic harmonic scalpel in total thyroidectomies. *Adv Ther*. 2008; 25:260–5.
6. Voutilainen PE, Haglund CH. Ultrasonically activated shears in thyroidectomies: a randomized trial. *Ann Surg*. 2000; 231:322–8.
7. Rahbari R, Mathur A, Kitano M, Guerrero M, Shen WT, Duh QY, Clark OH, Kebebew E. Prospective randomized trial of ligasure versus harmonic hemostasis technique in thyroidectomy. *Annals of surgical oncology*. 2011;18:1023–7.
8. Takao S, Shinci H, Maemura K, Aikou T. Ultrasonically activated scalpel is an effective tool for cutting the pancreas in biliary-pancreatic surgery: experimental and clinical studies. *J Hepatobiliary Pancreat Surg*. 2000; 7:58–62.
9. Siperstein AE, Berber E, Engle KL, Duh QY, Clark OH. Laparoscopic posterior adrenalectomy: technical considerations. *Arch Surg*. 2000; 135:967–971.
10. Rosato L, Avenia N, Bernante P, De Palma M, Gulino G, Nasi PG, Pelizzo MR, Pezzullo L. Complications of thyroid surgery: analysis of a multicentric study on 14,934 patients operated on in Italy over 5 years. *World journal of surgery*. 2004 Mar 1;28:271–6.
11. Bellantone R, Lombardi CP, Bossola M, Boscherini M, De Crea C, Alesina P, Traini E, Princi P, Raffaelli M. Total thyroidectomy for management of benign thyroid disease: review of 526 cases. *World journal of surgery*. 2002 Dec 1;26:1468–71.
12. Amaral JF. The experimental development of an ultrasonically activated scalpel for laparoscopic use. *Surg. Laparosc. Endosc*. 1994; 4:92–9.
13. Kanehira E, Omura K, Kinoshita T, Kawakami K, Watanabe Y. How secure are the arteries occluded by a newly developed ultrasonically activated device? *Surg Endosc*. 1999; 13:340–2.
14. Ecker T, Carvalho AL, Choe JH, Walosek G, Preuss KJ. Hemostasis in thyroid surgery: harmonic scalpel versus other techniques- a meta-analysis: *Otolaryngol Head Neck Surg*. 2010; 143:17–25.
15. McHenry CR, Speroff T, Wentworth D, Murphy T. Risk factors for postthyroidectomy hypocalcemia. *Surgery*. 1994 Oct;116:641–7.
16. Thomusch O, Machens A, Sekulla C, Ukkat J, Lippert H, Gastinger I, Dralle H. Multivariate analysis of risk factors for postoperative complications in benign goiter surgery: prospective multicenter study in Germany. *World journal of surgery*. 2000 Nov 1;24:1335–41.
17. Bliss RD, Gauger PG, Delbridge LW. Surgeon's approach to the thyroid gland: surgical anatomy and the importance of technique. *World journal of surgery*. 2000 Aug 1;24:891–7.
18. Hambley R, Hebda PA, Abell E, Cohen BA, Jegasothy BV. Wound healing of skin incisions produced by ultrasonically vibrating knife, scalpel, electrosurgery, and carbon dioxide laser. *J Dermatol Surg Oncol*. 1988;14:1213–17.
19. Armstrong DN, Ambroze WL, Schertzer ME, Orangio GR. Harmonic scalpel vs electrocautery hemorrhoidectomy: a prospective evaluation. *Dis Colon Rectum*. 2001; 44:558–64.
20. Leonard DS, Timon C. Prospective trial of the ultrasonic dissector in thyroid surgery. *Head & neck*. 2008 Jul 1;30:904–8.
21. Prgommet D, Janjanin S, Bilić M, Prstačić R, Kovač L, Rudeš M, Katić V. A prospective observational study of 363 cases operated with three different harmonic scalpels. *European archives of oto-rhino-laryngology*. 2009 Dec 1;266:1965–70.
22. Karvounaris DC, Antonopoulos V, Psarras K, Sakadamis A. Efficacy and safety of

- ultrasonically activated shears in thyroid surgery. *Head & neck*. 2006 Nov 1;28:1028-31.
23. Shemen L. Thyroidectomy using the harmonic scalpel: analysis of 105 consecutive cases. *Otolaryngology--Head and Neck Surgery*. 2002 Oct 1;127:284-8.
24. Defechereux T, Rinken F, Maweja S, Hamoir E, Meurisse M. Evaluation of the ultrasonic dissector in thyroid surgery. A prospective randomised study. *Acta Chirurgica Belgica*. 2003 Jan 1;103:274-7.
25. Miccoli P, Berti P, Dionigi GL, D'Agostino J, Orlandini C, Donatini G. Randomized controlled trial of harmonic scalpel use during thyroidectomy. *Archives of Otolaryngology--Head & Neck Surgery*. 2006 Oct 1;132:1069-73.
26. Cordon C, Fajardo R, Ramirez J, Herrera MF. A randomized, prospective, parallel group study comparing the Harmonic Scalpel to electrocautery in thyroidectomy. *Surgery*. 2005 Mar 31;137:337-41.
27. Salami A, Dellepiane M, Bavazzano M, Crippa B, Mora F, Mora R. New trends in head and neck surgery: a prospective evaluation of the Harmonic Scalpel. *Medical Science Monitor*. 2008 Apr 29;14:PI1-5.
28. D'Ajello F, Ciocchi R, Docimo G, Catania A, Ardito G, Rosato L, et al. Thyroidectomy with ultrasonic dissector: a multicentric experience. *G Chir*. 2010; 31:289-92.
29. Miccoli P, Berti P, Raffaelli MA, Materazzi G, Conte M, Galleri D. Impact of harmonic scalpel on operative time during video-assisted thyroidectomy. *Surgical endoscopy*. 2002 Apr 1;16:663-6.
30. Marchesi M, Biffoni M, Cresti R, Mulas MM, Turriziani V, Berni A, Campana FP. [Ultrasonic scalpel in thyroid surgery]. *Chirurgia italiana*. 2002 Dec;55:299-308.
31. Papavramidis TS, Sapalidis K, Michalopoulos N, Triantafillopoulou K, Gkoutzamanis G, Kesisoglou I, Papavramidis ST. UltraCision harmonic scalpel versus clamp-and-tie total thyroidectomy: A clinical trial. *Head & neck*. 2010 Jun 1;32:723-7.
32. Ortega J, Sala C, Flor B, Lledo S. Efficacy and cost-effectiveness of the UltraCision® harmonic scalpel in thyroid surgery: an analysis of 200 cases in a randomized trial. *Journal of Laparoendoscopic & Advanced Surgical Techniques*. 2004 Feb 1;14:9-12.