

Laparoscopic Cholecystectomy : Retrieval of the Gallbladder Specimen and Spilled Gallstones, Inside a Sterile Male Condom as an Endobag, Reduces the Septic Complications

Jawad Kadhim S. AL-Dhahiry

ABSTRACT:

BACKGROUND:

During the course of laparoscopic cholecystectomy .the gallbladder specimen and the spilled stones are retrieved by the formal endobag , which is not available in Iraq , or directly through the umbilical or the epigastric port .Direct retrieval of the gallbladder specimen and the spilled stones may cause contamination of the port site .

OBJECTIVE :

To evaluate the safety, cost effectiveness and incidence rates of intraperitoneal and port site infections when using a sterile male condom as an endobag for retrieval of gallbladder specimen and spilled gallstones .

METHODS :

This is a prospective study performed in AL-Karama Teaching Hospital, Medical College / Wasit University, Iraq .A total of 306 patients, with symptomatic cholelithiasis underwent Laparoscopic Cholecystectomy (LC), were included in this study performed during the period from April 2011 to June 2014. A sterile male condom was inserted through 10 mm epigastric port. The gallbladder specimen / spilled gallstones of every patient were retrieved inside a sterile male condom. Patients less than 15 years old and those with liver cirrhosis, gallbladder carcinoma and obstructive jaundice, were excluded. The follow-up period ranged from 2 to 42 months.

RESULTS:

Dissected gallbladders / spilled gallstones of the 306 patients; 279 (91.2%) were females and 27(8.8%) were males with a mean age of 39 ± 12.5 SD (range 16-75) years, were safely retrieved through 10 mm epigastric port inside male condoms.

Incidental perforation of gallbladders ,during their dissection from the hepatic bed, was observed in 11(3.6 %) patients. Perforation of the condom during retrieval of the gallbladder specimens/spilled stones occurred in 12(3.8%) patients.

This study had no intraperitoneal nor port site infections. No mortality occurred during the follow-up period.

CONCLUSION:

Use of a sterile male condom as endobag for retrieval of gallbladder specimen and spilled stones is simple, inexpensive and safe technique. It also reduces the intraperitoneal and port site septic complications .

KEY WORDS: Laparoscopic cholecystectomy, Condom endobag, Gallbladder specimen retrieval.

INTRODUCTION:

Laparoscopic cholecystectomy is considered worldwide the “gold standard” in the surgical treatment of symptomatic cholelithiasis and acute cholecystitis because it offers well-known and more definite advantages in comparison with open cholecystectomy ^[1].

Laparoscopic cholecystectomy may be performed by single, two, three or four port (3,5 and 10mm size) technique depending on the surgeon's choice. Endoscopes and long handle instruments are introduced into the body through an insertion port site. At the end of the procedure, proper positioning of instruments (rail roading) and orientation are required for retrieval of gallbladder specimen ^[2] .

Department of Surgery, AL-Karama Teaching Hospital, Medical College/ Wasit University / Wasit - Iraq .

RETRIEVAL OF THE GALLBLADDER Specimen

Intraperitoneal spillage of bile and gallstones and later implantation of gallstones, during dissection the gallbladder off its liver bed and its retrieval without endobag, are documented complications [3,4].

In order to prevent above complications, gallbladder specimen and the spilled gallstones are retrieved in an endobag, usually through umbilical port. Distended gallbladders that are packed with stones always create a problem during their retrieval from the abdomen. Gallbladder removal in these cases required a needle decompression, stone fragmentation and stone removal from the gallbladder near the port site or enlargement of the one of the fascial incision to facilitate gallbladder retrieval, which causes more postoperative port site pain [5]. This study evaluates; the safety, the cost effectiveness and the septic complications of technique of using the sterile male condom as endobag for retrieval of gallbladder specimens and the spilled gallstones.

PATIENTS AND METHODS:

A total of 306 patients with symptomatic cholelithiasis admitted to the department of surgery/AL-Karama Teaching Hospital/ College of Medicine / Wasit University , were included in this study from April 2011 to June 2014. Children, cirrhotic patients with cholelithiasis, gallbladder carcinoma, obstructive jaundice and cases converted to open technique were excluded from this study. After the procedure was explained for each patient, an informed consent was obtained from his/her and kept the medical record. Patients, after baseline investigations and anesthesia fitness, underwent the conventional LC with four port technique. In all patients gallbladders were retrieved through epigastric port inside a sterile

male condoms that was made of natural Latex (Carex,made by Karex Industries Sdn. Bhd, Malaysia). All patients were given Cefotaxime prophylaxis 1gm / 8 hourly,three doses ,the first dose was routinely given at time of induction of anesthesia. I routinely get the laparoscopic access by direct primary trocar insertion prior to pneumoperitoneum without using Verres needle nor any optic or open technique.

The Technique

A sterile male condoms , used for contraception and prevention of sexually transmitted disease , were used as endobags during this study. The sterilization of the condoms was bacteriologically and virologically proved .

At the completion of each LC, a sterile condom was inserted inside the peritoneal cavity through 10mm epigastric port using grasper under direct vision (Fig.1). The condom endobag was kept on the superior surface of the liver or on the omentum in acute cholecystites. The condom endobag mouth was opened and gallbladder specimen and spilled gallstones (if they were present) were put inside the condom endobag then, its mouth was closed with grasper from right axillary port

(Fig.2).The condom,while gallbladder specimen and the spilled stones were inside it, was retrieved through the epigastric port under direct vision by rail road technique (Fig.3). The condom mouth was delivered outside the abdomen through the epigastric port.The infundibulum of the gallbladder was opened, the bile in the gallbladder was sucked out, the stones were retrieved out by small sponge forceps (Fig.4). Finally, the condom with gallbladder in its lumen ,was removed out keeping the peritoneal cavity and the epigastric port clean and sterile.

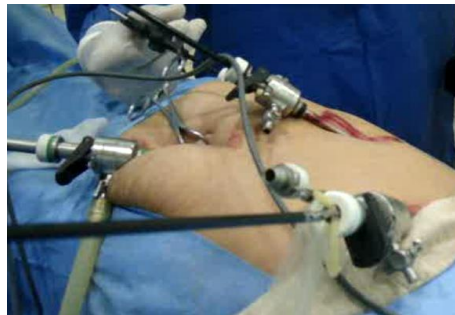

Figure 1: Insertion of condom endobag through the epigastric (retrieval) port .

RETRIEVAL OF THE GALLBLADDER Specimen

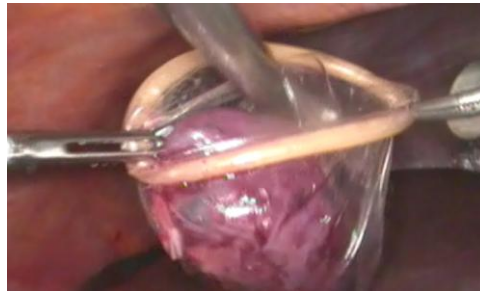


Figure 2: The dissected gallbladder being put inside the sterile condom endobag.

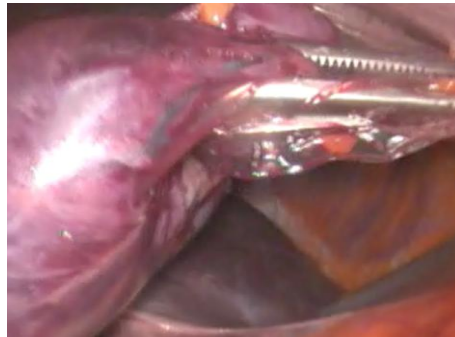


Figure 3: Getting the infundibulum outside the epigastric port to suck the bile out and retrieve the gallstones using small sponge forceps .

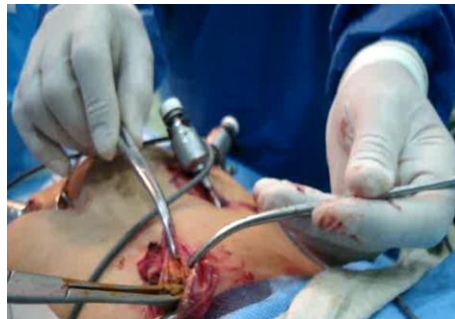

Figure 4: Retrieval of the gallstones from the gallbladder using small sponge forceps.

RESULTS:

The results of this study were statistically analysed using SPSS version 18 and tabulated in the following tables .

Table 1: Patient's Characteristics .

Patient's Characteristics	Total Number	Percentage %	Age / Year		
			Range	Mean \pm SD	P-value
Female	279	91.2 %	16- 70	38 \pm 12.02	
Male	27	8.8 %	27 -75	48 \pm 13.8	
Total	306	100 %	16 -75	39 \pm 12.5	0.001

RETRIEVAL OF THE GALLBLADDER Specimen

This study included a total of 306 patients with a mean age of 39 ± 12.5 SD (range from 16 to 75 years), as in Table.1. (91.2 %) were females and 27 (8.8 %) were males

Table 2: Patient's Distribution on Pathologic Types of Cholecystitis .

Pathologic types of Cholecystitis	Female	Male	Total number	Percentage	Age / Year	
					Range	Mean \pm SD
Chronic calculous cholecystitis	248	23	271	88.6 %	16-75	38 \pm 12.48
Acute episode of chronic calculous cholecystitis	10	2	12	3.9 %	24-54	40 \pm 11.19
Acute cholecystitis	1	0	1	0.3 %	29	29
Empyema of Gallbladder	4	0	4	1.3 %	30-70	55 \pm 17.32
Mucocele of Gallbladder	16	2	18	5.9 %	28-66	41 \pm 11.00
Total	279	27	306	100 %	16 -75	39 \pm 12.50

Table .2.shows distribution of the study patients on the pathologic types of cholecystitis: 248 (88.6%) patients presented with chronic calculous cholecystitis,12 (2.9 %) patients presented with acute attack of chronic of chronic calculous cholecystitis, one (0.3 %) patient presented with an acute cholecystitis, 4 (1.3 %) patients presented with empyema of gallbladder and 18 (5.9 %) patients presented with mucocèles of gallbladder .

Table 3:Intraoperative & Postoperative Complications of This Study .

This study Complications	Female	Male	Total	Percentage %	Age /Year	
					Mean \pm SD	P-value
Intraoperative Complications						
Bleeding	13	0	13	4.2	45 \pm 10.43	0.33
Incidental perforation of the GB* with /without Spillage of it's stones	8	3	11	3.6	42 \pm 11.7	
Perforation of the condom endobag	12	0	12	3.8	41 \pm 14.26	
Visceral injuries	0.0	0.0	0.0	0.0	0.0	
Bile duct injury	0.0	0.0	0.0	0.0	0.0	
Other Complications	0	1	1	0.3	50	
Total	33	4	37	12.08 %	39 \pm 12.5	
Postoperative Complications						
Bleeding	0	1	1	0.3	43	0.80
Bile leak	5	1	6	2.0	44 \pm 11	
Acute Bronchitis	2	0	2	0.7	35 \pm 70	
Port site infection	0.0	0.0	0.0	0.0	0.0	
Port site Hernia	0.0	0;0	0.0	0.0	0.0	
Intraperitoneal sepsis	0.0	0.0	0.0	0.0	0.0	
Total	7	2	9	3.0 %	39 \pm 12.5	

*GB= Gallbladder .

Table .3. shows intraoperative and postoperative complications of this study . Bleeding from the cystic artery, it's branches or gallbladder bed occurred in 13 (4.2%) patients with a mean age of 45 ± 10.43 SD years, P-value = 0.33. These bleeds were successfully controlled laparoscopically . Accidental perforation of gallbladders, during their

RETRIEVAL OF THE GALLBLADDER Specimen

dissection with /without spillage of stones, was observed in 11 (3.6 %) patients with a mean age of 42 ± 11.7 SD years P-value = 0.33. Perforation of the condom endobag, during retrieval of the gallbladder specimens / spilled stones, occurred in 12 (3.8 %) patients with a mean age of 41 ± 14.26 SD years, P-value = 0.33. The perforated condoms were replaced by new ones.

Postoperative bile leak occurred in 6 (2.0 %) patients with a mean age of 44 ± 11 SD years, P-value = 0.80. These bile leaks spontaneously stopped within one to 3 days postoperatively. Two (0.7 %) patients presented with acute bronchitis were successfully treated. During the follow-up period, this study showed no intraperitoneal infection, port site infection nor port site hernia. The port site fascias were not routinely closed.

DISCUSSION:

Laparoscopic cholecystectomy has been established as the “gold standard” in the treatment of symptomatic gallbladder diseases due to short hospital stay, early recovery, less postoperative pain, good cosmetic results and early return to work. Currently, more than 80% of cholecystectomies are laparoscopically performed^[6]. Spilled or implanted gallstones and spillage of infected bile in the peritoneal cavity are common events during LC without using endobag. Spillage of infected bile and gallstones in the peritoneal cavity and retrieval port site with implantation of the gallstones in the subcutaneous tissues of the abdominal wall causing discharging sinus or abscess are reported complications^[7].

This study included a total of 306 patients with symptomatic cholelithiasis; 279 (91.2 %) were females and 27 (8.8 %) were males with a mean age of 39 ± 12.5 SD (range 16-75) years. Female to male ratio was 9:1. This result is similar to study of Sajid M et al^[8], but higher than that of Amir D et al^[9] whose female: male ratio was 7:1.

In this study, bleeding from the cystic artery, its branches or gallbladder bed, occurred in 13 (4.2%) patients with a mean age of 45 ± 10.43 SD years, P-value = 0.33. These bleeds were successfully controlled laparoscopically, whereas Kapoor M et al^[10] reported bleeding rate of 1%.

In this study, incidental perforation of gallbladder during its dissection from the hepatic bed with /without spillage of stones, occurred in 11 (3.8 %) patients; 8 females and 3 males with a mean age of 42 ± 11.7 SD years, P-value = 0.33. A I Memon et al^[7] reported that gallbladder perforation occurred

in 20 (5 %) patients. However, a reported incidence of gallbladder perforation with / without gallstone spillage varies from 6 to 30 %^[2,11]. Rahim B M et al^[12] reported that perforation of gallbladder occurred in 40 % of their patients. Kapoor M et al^[10] Saud J D et al^[13] reported that perforation of gallbladder occurred in 10.7 % of their patients. Kapoor M et al^[10] reported bile spillage from gallbladder in 7 patients (2.3%).

In this study, perforation of the condom endobag occurred in 12 (3.9 %) patients with a mean age of 41 ± 14.26 SD years, P-value = 0.33. The perforated condom endobags were replaced by new ones.

In this study, there was no bile duct injury (0.0 %), whereas Amir D et al^[9] reported bile duct injury rate 1.4%, Kapoor M et al^[10] reported incidence of bile duct injury was 1.3% and Swiss 1995–2005 hospital database analysis, shows incidence rate of bile duct injury after LC was 0.3%^[14].

In this study, one patient (0.3 %) had post operative bleeding that stopped spontaneously.

This study had 6 (2.0 %) patients with postoperative bile leakage that stopped spontaneously; 5 females and one male with a mean age of 44 ± 11 SD years. This result is comparable that of Amir D et al^[9] who reported bile leak in 6 patients out of 426 (1.4 %).

This study has no intraperitoneal sepsis nor port site infection (0.0 %), whereas A.I. Memon et al^[7] reported retrieval port site infection 5 % of their patients despite using endobag. Ali SA et al^[3] and Helme et al^[15] stated that best way to avoid complications of spilled gallstones and port site contamination is to use endobag.

Karthik S et al^[16] study had retrieval port site infection 1.8 %. Taj M N et al^[17] study showed that; port site infection was 5.28 % without using endoglove, whereas it was 0.20 % when using endoglove. Turk E et al^[18] study had infection rate 1.1% despite use of Cefazolin Prophylaxis

Wound infections can be prevented by; appropriate administration of antibiotic prophylaxis, sterile techniques and the use of specimen endobags for specimen extraction^[19]. Endobag facilitates collection of operative specimens, spilled gallstones and minimizes the chances of contamination of the abdominal cavity and the retrieval port site^[19,20].

This study has no death (0.0 %), similar to Amir D et al^[9] study, whereas the basis of the 1997–2006 trend analysis by National estimates for LC in USA showed that LC was associated with a low death

RETRIEVAL OF THE GALLBLADDER Specimen

rate (mean value in the period: 0.52%) while open cholecystectomy was associated with a significantly higher rate (corresponding value: 4.9%)^[21].

Original disposable endobags prices range from 14-15 US \$ (endosac, Zenith medical), and 14 US \$ for (Dexdelac)^[22]. In Iraq, original disposable endobags are not available. The price of a single sterile male condom is about 0.12 US \$.

CONCLUSION:

I conclude that the sterile male condom endobag is simple, inexpensive and safe technique for retrieval of gallbladder specimen and spilled gallstones. It's use also, reduces the septic complications because it reduces both ; 1) spillage of bile and gallstones in the peritoneal cavity and the retrieval port site and 2) direct contact of the infected gallbladder specimen, infected gallstones and infected bile with abdominal viscera and the port site .The use of condom endobag also reduces contamination of the operative field and the port site with malignant cells in case of unexpected gallbladder carcinoma.

ABBREVIATIONS: LC: laparoscopic cholecystectomy, GB: Gallbladder .

COMPETING INTERESTS : I declare that I have no competing interests.

REFERENCES:

1. Gelmini R, Franzoni C, Zona S, Andreotti A, Saviano M . Laparoscopic Cholecystectomy with harmonic scalpel. *Journal Of The Society Of Laparoendoscopic Surgeons*. 2010 ;14:14–19 .
2. Kang K J , Lim T J. Tip for microlaparoscopic cholecystectomy, easy removal of the gallbladder after laparoscopic cholecystectomy using the three-port technique. *Surg Laparosc Endosc Percutan Tech*. 2003 ; 13:118–20.
3. Ali S A, Siddiqui F G. Implanted gallstones at port site (A Case Report) . *World J. Min. Access. Surg*. 2013;2.
4. Diez J, Arozamena C, Gutierrez L et al. Lost gallstones during laparoscopic cholecystectomy. *HPB Surg*. 1998 ; 11 :105-9. [Pubmed].
5. Zehetner J, Shamiyeh A, Wayand W. Lost gallstones in laparoscopic cholecystectomy, all possible complications. *Am. J. Surg*. 2007; 193 : 73-8.
6. Melissa M. Murphy, Shimul A. Shah, Jessica P. Simons, Nicholas G. Csikesz et al. Predicting major complications after laparoscopic cholecystectomy: a simple risk score". *Journal of gastrointestinal surgery*. 2009 ; 13:1929–36.
7. A I Memon, S A Ali, A G Soomro, A k Sangrasi, A J Siddiqui . A safe and inexpensive technique of retrieval of gallbladder specimen after laparoscopy. *Scientific Journal of Medical Science*. 2013;2: 219-24 .
8. Sajid M, Azim K, Rehman S, Saqib K. Early cholecystectomy for acute cholecystitis: our experience. *Professional Med J*. 2014;21:10-15.
9. Amir D, Amin N. Frequency of complications due to laparoscopic cholecystectomy in Hamedan Hospitals . *J Pak Med Assoc* .2012 ; 62:13- 15 .
10. Kapoor M, Yasir M, Umar A, Suri A, Aiman A, Kumar A. Complications of laparoscopic cholecystectomy; analysis of 300 patients. *JK-Practitioner*. 2013;18:7-11.
11. Machado M.A.C, Herman P.A. Simple technique for removal of galbladder during microlaparoscopic cholecystectomy. *Surg.Endosc*.2004;18 :1289-90.
12. Rahim B M, Jawaid RM, Syed R M. Cholecystectomy: Fate of spilled bile with gallstones during laproscopic cholecystectomy. *Professional Medical Journal*. 2011;18:361.
13. Saud J D , Abdulla M A, Abu-Alhail M C. Spilled gallstones during laparoscopic cholecystectomy : a prospective study . *Bas J Surg*. 2011;17:65-71.
14. Agabiti N, Stafoggia M, Davoli M, et al .Thirty-day complications after laparoscopic or open cholecystectomy: a population-based cohort study in Italy. *BMJ Open* . 2013;3:e001943. doi:10.1136/bmjopen-2012-001943
15. Helme S, Samdani T, Sinha P. Complications of spilled gallstones following laparoscopic cholecystectomy; a case report and literature overview. *J. Med. Case. Reports*. 2009;3:8626.
16. Karthik S, Augustine A J, Shibumon M M, Pai M V. Analysis of laparoscopic port site complications: A descriptive study. *Journal of Minimal Access Surgery* . 2013; 9:59-64 .

17. Taj M N, Iqbal Y, Akbar Z .Frequency And Prevention Of Laparoscopic Port Site . *J Ayub Med Coll Abbottabad*. 2012;24:197-99 .
18. Turk E, Karagulle E, Serefhanoglu K , Turan H, Moray G.Effect of cefazolin prophylaxis on postoperative infectious complications in elective laparoscopic cholecystectomy: a prospective randomized study. *Iranian Red Crescent Medical Journal*. 2013; 15: 581-86.
19. Sathesh-Kumar T, Saklani A P, Vinayagam R, Blackett R L. Spilled gallstones during laparoscopic cholecystectomy, a review of literature. *Postgrad Med. J*. 2004; 80 :77-79.
20. Raj P K, Katris F, Linderman C G , Remine SG. An inexperience laparoscopic specimen retrieval bag. *Surg. Endosc*. 1998; 12: 83.
21. Dolan JP, Diggs BS, Sheppard BC et al.The national mortality burden and significant factors associated with open and laparoscopic cholecystectomy 1997–2006. *J Gastrointest Surg*. 2009;13:2292–301 .
22. Bisgaard T, Klarskov B, Trap R, Kehlet H, Rosenberg J. Microlaparoscopic vs conventional laparoscopic cholecystectomy; a prospective randomized double-blind trial. *Surg. Endosc*. 2002 ; 16: 458–64 .