

HETEROTOPIC OSSIFICATION OF THE ABDOMINAL WALL

Issam Merdan* & Haider M Mahmood#

*MB,ChB, CABS, FICMS, Professor of Surgery, Dept. of Surgery, Basrah Collage of Medicine, IRAQ.

#MB,ChB, Iraqi Board Candidate, Al-Sadir Teaching Hospital

Abstract

Heterotopic ossification is a rare and benign condition which occurs when bone develops in tissues that do not normally ossify.

We report a 53-year-old man who underwent laparotomy for recurrent pyloric obstruction. A segment of abnormal hard tissue was found in the abdominal wall and so was excised. Histopathology revealed metaplastic bone deposition.

Heterotopic ossification may occur at various sites and is a recognized but infrequent sequela of abdominal surgery. This case highlights clinical, aetiological and histopathological features of this rare finding.

Introduction

Heterotopic ossification (HO) is an uncommon entity, first described by Riedel in 1883 as a complication after spinal cord injury^{1,2}. This phenomenon may occur in a variety of sites including skin, subcutaneous tissue, skeletal muscle, mesentery and fibrous tissue^{3,4}. The spectrum of disease is wide with lesions ranging from minute foci of ossification to large clinically significant deposits. Considering the large volume of abdominal surgeries performed annually worldwide, the incidence of this condition in abdominal scars is extremely low. Although infrequently reported, this pathology is long recognized, with the first case of heterotopic calcification in an abdominal scar reported by Askanazy as far back as 1901^{5,6}. Given its rarity, the lack of conclusive data regarding incidence is unsurprising. Similar discordance exists regarding potential aetiology. There is agreement in the literature, however, regarding a marked male preponderance⁷

and confinement to vertical abdominal scars⁶. The case reported herein is in keeping with these patterns.

Case Presentation

A 53-year-old man with chronic history of peptic ulcer on irregular treatment, and with previous history of surgery for pyloric obstruction (pyloroplasty) three months ago, presented to the Accident and Emergency Department with a 4 day history of upper abdominal pain and repeated vomiting. After admission to the hospital and resuscitation, he was prepared for upper endoscopy which revealed complete obstruction of pylorus with dilated stomach. A decision for surgery was made to revise the obstruction.

A midline vertical incision incorporating scar of previous surgery was made (the previous scar looks to be extended to the xiphisternum). Two pieces of hard calcified tissue were noted in the abdominal wall (Figures 1&2) involving the previous laparotomy scar.

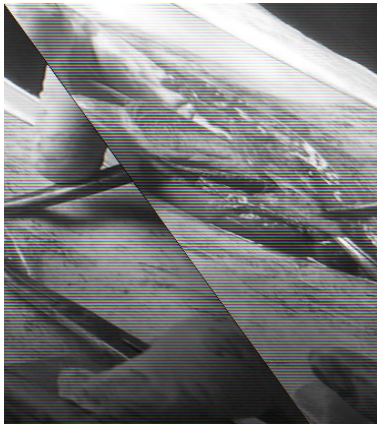


Figure 1

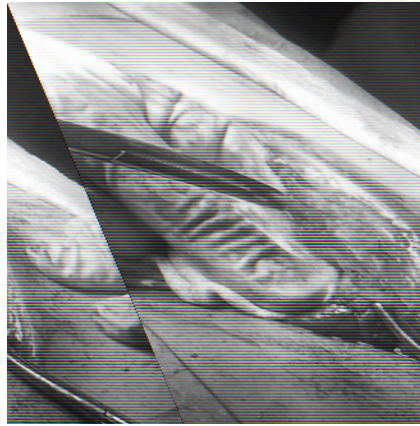


Figure 2

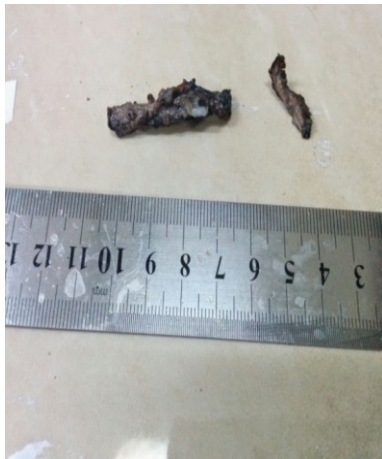

Figure 3

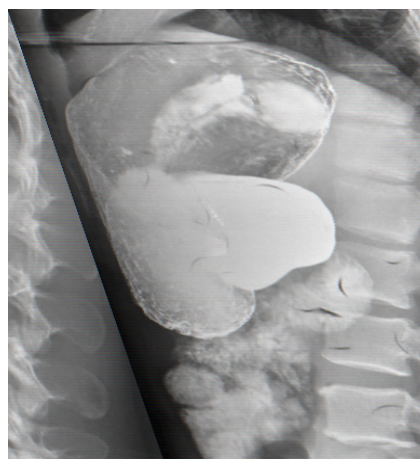

Figure 4

These pieces were excised (Figure 3) and a gastro-jejunostomy was done. Actually, on revision of the patient's contrast film of the abdomen (Barium meal) (Figure 4), it was hardly to see some form of thickening or calcification at the site of previous surgery (midline laparotomy incision). The patient had an uneventful recovery and was discharged home well on the fourth post-operative day. Histopathology of these two pieces revealed the presence of metaplastic bone consisting of mature bone trabeculae.

Discussion

Heterotopic ossification is a metaplastic phenomenon defined as abnormal deposition of mature, lamellar bone in soft tissues which do not normally ossify. The etiology may be broadly subdivided into

traumatic, neurogenic and genetic¹. Given the site and previous history of abdominal surgery, this case falls into the former category (traumatic). Heterotopic ossification within an abdominal incision is rare. Since no true estimate of incidence is available, the available evidence is based on findings of isolated case reports⁸ and small series^{6,9-11}.

A striking male preponderance is evident with male–female ratio estimated to be as high as 10:1¹⁰. This pathology has only ever been reported in vertical midline scars as is the case in our patient. Generally, ectopic bone formation appears to occur within the first year after surgery. In our case, only 3 months had elapsed since the first laparotomy. Morbidity is primarily a function of the anatomic location of the

ossification. In our case, the patient was asymptomatic.

The literature is in agreement that four factors are necessary for the pathogenesis of ectopic bone¹⁰. Firstly, a trigger or inciting event must be present. In our case, this is likely to be the initial laparotomy. Secondly, a signal must emanate from the site of injury. This factor has been reported to be the most crucial step and many agents, including bone morphogenic proteins have been implicated as potential signalling vehicles⁴. Thirdly, a supply of uncommitted mesenchymal cells is necessary. Mesenchymal stem cells (MSCs) are a remarkable group of non-hematopoietic, multipotent cells which make up a very small percentage (0.01%) of the population of nucleated cells in the bone marrow¹². They are known to home to sites of injury and, given the appropriate signals, can differentiate into many different cell types including osteoblasts or chondroblasts¹³. This process has been referred to as osteogenic induction to highlight the acquisition of osteogenic properties in these

cells which are not normally associated with the formation of bone⁶. Finally, a permissive environment for this process is necessary. It has also been postulated that fragments of periosteum or perichondrium may be liberated from the xiphisternum or symphysis pubis intra-operatively and transposed to a site along the wound, thus inoculating the scar^{1,4}. This theory is supported by the fact that heterotopic bone formation has only ever been reported in vertical abdominal scars. In our case, the previous incision was extended to the xiphisternum. Furthermore, this theory fails to account for heterotopic ossification which occurs at sites with no anatomic relationship to osseous tissue.

Heterotopic ossification in the abdominal wall is a rare pathology, many aspects of which are yet to be elucidated. Regardless of aetiology, the literature is in agreement that, in symptomatic patients, treatment should consist of complete excision with primary closure⁴. Generally, asymptomatic patients should be excluded from treatment.

References

1. T.A. Balboni, R. Gobezie, H.J. Mamon. Heterotopic ossification: pathophysiology, clinical features, and the role of radiotherapy for prophylaxis. *International Journal of Radiation Oncology, Biology, Physics*, 65 (5) (2006), pp. 1289–1299.
2. F.F. Naraghi, T.A. DeCoster, M.S. Moneim, R.A. Miller, D. Rivero. Heterotopic ossification. *Orthopedics*, 19 (2) (1996), pp. 145–151.
3. M. Hakim, E.F. McCarthy. Heterotopic mesenteric ossification. *American Journal of Roentgenology*, 176 (1) (2001), pp. 260–261.
4. E.F. McCarthy, M. Sundaram. Heterotopic ossification: a review *Skeletal Radiology*, 34 (10) (2005), pp. 609–619
5. A. Lehrman, J.H. Pratt, E.M. Parkhill. Heterotopic bone in laparotomy scars. *American Journal of Surgery*, 104 (1962), pp. 591–596.
6. M.J. Reardon, A. Tillou, D.R. Mody, P.R. Reardon. Heterotopic calcification in abdominal wounds. *American Journal of Surgery*, 173 (2) (1997), pp. 145–147.
7. M. Rosa, A. Mohammadi. Myositis ossificans traumatica of the abdominal wall. *Canadian Journal of Surgery*, 52 (2) (2009), pp. E33–E34.
8. F. Nilsson, N. Simonsson. Heterotopic bone formation in upper midline abdominal incisions. *Acta Chirurgica Scandinavica*, 143 (7–8) (1977), pp. 435–437.
9. J.E. Jacobs, B.A. Birnbaum, E.S. Siegelman. Heterotopic ossification of midline abdominal incisions: CT and MR imaging findings. *American Journal of Roentgenology*, 166 (3) (1996), pp. 579–584.
10. F.S. Kaplan, D.L. Glaser, N. Hebel, E.M. Shore. Heterotopic ossification. *Journal of the American Academy of Orthopaedic Surgeons*, 12 (2) (2004), pp. 116–125.
11. S. Orava, E. Tallila, T.K. Larmi. Heterotopic ossification in upper midline abdominal scars. *Annales Chirurgiae et Gynaecologiae*, 69 (3) (1980), pp. 115–118.
12. M.F. Pittenger, A.M. Mackay, S.C. Beck, R.K. Jaiswal, R. Douglas, J.D. Mosca, et al.. Multilineage potential of adult human mesenchymal stem cells. *Science*, 284 (5411) (1999), pp. 143–147.
13. G. Chamberlain, J. Fox, B. Ashton, J. Middleton. Concise review: mesenchymal stem cells: their phenotype, differentiation capacity, immunological features, and potential for homing.