

IMMEDIATE HIP SPICA FOR FRACTURE OF SHAFT OF FEMUR IN PEDIATRICS

Jasim Hasan

Consultant Orthopaedic Surgeon, Department Of Surgery, Al Muthana Medical College & Al-Husain Teaching Hospital, IRAQ.

Abstract

This is a prospective study performed on 20 children with isolated fracture shaft femur between January 2010 to December 2010 at Al-Husain Teaching Hospital in Al-Samawa city. They were 12 boys and 8 girls, their age ranged between 1 to 6 years(average 3.2).

All patients were treated by immediate single leg spica as an outpatient technique. This study found that immediate hip spica casting and discharging to home is associated with few complications, no functional limitation and minimal limb length inequality.

Introduction

The most common paediatric orthopaedic injury requiring hospitalization is a femur fracture¹.

Fortunately most of femur fractures in children result in good outcome. Almost all unite rapidly, regardless of the fracture type, location, or treatment. Femoral fractures in children are common, with annual rates of roughly 20 per 100000^{2,3}.

A variety of treatment methods exist, including spica casting with or without traction, external fixation, flexible or rigid intramedullary nailing and plate fixation. Psychological and social effects play a role in selecting optimal treatments.

Patients and Methods

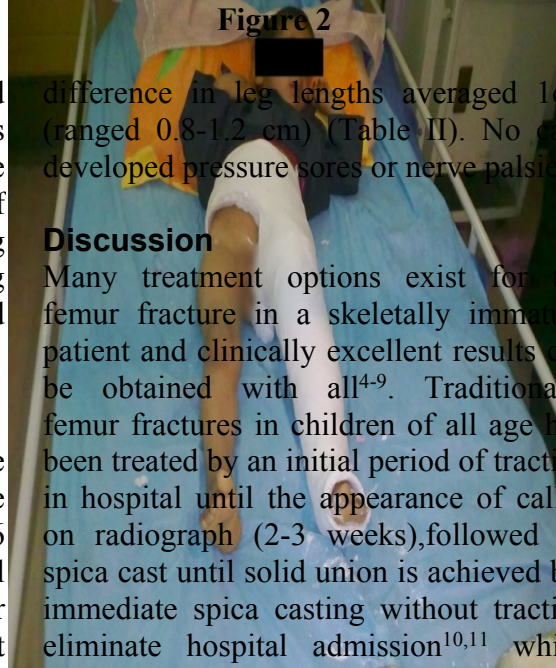
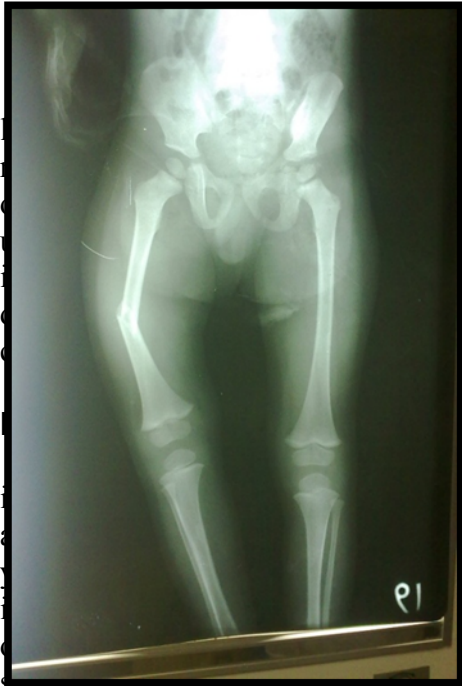Twenty children with isolated closed shaft femur fractures were treated from January 2010 to December 2010 at Al Husain Teaching Hospital. They were 12 males and 8 females, their ages ranged between 1 to 6 years (average 3.2). Immediate single leg spica after closed reduction was done as outpatient technique under intravenous diazepam.

Child was discharged to home and followed every 2 weeks by clinical and radiological measures till removal of spica which need 4-8 weeks then monthly for one year.

Technique

A single spica cast was performed under intravenous diazepam (1 mg per year of age) in the outpatient clinic. The patient is placed on a spica table and an assistant holds the lower extremities while we place the cast thorough padding with cotton especially over bony prominences, is essential to prevent skin ulceration under the cast. Two assistants were needed; one to hold the lower limbs straight through continuous traction and the other to stabilize the patient's chest and shoulders. Without fluoroscopy, the surgeon performed gentle closed reduction using manual traction to restore the general alignment and length of the injured limb to match the sound side. The injured limb was kept straight at hip and knee with the ankle joint in neutral position, it was abducted 30-40° and spica applied from just below nipples to foot keeping the limb in neutral rotation throughout the

procedure (Figures 1 & 2). This process needed about 20-30 minutes.



Injured leg was... are... if... nursing... child... s were... The... 1 to 6... as fall... body or... Right... side affected in 15 cases (65%) while left side in 7 cases (35%). The most common type of the fracture was spiral in 12 cases, transverse in 4, oblique in 2, segmental in one and greenstick fracture in one case. The middle third of femur is the most common site to be involved in 17 cases. Average time in cast was 6 weeks (range 4 to 8 weeks). Average time to union was 6 weeks. One cast required wedging during treatment. The casts of three patients broke at the hip joint due to improper hygiene requiring reinforcement. There was no rotational malunion. Mild degrees of knee joint stiffness were reported at time of spica removal in all patients with limping which had responded fully to home exercises. Three children had a

difference in leg lengths averaged 1cm (ranged 0.8-1.2 cm) (Table II). No case developed pressure sores or nerve palsies.

Discussion

Many treatment options exist for the femur fracture in a skeletally immature patient and clinically excellent results can be obtained with all⁴⁻⁹. Traditionally femur fractures in children of all age had been treated by an initial period of traction in hospital until the appearance of callus on radiograph (2-3 weeks), followed by spica cast until solid union is achieved but immediate spica casting without traction eliminate hospital admission^{10,11} which consider a major advantage in our locality nowadays because our people refuse leaving their home for long time in addition to that it avoid the risk of skin or skeletal traction and allows rapid return of patient to the family environment. Overall spica casting is simple, save and effective. It avoid the risk of surgery and require no specialized tool, or implants. The success of this technique is facilitated by the fact that infant and children have a tremendous ability to remodel the deformities that remain after closed treatment¹²⁻¹⁴.

The major disadvantage of spica casting are the result of prolonged immobilisation and cast pressure sore especially in the back area and this can be prevented by well moulded spica.

Table I: Details of patients included in this study

Gender		Side		Site of fracture			Type of fracture					Mechanism of injury		
M	F	R	L	Upper 1/3rd	Middle 1/3rd	Lower 1/3rd	Spiral	Oblique	Transverse	Greenstick	Segmental	Fall to ground	Heavy object fall on body or limb	RTA
12 60%	8 40%	13 65%	7 35%	2 10%	17 85%	1 5%	12 60%	2 10%	4 20%	1 5%	1 5%	15 75%	4 20%	1 5%

Table II: The results at time of spica removal

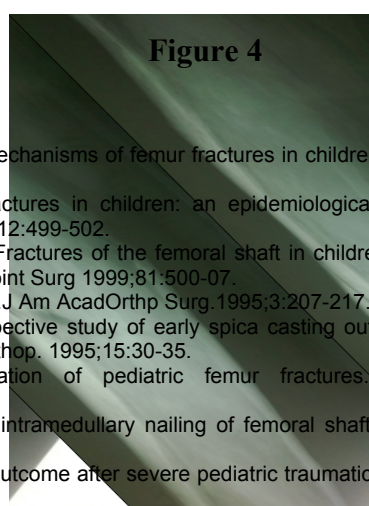
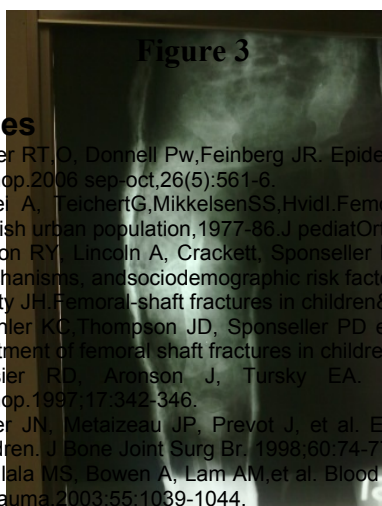
Clinically after removal of spica	No.	%
Limping	20	100
Shortening ≤ 2cm	3	15
Knee stiffness	20	100

Excessive shortening is the most common early complications of spica casting and to detect it early, needs close follow up especially in first 2-4 weeks after cast application¹⁵. In this study, such problem did not faced and 1 cm shortening in average can be accepted (3 cases).

Angulation may occur as well and if unacceptable it may require the cast to be wedged or replaced. In patients included in this study, one case needed wedging after 2 weeks due to varus angulation (Figures 3 & 4) so we advise to reduce the

fracture in slight valgus (5-10°) from the start to counteract the fracture tendency to go in varus as preventive measure. In this study, treatment with immediate hip spica cast, all femoral fractures united in 4-8 weeks with no significant residual disabilities and this supported by Nork et al and Casas et al studies^{16,17}.

In conclusion the immediate single leg spica cast can safely and effectively be used to manage femur fractures in young children (up to age 6 years).



References

1. Loder RT, O, Donnell Pw, Feinberg JR. Epidemiology & mechanisms of femur fractures in children. J Pediatr Orthop. 2006 sep-oct;26(5):561-6.
2. Nafei A, Teichert G, Mikkelsen SS, Hvidt. Femoral shaft fractures in children: an epidemiological study in a Danish urban population, 1977-86. J pediatr Orthoped 1992;12:499-502.
3. Hinton RY, Lincoln A, Crackett, Sponseller P, Smith G. Fractures of the femoral shaft in children: incidence, mechanisms, and sociodemographic risk factors. J Bone Joint Surg 1999;81:500-07.
4. Beatty JH. Femoral-shaft fractures in children & adolescents. J Am Acad Orthp Surg. 1995;3:207-217.
5. Buchler KC, Thompson JD, Sponseller PD et al. A prospective study of early spica casting outcome in the treatment of femoral shaft fractures in children. J Pediatr Orthop. 1995;15:30-35.
6. Blasler RD, Aronson J, Tursky EA. External fixation of pediatric femur fractures. J Pediatr Orthop. 1997;17:342-346.
7. Ligier JN, Metaizeau JP, Prevot J, et al. Elastic stable intramedullary nailing of femoral shaft fractures in children. J Bone Joint Surg Br. 1998;60:74-77.
8. Vavilala MS, Bowen A, Lam AM, et al. Blood pressure & outcome after severe pediatric traumatic brain injury. J Trauma 2003;55:1039-1044.
9. Kanlic EM, Anglen JD, Smith DG, et al. Submuscular bridge plating for the treatment of pediatric femur fractures. Clin Orthop. 2004;426:244-251.
10. Irani RN, Nicholson JT, Chung MK. Long term results in the treatment of femoral-shaft fractures in young children by immediate spica immobilization. J Bone Joint Surg Am. 1976;58:945-951.
11. Infante AF Jr, Albert MC, Jennings WB, et al. Immediate hip spica casting for femur fractures in pediatric patients. A review of 175 patients. Clin Orthop. 2003;376:106-112.
12. Macnicol MF. Fracture of the femur in children. J Bone Joint Surg. 1997;79B:891-92.

13. Shapiro F. Fractures of the femoral shaft in children. The overgrowth phenomenon. *Acta Orthop Scand.* 1981;52:649-655.
14. Viljanto J, Kwiluoto H, Paananen M. Remodeling after femoral shaft fracture in children. *Acta Chir Scand.* 1975;141:360-365.
15. Martinez AG, Carroll NC, Sarwark JF, et al. Femoral shaft fractures in children treated with early spicacast. *J Pediatr Orthop.* 1991;11:712-716.
16. Nork SE, Bellig GJ, Woll JP, et al. Overgrowth & outcome after femoral shaft fracture in children younger than two years. *Clin Orthop.* 1999;357:186-91.
17. Casas J, Gonzalez-Morgan G, Albinana J. Femoral fractures in children from 4 years to 10 years: Conservative treatment. *J Pediatr Orthop B.* 2001;10:56-62.