

RADIOLOGICAL & EVALUATION STUDY OF SOME MINERAL COMPONENT TO EFFECT OF MEDIAN NEUROECTOMY OF THE MID-SHAFT OF METACARPAL BONE IN FORE-LIMB IN DONKEYS

Abdullbari A. Alfaris* Alaa A. H. Sawad** Ali kareem M. Al-Atrakchi*

*Department of surgery & obstetrics, College of Veterinary Medicine, University of Basrah. Basrah-Iraq.

**Department of anatomy, College of Veterinary Medicine, University of Basrah. Basrah-Iraq.

(Received 20 October 2014 ,Accepted 19 January 2014)

Keywords; neuroectomy, Metacarpal ,callus.

ABSTRACT

The present study assigns the effect of neuroectomy to bone healing of experimentally induce bone fracture in 3rd metacarpal bone ,in donkeys by macroscopic, radiographic and evaluation of mineral levels(ca,p).

Sixteen donkeys of male sex with the age 1.5- 2 years, weighting 125-150 kg. were used for this study. These animals were healthy clinically. The donkeys were divided randomly into two groups(non- neuroectomized and neuroectomized) eight donkeys each group. The animals anaesthetized with xylazine Hcl at dose 0.5 mg/kg. B.W., then injectable Ketamine Hcl at the dose 3 mg/kg B.W. which administered intravenously.

The animals of non- neuroectomized group, induced one fracture at the mid of the shaft of 3rd metacarpal bone. Evaluated with clinical signs macroscopical, estimation of level of mineral and radiographic examination. Gross examination swelling in the site of fracture and lameness. The callus formation shows in radiographic examination. The calcium concentration was highly significant increase after 30th and 60th days , which the phosphorus level increase after 30th days and then decrease at 60th days.

The neuroectomized group were median neuroectomy in right plexus forelimb ,and then after 30th days induce fracture in metacarpal bone in left side. The right side neuroectomized cause paralysis and no ability to bear the weight and the site of fracture

was no callus or very little and the line of fracture is clear in radiographically examination and clinically . The calcium mineral level was highly significant decrease in relation to time. While The phosphors level were increase after 30th days and decrease on 60th days, The neuroectomized groups show decreased at the osteoblasts and increased of osteoclasts and the trabecular when compared with non- neuroectomized group with the aggregation of nests cells.

The conclusion of this study demonstrate the effectiveness of neuroectomized in delay bone healing and reduce the callus formation compared with non- neuroectomized group.

INTRODUCTION

Neuroectomy is a surgical procedure that destroys one of the nervous system. The procedure is performed to increase the blood flow and decrease long-term pain in certain diseases that cause narrowed blood vessels. It can also be used to decrease excessive sweating. This surgical procedure cuts or destroys the nerve which are collections of nerve cell bodies in clusters along the thoracic or lumbar spinal cord [1]. Nerve is closed such as cable package of axles (a long, slender projections of neurons) in the peripheral nervous system . Provides a common neural pathway for the electrochemical nerve impulses transmitted along each of the axons to peripheral devices. In the central nervous system, it is known that structures similar to the spaces called neurons. Each nerve is a cordlike structure contains many of the themes also called nerve fibers [2]

The aims of the study include determine the effect of neuroectomized on bone healing, also to evaluate the effect of calcium and phosphorus level in the bones, and to measure the approximate time for healing of the bone fracture in neuroectomized.

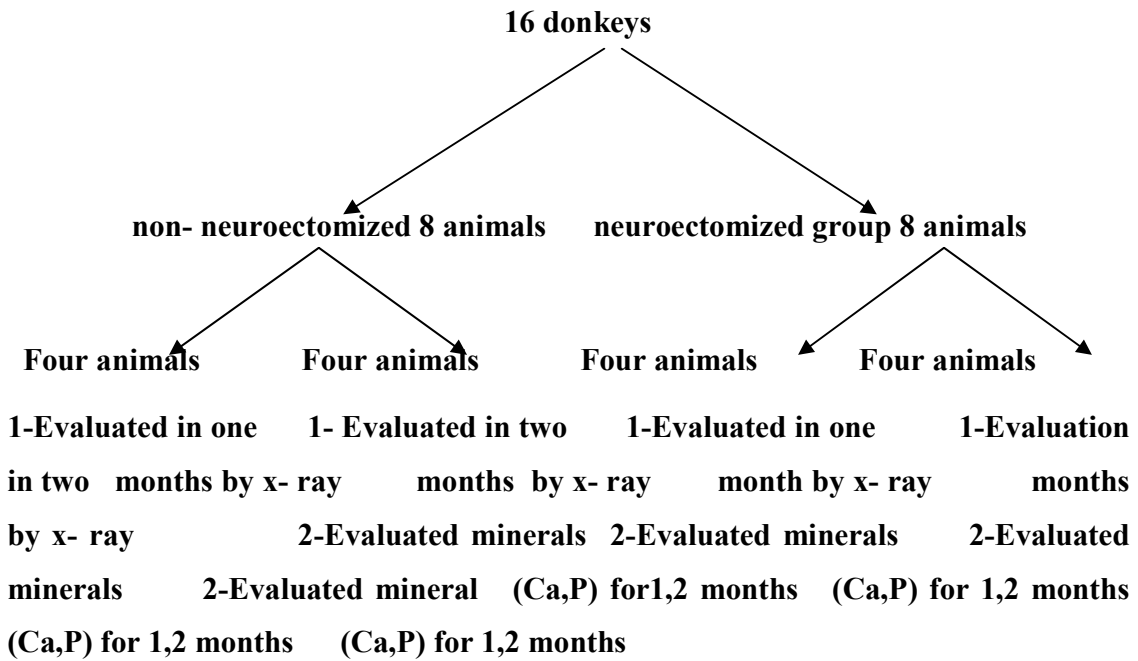
MATERIALS AND METHODS

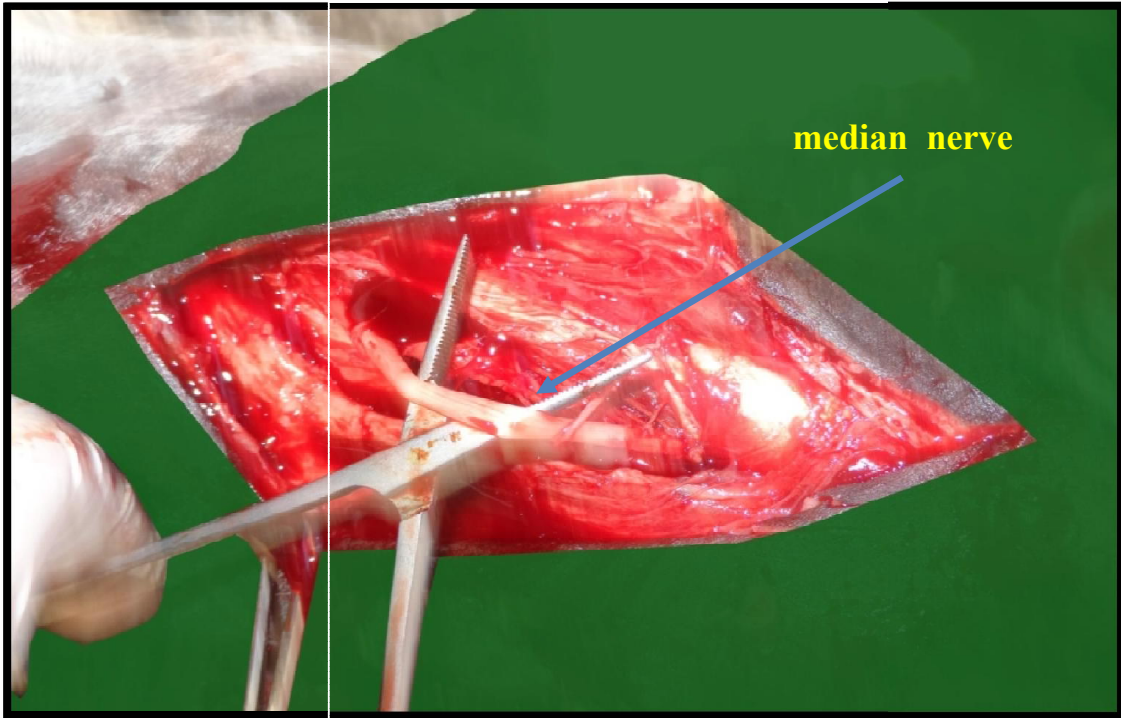
Sixteen donkeys of both sexes, age between 1.5 – 2 years, with bodyweight of 125 – 150 kg, were used in this study. The animals were divided randomly into two groups(non- neuroectomized and neuroectomized) eight donkeys in each group, and each four donkeys in subgroup (fig.(1)).

Neuroectomized group get Sedation via intravenous injection of

xylazine Hcl at the dose 0.5 mg/kg., also the animals were injecting by ketamine Hcl at the dose 3 mg/kg.[3].Induce surgical wound longest (7 cm) in the skin and medial head of triceps brachial muscle to reach the median nerve (fig.(2)), and then separated the nerve sites surrounding it and then be cutting the median nerve near the axilla(fig.(3)). one month after cutting the nerve induces transverse fracture in 3rd metacarpal bone and make external fixation by Gipson.In non-neuroectomized group breakage events are filled directly in the same 3rd metacarpal bone without causing neuroectomy and have radials followed the cases during the period of 30th days, and described in the X-ray images the same cases at 60th days, also we check the clinical signs (swelling, paralysis, lameness...) and we tested the level of minerals (Ca, P) in serum in non-neuroectomized and neuroectomized groups before and after 30th,60th days.

Figure (1) The diagram of the study designs





Figure(2) Show: The median nerve in fore limb

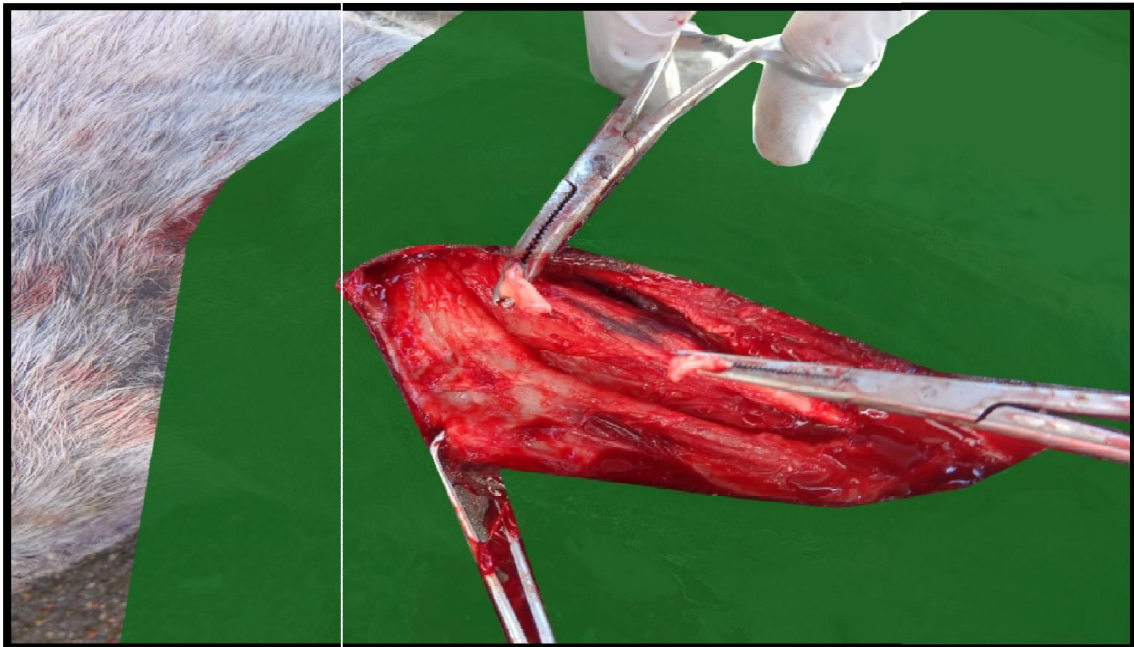


Figure (3) show: median nerve after cutting

RESULTS

Clinical observation

In the palpation the 3rd metacarpal region of non-neuroectomized group on 30th days showed the structure in the site of fracture seem the callus was clear, but in neuroectomized group is palpated very little of amount callus in site of fracture.

Radiological finding

The radiography of the 3rd metacarpal region (site of fracture), was done routinely at 30th and 60th days post-operative to assess the development bone healing by evaluation the callus composition by x- ray machine. The limbs were evaluated by radiographs detect bone formation within 30th and 60th days.

In non-neuroectomized group the radiography performed at the 3rd metacarpal region of the left fore- limb at 30th days post -operative showed the callus formation. It is clear in x-ray, line of bone fracture is clear not disappear (fig.(4)), but on 60th days the callus composed in large amount and the line fracture is disappear (fig.(5)). In neuroectomized group the radiographic signs show on 30th days no callus or in simple cases is very rare composed and very clear the line bone fracture(fig.(6)), But on 60th days, also the callus is not quantities amount is sufficient for healing, the line fracture is also clear(fig.(7)).

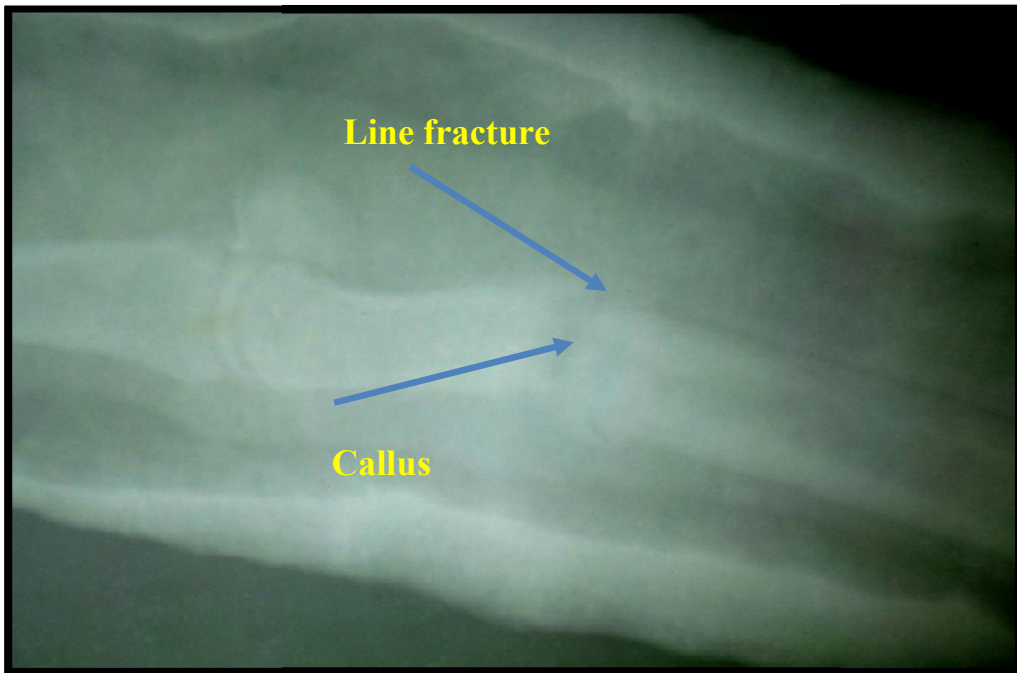
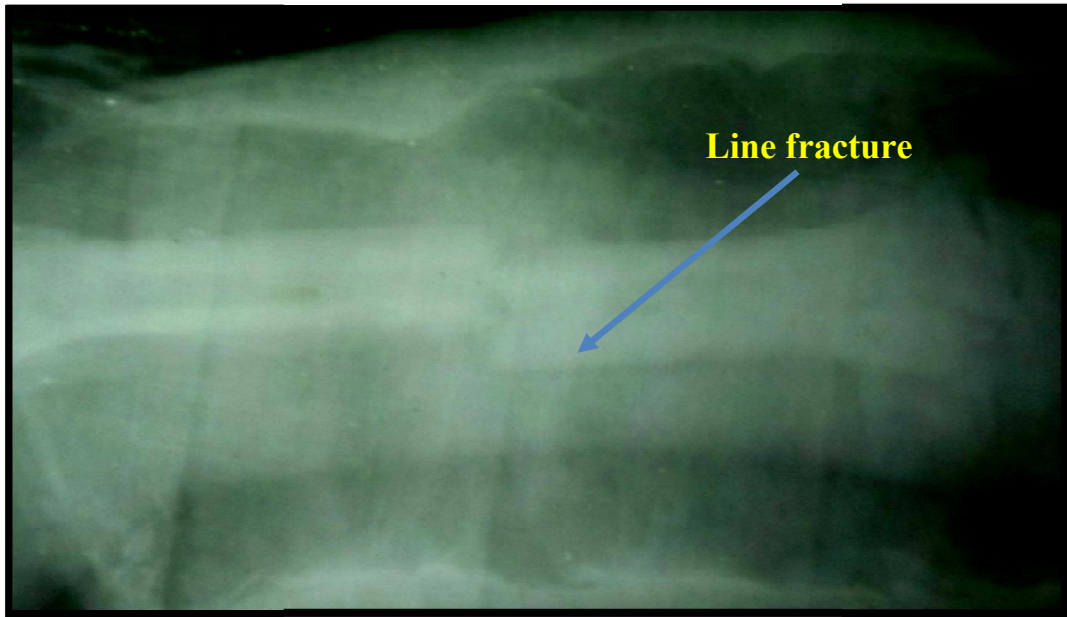


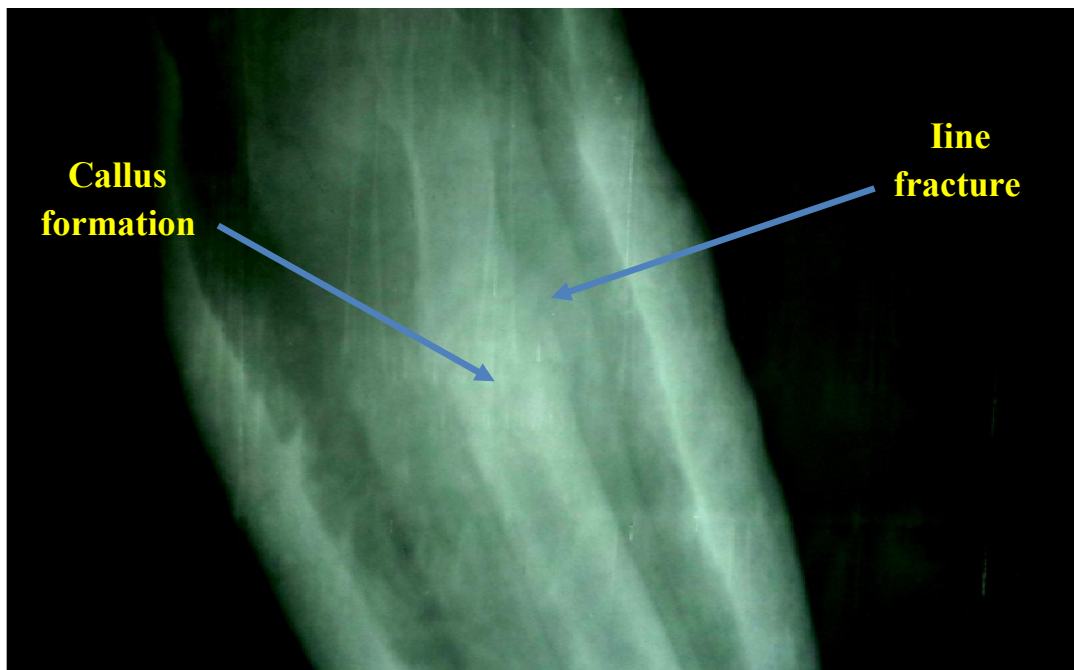
Figure (4) radiographic picture of the 3rd metacarpal bone for non-neuroectomized group on 30th days

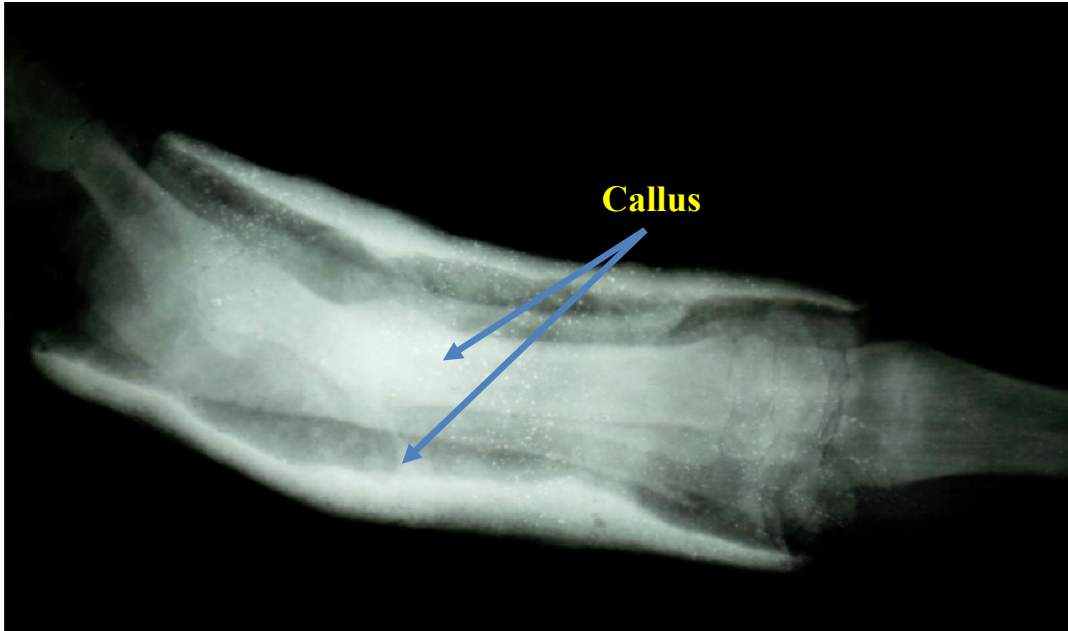

Figure (5) radiographic picture of the 3rd metacarpal bone for non-neuroectomized group on 60th days



Figure(6) radiographic picture of the 3rd metcarpal bone for neuroectomized group on 30th days



Figure(7) radiographic picture of the 3rd metcarpal bone for neuroectomized group on 60th days

Level of minerals in serum

Level of calcium (Ca

In neuroectomized group, there was decrease in Calcium concentration after 30th days, the same result was reported after 60th days.

In non- neuroectomized group the calcium concentration was highly significant increase after 30th and 60th days.

The results of the present study show that there was significant difference in the mean of Calcium concentration between neuroectomized and non- neuroectomized group before the experiment.(table-1)

Table 1: Calcium value in neuroectomized and non- neuroectomized groups

	before	30 th	60 th	P value
Control group	2.75 ± 0.04 a	3.22 ± 0.17 a	3.02 ± 0.25 a	0.001
Treated group	2.08 ± 0.02 b	1.43 ± 0.21 b	1.03 ± 0.046 b ¹	0.008
P value	0.002	0.0006	0.0001	

Level of phosphorus (P

In neuroectomized group, there was decrease of Phosphorus concentration After 30th days, the same result was reported after 60th days.

In non- neuroectomized group the Phosphorus concentration was highly significant increase after 30th and continue to decrease at 60th days.

The results of the present study show that there was a significant difference in the mean of Phosphorus concentration between treated and control group before the experiment. (table-2)

Table (2) Phosphorus value in neuroectomized and non- neuroectomized groups

	Before	30th	60th	P value
Control group	1.53± 0.15 a	2.70±0.57 b	2.65± 0.40 c	0.009
Treated group	1.10±0.18 b	2.50± 0.41 b	2.55±0.66 c	0.002
P value	0.037	Not significant	Not significant	

DISCUSSION

This study demonstrates that bone union following experimental osteotomy was faster in normal non-neurectomized group compared to the neuroectomized animals, that is agree with [4]. In contrast, the healing bone the fast by bridging callus parties in denervated than in the non-neuroectomized group that's agree with [5]. Who demonstrated that the formation of callus in the limbs denervated was little, less dense and includes new bone is mature and less collagen matrix and minerals percentage of control . This could explain the importance of the innervation intact for healing bones and normal. However, the delayed healing of fractures of the limbs paralyzed front in neurectomized group in this study can also be attributed in part to the absence of low load or weight-bearing factor on the healing of the fracture that is agree with [6].

The positive impact of these forces is to increase the periosteum of bone formation in the fracture 3rd metacarpal bone, and increase the blood flow and also bone remodeling that is agree with [7 At the same time, he signed micromovements in the limbs paralyzed during movements of animals has also played some positive effect that is agree with [8] and [9], which demonstrated that micro - movement pivotal role in the fracture site has been shown to encourage and promote healing from the fractures, that is agree with [10].The process of the bone remodeling is a natural process that couples bone resorption and bone formation , occurs in separate places and involves a range of different types of cells in the area of the surface of the bone to complete one cycle of bone remodeling. Morphologically and physiologically separate bone tissue from the bone marrow by cells lining the process of cancellous bone remodeling occurs

on the surface of the trabecular on the border between the bone and marrow . And bone remodeling occurs in the basic multicellular unit (BMU) and the skeleton contains millions, that is agree with [11]

It have found increased callus formation, a greater and more rapid healing response. The bone response after denervation is not only due to a local effect, but also to a systemic response, that is agree with [12] .

The wound repair in the central nervous system damage do not follow prior to the renewal of nerve cells. Unlike the response seen in the peripheral nervous system, where it can be transformed to renew axes, and repaired the beginning of axons in the central nervous system damage first, that is agree with [13] . The neuroectomy is a surgical procedure that destroys nerves of the median nerve, which are collections of nerve cell bodies in clusters along the thoracic or lumbar spinal cord, that is agree with [14] .

دراسة شعاعية وتقييمية لتأثير قطع العصب الوسطاني على بعض المعادن والتنم عمم عظم المشط الثالث في الحمير

عبد الباري عباس ساهي* ، علاء عبد الخالق سواد** علي كريم محمد*

*فرع الجراحة والتوليد، كلية الطب البيطري ، جامعه البصرة ، البصرة العراق

** فرع الأنسجة والتشريح، كلية الطب البيطري ، جامعه البصرة ، البصرة العراق

الخلاصة

تشير هذه الدراسة الى تأثير قطع العصب الوسطاني على بعض المعادن والتنم عمم المشط الثالث في الحمير ، وتم تقييم نتائج الدراسة من خلال تسجيل العلامات السريرية والصور الشعاعية وتقدير بعض المعادن مثل الكالسيوم والفسفور .

استخدم في هذه الدراسة ستة عشر حمارا ذكر بعمر يتراوح بين ١.٥-٢ سنة ووزن ١٢٥-١٥٠ كغم .

قسمت حيوانات التجربة الى مجموعتين هما مجموعة غير مقطوعه العصب ومجموعه مقطوعه العصب الوسطاني ، خدرت الحيوانات باستخدام الزيلازين والكيامين حقنا بالوريد .

في مجموعة غير مقطوعه العصب تم احداث كسر في عمم المشط الثالث في القائمه الاماميه ، قيمت نتائج المجموعة عبر ملاحظه العرج وتورم موقع الكسر وملاحظه تكون الثفن مع تقدير مستوى الكالسيوم والفسفور بفترات ٣٠ و ٦٠ يوم على التوالي .

اما مجموعة مقطوعة العصب الوسطاني لوحظ العلامات السريرية من خلال الشلل في القائمه الأمامية اليمنى مقطوعة العصب وعدم قدرة الحيوانات على تحمل الوزن اما من خلال ملاحظة الصور الشعاعية لوحظ وجود ثفن قليل مع ملاحظة وجود خط الكسر .

اما في مستوى المركبات اللاعضويه فقد سجل الكالسيوم انخفاضا كبيرا للغايه بينما اظهر الفسفور زيادة في ٣٠ يوم وانخفاض في ٦٠ يوم. مما يدل تأثير قطع العصب على التئام الكسور بشكل سلبي .

REFERENCES

- [1]- **Otfinowski J. (1993).** Heterotopic induction of osteogenesis in the course of neural injury. Patol- pol 44:133-68.
- [2]- **Purves D., Augustine GJ. and Fitzpatrick D. (2008).** Neuroscience Sinauer Associates. pp. 11–20.
- [3]- **Bohart G. (1997).** Anesthesia of horses in the field. In: Current Therapy in equine Medicine , 4:34 – 36.
- [4]- **Nottag WM. (1981).** Areview of long bone fractures in patients with spinal cord injuries. Clin orthop 155: 65-70.
- [5] -**Aro H. (1985).**Effect of nerve injury on fracture healing. Acta orthop scand.56:233-7.
- [6]- **Meadows TH., Bronk JT.and Chao EYS. (1990).** Effect of weight bearing on the healing of cortical defects in the canine tibia J Bone Joint Surg.72A:1074.
- [7]- **O' Sullivan ME., Bronk Jt. and Chao EYS. (1994).** Experimental study of the effect of weight bearing on fracture healing in the canine tibia.Clin orthop. 302:273-83.
- [8]- **Goodship AE. and Kenwright J. (1985).** The influence of induced micromovement upon the healing of experimental tibial fractures. J Bone Joint Surg. 67B:650.
- [9]-**Wallace AL., Draper ERC. and Strachan RK. (1994).** The vascular response to fracture micromovement. Clin orthop. 301: 281-90.

- [10]- **Kenwright J., Richardson JB. and Cunningham JL. (1991).** Axial movement and tibial fractures: A controlled randomized trail of treatment. *J Bone Join Surg.*73B: 654.
- [11]- **Kular J., Tickner J., Chim SM. and Xu J. (2012).** An overview of the regulation of bone remodelling at the cellular level. *Clin Biochem*;45:863–873.
- [12]-**Madsen JE., Aune AK., Falch JA., Hukkanen M., Konttinen YT., Santavirta S. and Nordsletten L.(1996)** Neural involvement in post-traumatic osteopenia: an experimental study in the rat. *Bone.* 18:411– 416.
- [13]- **Zhao B-Q., Wang S., Kim H-Y., Storrie H., Rosen BR., Mooney DJ., Wang X. and Lo EH.(2006).** Role of matrix metalloproteinases in delayed cortical responses after stroke. *Nature Medicine* ;12(4):441.
- [14]- **Otfinowski J. (1993).** Heterotopic induction of osteogenesis in the course of eural injury. *Patol-pol* 44:133-68.