

The effect of Henna (*Lawsonia inermis*) on the wound healing of Local Arabian Horses

دراسة تأثير الحناء على التئام الجروح في الخيل العربية المحلية

Amir I. Towfik

Arabian horses center

Al-Qadisyia University

Amir_vet_58@yahoo.com

Abdul- Satar S. Hamza

Veterinary Medicine College

Al-Qadisyia University

satar.salman@yahoo.com

Ahmed K. Munahi

Veterinary Medicine College

Al-Qadisyia University

a_munahi@yahoo.com

Summery

This study was conducted on (15) local horses to assess the effect of henna extract on wound healing in horses , the horses divided randomly into five groups (first four groups were regarded as henna extract solutions treatment 5%, 10%, 15%, 20% respectively and the fifth group was regarded as control group) and (3) horses for each group.

All the horses were submitted to cutaneous incisions in the neck regions , the henna extract treatment groups were treated locally and daily for (21) days except the control group which treated with distal water only.

The clinical signs of each wound were recorded daily and swabs were taken for bacterial examinations at (7, 14, 21) days to diagnose the types of bacteria which grew in the wounds and study the effect of henna extract on their growth, at first they were cultured in nutrient broth and smears were done for gram stain evaluation then they transferred to special media for each type of them, red manitol agar for *Staphylococcus aureus* , blood agar and brain heart broth for *Streptococcus equi* and cetrimide agar for *Pseudomonas erogenosa* .

The results showed the superiority of the henna extract solution at 20% concentration according to the clinical signs of the wound (swollen, bleeding, dryness, abscess formation, epithelization and scar tissue formation) and the henna extract solution with its different concentrations showed gradually absence of wound edges swollen, no bleeding, dryness, intensive growth of epithelial tissue, no abscess formation and scar tissue since the first week of the treatment.

Also the results showed clearly the cidal effect of the henna extract solutions (10%, 15%, 20%) respectively for the *Staphylococcus aureus* , *Streptococcus equi* , *Pseudomonas erogenosa*.

The histo – pathological examination of the wound which treated by henna extract solution at 20% concentration showed strong healing with thick keratinized tissue, hyperproliferation of the epidermal layer, presence of profuse fibrosis and clear growth of new blood vessels in compare with control group .

Key words: henna, wound, healing, local, Arabian, horses

الخلاصة

شملت الدراسة (15) خيلا عربية محلية لمعرفة تأثير مستخلص الحناء على التئام الجروح في الخيل ، حيث قسمت الخيل الى خمسة مجاميع عشوائية (أربعة منها مجاميع معالجة بمحلول مستخلص الحناء بتركيز 5% ، 10% ، 15% ، 20% ومجموعة خامسة اعتبرت مجموعة سيطرة) بواقع ثلاثة خيول لكل مجموعة.

تم عمل شقوق جراحية في الجلد لمنطقة الرقبة لجميع حيوانات التجربة ، ووضع مستخلص الحناء وحسب التراكيز المحددة لكل مجموعة معالجة موضعيا وبصورة يومية لمدة (21) يوما عدا مجموعة السيطرة حيث عولجت بمحلول الماء المقطر فقط طيلة فترة التجربة .

سجلت العلامات السريرية يوميا لكل جرح وأخذت مسحات لغرض الفحص البكتيري في يوم (7 ، 14 ، 21) ولغرض تشخيص انواع البكتيريا الموجودة في الجروح ودراسة مدى تأثيرها بمستخلص الحناء تمت زراعتها على وسط زرعي مغذي عام ثم عملت منها شرائح زجاجية وصبغت بصبغة الكرام ونقلت في اوساط زرعية متخصصة لكل منها ، حيث استخدم وسط

المانتول الاحمر للمكورات العنقودية الذهبية ، ووسط الدم ثم المرق الدماغى القلبي المغذي للمسبقيات الخيلية ، ووسط
السترامايد للمتقلبات ايروجينوزا .
أظهرت النتائج تفوق محلول مستخلص الحناء بتركيز 20% على جميع التراكيز الاخرى من حيث العلامات للجروح
(تورم حافات الجرح ، النزف ، جفاف الجرح ، تكون الخراج ، التظهير ، تكون نسيج الندبة) وقد أظهر محلول مستخلص
الحناء بتركيزه المختلفة وبدرجات متفاوتة عدم وجود تورم في حافات الجرح وانعدام النزف وجفاف الجرح مع نمو شديد
للسيج الظهاري وانعدام تكون الخراج ونسيج الندبة منذ الاسبوع الاول للمعالجة .
كما بينت النتائج التأثير الفعال لمحلول مستخلص الحناء 10% ، 15% ، 20% على التوالي للمكورات العنقودية الذهبية
والمسبقيات الخيلية والمتقلبات ايروجينوزا على مدى الفترة الزمنية للتجربة .
وأظهر الفحص النسيجي للجروح المعالجة بمحلول مستخلص الحناء بتركيز 20% التئام شديد مع نسيج متقرن سميك مع
فرط التكاثر لطبقة البشرة ووجود تليف غزير ونمو واضح للأوعية الدموية الجديدة مقارنة مع مجموعة السيطرة .
الكلمات المفتاحية : حناء ، جرح ، التئام ، محلية ، عربية ، خيل

Introduction

Henna(Lawsonia inermis, syn.L.alba) was a flowering plant 2-6m in height. It produced a burgundy dye molecule, Lawsonia(1).

The plant Henna, family Lythraceae was a shrub that was naturally grown or cultivated from north-east Africa to India. Marketed henna represented a natural material derived from dried and powdered leaves of the plant(2).

Lawsonia, dye molecule had an affinity for bonding with protein, and thus had been used to dye skin, hair, finger nails, leather, silk and wool. This molecule lawsonia was primarily concentrated in the leaves(3).

In some parts of the world, plants and herbs were still the prime medicines used in medical treatment(4),(5).Its core chemical components were 2-hydroxynaphthoquinone(Lawsonia), mannite, tannic acid, mucilage and gallic acid. Out of these ingredients, the main one was Lawsonia. Its bioactive feature was thought to be due to its high protein binding capacity(1),(7).

The main uses of henna were as a cooling agent, astringent, antifungal and anti-bacterial herb for the skin and hair(6),(7).Many types of bacteria had ability to produce skin infections. Staphylococcus aureus was the most common cause of skin infections(8).

(9) mentioned that ethanol extracts of henna had exhibited more prominent wound healing activity in rats, while (3) found that when measuring the antibacterial activity of henna extracts, alcoholic and oily extracts were more effective than the water based extract which had no effects.

The study of (10) showed that the ethyl acetate extract of Lawsonia inermis was found to be the most active one against all bacteria, gram-positive and gram- negative.

(11) found that the excision wound model on rats, the topical application of ethanol extract of henna showed 71% reduction in the wound area when compared with control group, enhanced wound contraction, increased skin breaking strength, hydroxyproline and histological findings suggested the use of Lawsonia inermis in the management of wound healing.

The wound healing property of the leaves extract of henna appeared to be due to the presence of its active principles(alkaloids, flavonoids, lignins, triterpenoids, fixed oils, fats, proteins and amino acids) which accelerated the healing process and confers breaking strength to the healed wound. This study was demonstrated that an ethanolic extract of henna leaves had properties that render it capable of promoting accelerated wound healing activity compared with control group, wound contraction, increased tensile strength activity in the topical treatment and management of wounds(12).

The aim of this study is to evaluate the effect of Lawsonia inermis extract on wound healing in local Arabian horses.

Materials and methods

The study is conducted on five groups with three horses in each group in Al-Diwaniya province. All the horses are local Arabian breed, feed on grains, Alfa Alfa, hays, minerals and vitamins, they housed with same conditions . Their ages range (3-5) years.

The water- based henna extract is prepared by (500) gm of fine leaf powder of henna (bought from local shop in Al- Diwaniya city) are suspended in (1500) ml. of absolute ethanol for (24) hours at room temperature.

The mixture is filtered by filter paper then the filtrate is placed in a water bath to dry at (40 c°) and the final ethanol free clear residue is used for the study, the residue is diluted with distilled water as 5% (group 1), 10% (group 2), 15% (group 3), 20% (group 4) and the fifth group is regarded as a control group which treated with distilled water.

All experimental horses are incised (10 cm) in the neck region as the surgical protocol. Each open wound (except of the control group) is treated by different concentrations of henna solutions as design for each group daily.

The clinical observations are recorded, biopsy samples (1 cm³) are taken surgically under local anesthesia (lidocain 2% 5ml.) for histo-pathological examinations at 7,14,21 days of the healing processes.

The histo-pathological sections is stained with eosin- hematoxiline and examine by light microscope x 40 according to Luna method.

The bacterial swabs are taken at the same times of biopsies for bacterial examination. They are cultured in nutrient broth media as general media, then they are cultured in their specific selective media for each one, Staphylococcus aureus in red manitol agar, Streptococcus equi in brain heart broth, Pseudomonas earogenosa in cetrimide agar respectively.

Results

Table -1: clinical observations of the experimental wound according to the duration and concentration

| No | Duration | Clinical signs | 5 % | 10 % | 15 % | 20 % | Control group |
|----|----------|-----------------------|-----|------|------|------|---------------|
| 1 | 7 days | Swallon | + | + | - | - | +++ |
| 2 | | Bleeding | + | + | + | - | ++ |
| 3 | | Dryness | + | ++ | ++ | +++ | - |
| 4 | | Abscess formation | +++ | - | - | - | +++ |
| 5 | | Epithelization | + | + | + | + | - |
| 6 | | Scar tissue formation | ++ | + | + | + | +++ |
| 7 | | | | | | | |
| 1 | 14 days | Swallon | + | - | - | - | ++ |
| 2 | | Bleeding | - | - | - | - | - |
| 3 | | Dryness | ++ | ++ | +++ | +++ | - |
| 4 | | Abscess formation | + | - | - | - | + |
| 5 | | Epithelization | + | ++ | +++ | +++ | + |
| 6 | | Scar tissue formation | + | - | - | - | ++ |
| 7 | | | | | | | |
| 1 | 21 days | Swallon | - | - | - | - | + |
| 2 | | Bleeding | - | - | - | - | - |
| 3 | | Dryness | +++ | +++ | +++ | +++ | - |
| 4 | | Abscess formation | - | - | - | - | - |
| 5 | | Epithelization | ++ | +++ | +++ | +++ | + |
| 6 | | Scar tissue formation | - | - | - | - | + |
| 7 | | | | | | | |

(+):Mild
 (++)Moderate
 (+++):Severe

Table-2:The result of bacterial cultures according to the durations and concentration

| No. | Type of bacteria | Duration | 5 % | 10 % | 15 % | 20 % | Control group |
|-----|------------------------|----------|-----|------|------|------|---------------|
| 1 | Staphylococcus aureus | 7 days | +++ | ++ | - | - | +++ |
| 2 | Streptococcus equi | | +++ | ++ | + | - | +++ |
| 3 | Pseudomonas aerogenosa | | +++ | + | + | - | +++ |
| 1 | Staphylococcus aureus | 14 days | +++ | ++ | - | - | +++ |
| 2 | Streptococcus equi | | +++ | ++ | + | - | +++ |
| 3 | Pseudomonas aerogenosa | | +++ | + | + | - | +++ |
| 1 | Staphylococcus aureus | 21 days | +++ | + | - | - | +++ |
| 2 | Streptococcus equi | | +++ | + | + | - | +++ |
| 3 | Pseudomonas aerogenosa | | +++ | + | + | - | +++ |

(+):Mild
 (++)Moderate
 (+++):Severe

Slides

Discussion

Although there are few researches about the effect of henna on wound healing in horses, the results of this study show many scientific facts.

Normally, any wound show swollen of its edges due to the destruction of tissue cells, blood vessels (hematoma & clot formation) and promoting of histamine release .

Table – 1 show that the swollen exist severely at 7 days in the control group as well as 5% group while it is mild with 10% , 15% and 20% groups respectively due to its cool effect.

The bleeding is severe in the first minutes with the control group and 5% group, while no bleeding has been recorded with 10%, 15% and 20% groups respectively due to the affinity of (Lawsone) molecule which binding with the blood protein (Fibrinogen and Thrombin) that's forms good clotting (3) &(6).

The clinical observations also show that , the henna extract at 20% concentration is the more effective concentration than others , there is no abscess formation, high wound tension , all the wounds are well dry so there is no suitable media for bacterial growth due to that henna has good bactericidal effect of it's important constituent 2 – hydroxynaphthoquiner (Lawsone). This result agree with (1) &(7).

Its worthwhile to mention , that the results in (table -1) show grossly very well wounds tension specially with 20% concentration group due to the presence of tannic acid as astringent material (6) &(7).

The constituents of henna (13) are present in the form of a mixture. Antimicrobial activity may be due to numerous free hydroxyls that have the capability to combine with the carbohydrates and proteins in the bacterial cell wall. They may get attached to enzyme sites rendering them inactive (14).

Lawsone has also been reported to be an immune-stimulant (15). One of the main constituents of henna is flavonoids (16). The flavonoids are well – known for their role in wound healing (17).

Henna leaf extracts have antimicrobial activity on the bacteria responsible for the common skin infections. Alcoholic and oily henna extracts have similar effects to some of the antibiotics (Benzyl Penicillin) commonly use in clinical practice (18).

Moreover, there are the reports that bioflavonoids have pharmacological activities such as antioxidant activities (19).

Table – 2 show that the ethanol henna extract inhibit the bacterial growth at 10% concentration, while act as bactericidal for *Staphylococcus aureus* at 15% concentration. But at 20% concentration it act as bactericidal for all the types of bacteria which include in this study.

These results may be due to the bactericidal effect of anthraquinones as major constituent of the henna leaves (20).

The results of the histopathological exams show that there are wide differences between the control group and the treatment groups especially the 20% concentration group.

After one week the control group show absence of the keratinization with mild fibrosis and scant collagen (fig 1), while especially in the 20% treatment group there are narrow scar tissue, fibrosis and thick keratinization (fig 5).

But after three week the control group show absence of keratinization, profuse fibrosis with formation of new blood vessels and abundant collagen with different directions (fig 11), while 20% treatment group show strong and more developed healing, thick keratinization, high proliferation of epidermal layer and profuse fibrosis with well orientation and formation of new blood vessels (fig 15).

These facts indicate that there are fibroblast proliferative activity with epithelization during short period (21) . So the proliferative fibroblasts will induce large amount of collagen which gives strength integrity to the tissue matrix and play role in homeostasis and epithelization at latter phase of healing (22). The henna extracts increase the wound contraction which increase tensile strength activity.

References

- 1- Harbone S.B. ; Baxter A. (1995). Phytochemical Dictionary. A handbook of bioactive compounds from plants. Tylor and Francis. London.
- 2- European Commission, Health and consumer protection Directorate-general. Directorate C- Public health and risk assessment scientific committee on consumer products SCCP Opinion on Lawsonia inermis (Henna) 13 December(2005).
- 3- Al-Rubaiy K. K. ; Jaber N. N. ; Al-Mhaawe B. H. and Al-Rubaiy L. K. (2008). Antimicrobial efficacy of Henna extracts. Oman Med J. 23 (4).
- 4-Natarajan V. ; Venugobal P. V. ; Menon T. (2003). Effect of Azadarichta indica (nem) on the growth pattern of dermatophytes. Indian J. Med. Microbiol; 21; 98-101.
- 5-Muhammad H. S. and Muhammad S. (2005). The use of Lawsonia inermis linn. (henna) in the management of burn wound infections. African J. Biotechnology; 4: 934-937.
- 6-Singh A. ; Singh D. K. (2001). Molluscicidal activity of Lawsonia inermis and its binary and tertiary combinations with other plant derived molluscicides. Indian J. exp. Biol. ; 39: 263-268.
- 7-Kelmanson J. E. ; Jager A. K. and Staden J. V. (2002). Zulu medicinal plants with antibacterial activity. J. Ethnopharm; 69: 241-246.
- 8-Sakarkar D. M. ; Sakarkar U. M. ; Shrikhande V. N. ; Yas J. V. V. ; Mandavgade S. ; Jaiswal S. B. and Purohit R. N. (2004). Wound healing properties of henna leaves. Natural Product Radiance. Vol.3 (6); 406-412.
- 9-Kluytmas S.J.,VanBelkum A.,Verbrugh H.(1997).Nasal carriage of Staphylococcus aureus:epidemiology,underlying mechanisms and associated risks.Clin.Microbiol.Rev.:10:505-520.
- 10-Awadh Ali N. A. ; Julich W. D. ; Kusnick C. and Lindequist U. (2002). Screening of Yemeni medicinal plants for antibacterial and cytotoxic activities. J. of Ethnopharmacology, 74: 173-179.
- 11-Nayak B. S. ; Isitor G. Davis E. M. and Pillai G. K. (2007). The evidence based wound healing activity of Lawsonia inermis Linn. Phytotherapy Research, 21: 827-831.
- 12-Nithya V. and Anusha Baskar. (2011). A preclinical study on wound healing activity of Lawsonia alba Linn. Research J. of Phytochemistry, 5: 123-129.
- 13-Kelmanson J. E. ; Jager A. K. and Staden J. V. Zulu.(2002). Medicinal planes with antibacterial activity. J. Ethnopharm.69: 241-246.
- 14-Herborne S. B. and Baxter A. (1995). Phytochemical dictionary. A handbook of bioactive compounds from plants. Tylor and Francis. London.
- 15- Kulkarni S. R. and Karande V. S. (1998). Study of the immune-stimulant activity of naphthoquinone extract of leaves of Lawsonia alba, Indian Drugs, 35:427.
- 16-Trease G. E. and Evans W. C. (1997). Extraction of plant material, separation and isolation of constituents. In: pharmacognosy, 14th edn, W.B. Saunders Company, London, 248.
- 17-Bair K. L. and Rao C. M. (2001).Wound healing profiles of Gingko biloba,J. Nat. Remed., 1: 25.
- 18-Narayama K. R. ; Reddy S. M. ; Chalvadi M. R. and Krishna D.RR. (2001). Bioflavonoids classification, pharmacological, biochemical effects and therapeutic potential, Indian J. pharmacol, 33, 2.
- 19-Abdulmoneim M. A. (2007). Evaluation Lawsonia inermis Linn. (Sudanese Henna) leaf extract as an antimicrobial agent. Research Journal of Biological Sciences, 2:417-423.
- 20-Khorshid F.,Ali S.S.,Alsofyani T. and Albar H.(2010). Plectranthus tenuiflorus (shara) promotes wound healing: In vitro and invivo studies. Int.J.Bot.,6;69-80.
- 21-Hassan S.W.,Abubakar M.G.,Umar R.A.,Yakubu A.S.,Maishanu H.M.and Ayeni G.(2011).Pharmacological and toxicological properties of leaf extracts of Kingeli Africana(bignoniaceae). J.Pharmacol.Toxicol.,6;124-132.
- 22-Sharma Y. , Jeyablan G. , Singh R. and Semwal A. (2013). Current aspect of wound healing agents from medicinal plants: a review. J. of Med. Plants Studies, 1:3 Pp: 1-11.

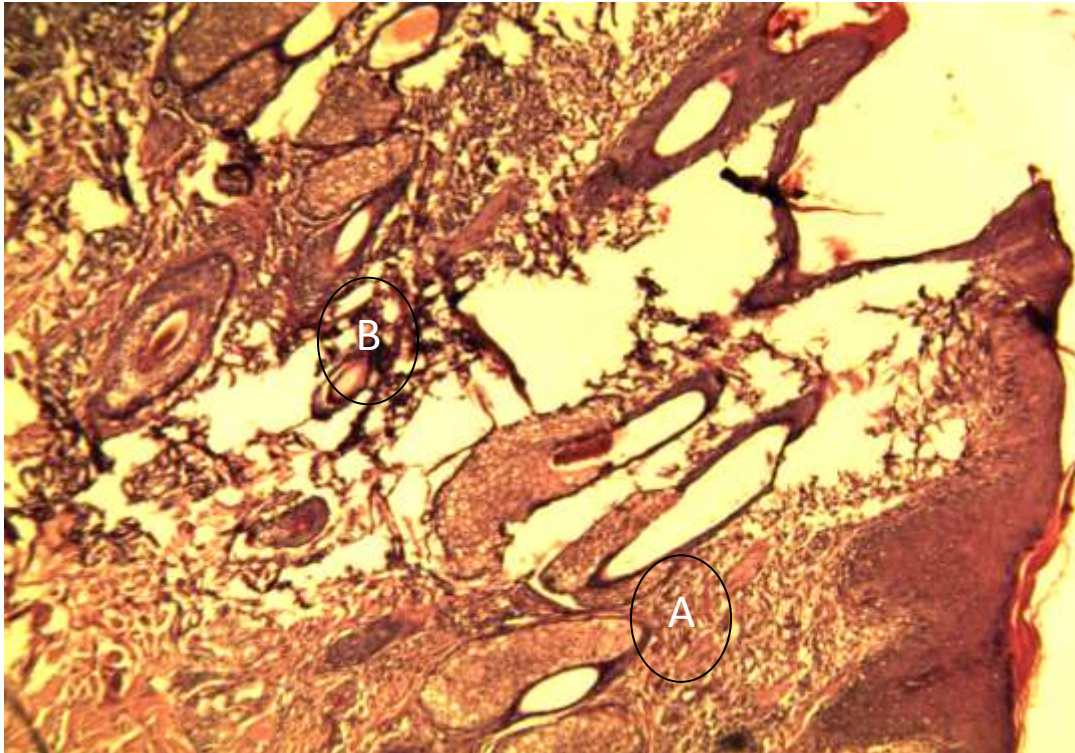


fig (1) after 1 week(control group) there is absence of keratinized layer proliferation of epithelial cells of epidermis,mild fibrosis(formation of fibros tissue network (A) and scand collagen(B)

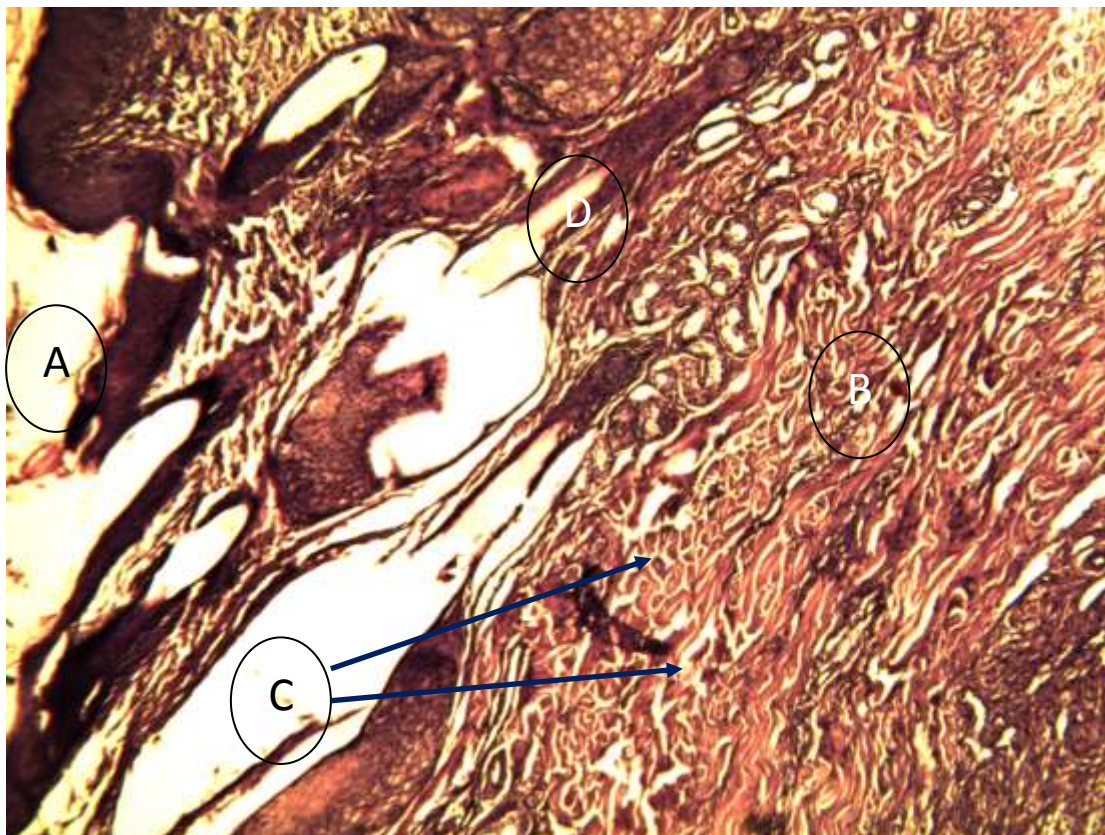


Fig.(2)after 1 week (5%con.solution)mild proliferation of epithelial cells of epidermis(thin epidermis)(A)abundant collagen with profuse fibrosis(B)mild infiltration of inflammatory cells (C)presence of sever hemorrhage with hemostasis(D)

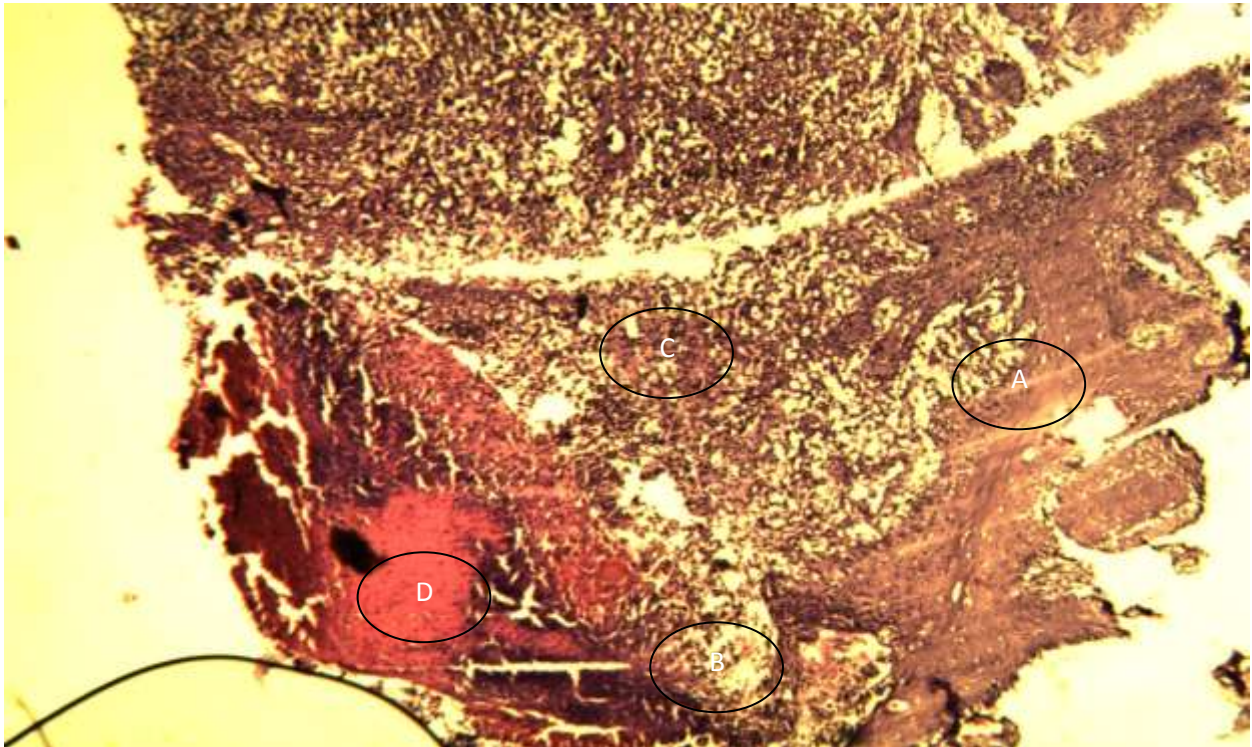


Fig.(3)after 1 week (10% con.solution) thick epidermis(A), downward hyperplasia of epidermal layer toward the dermis, infiltration of inflammatory cells(B) scant collagen with fibrosis(c), new formation of blood vessels(D).

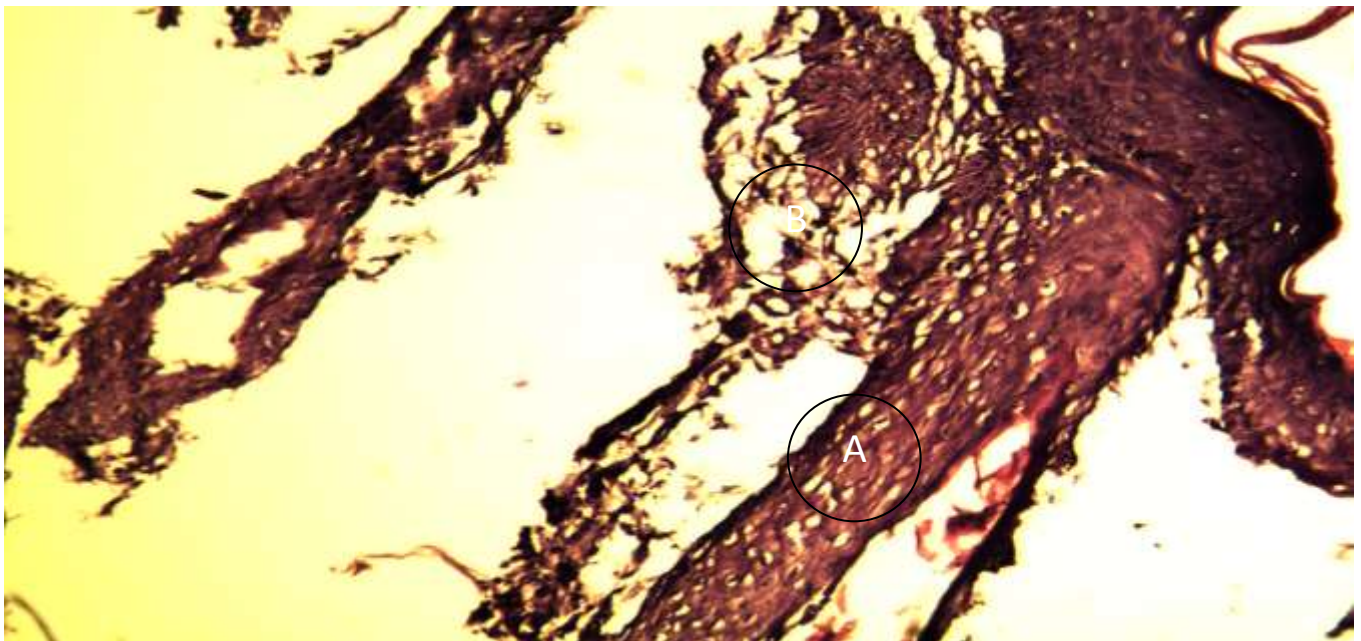
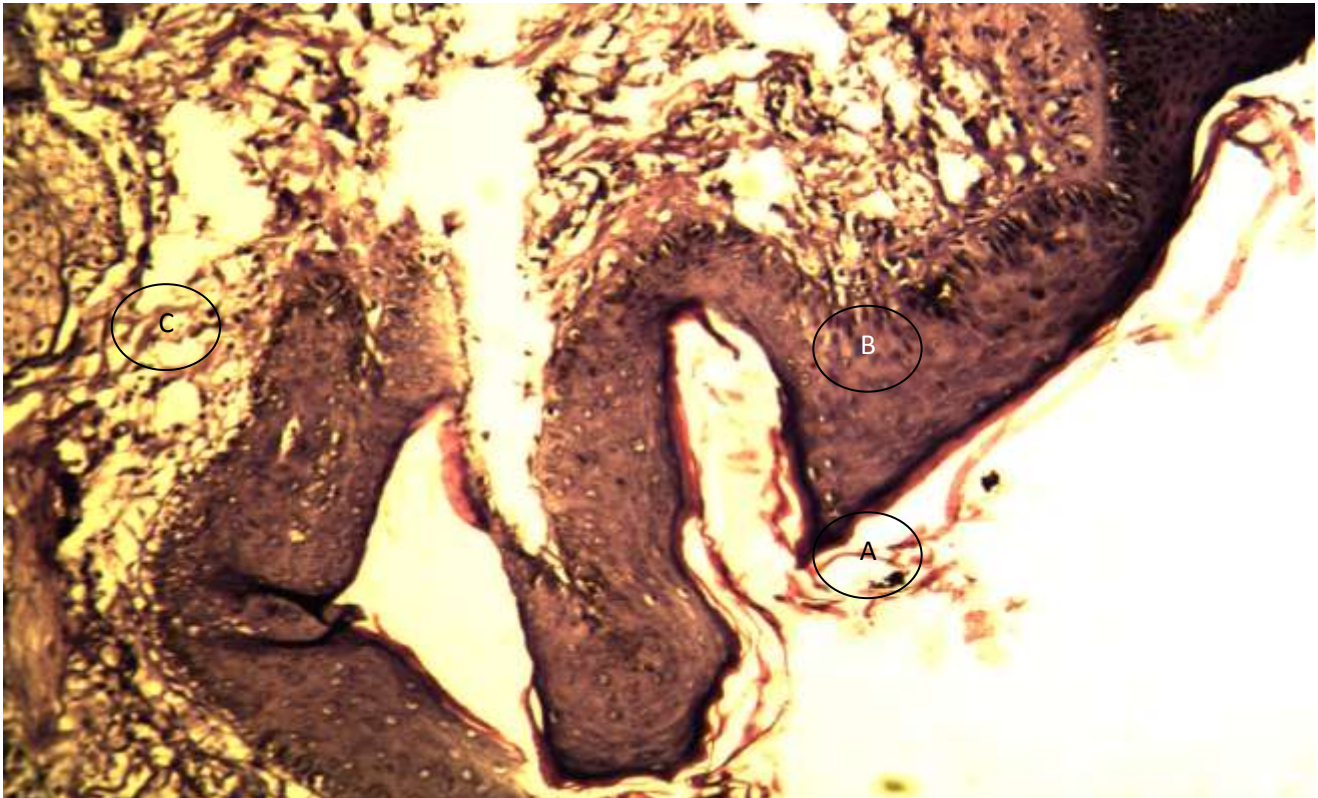


Fig.(4)after 1 week(15%con.solution)Thin keratinized layer downward hyperplasia of epidermal layers fibrosis(A), infiltration of inflammatory cells(B)



Fig(5)after1week(20%con.solution) there is narrow scar tissue(A), proliferation and thickness of epidermal layers(B), fibrosis with infiltration of inflammatory cells(C).

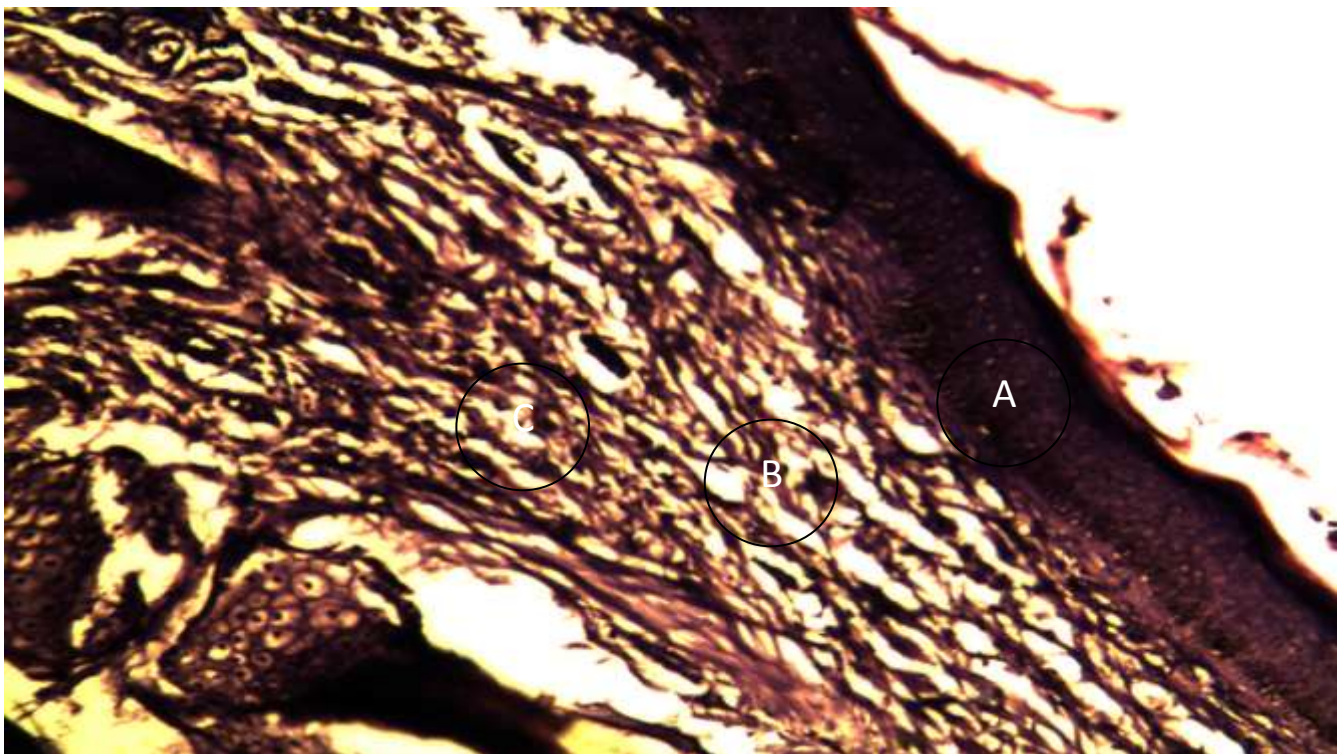


Fig.(6)after2week (control group)Proliferation of epidermal layers(A), abundant collagen fibrosis(B) with infiltration of inflammatory cells(C).

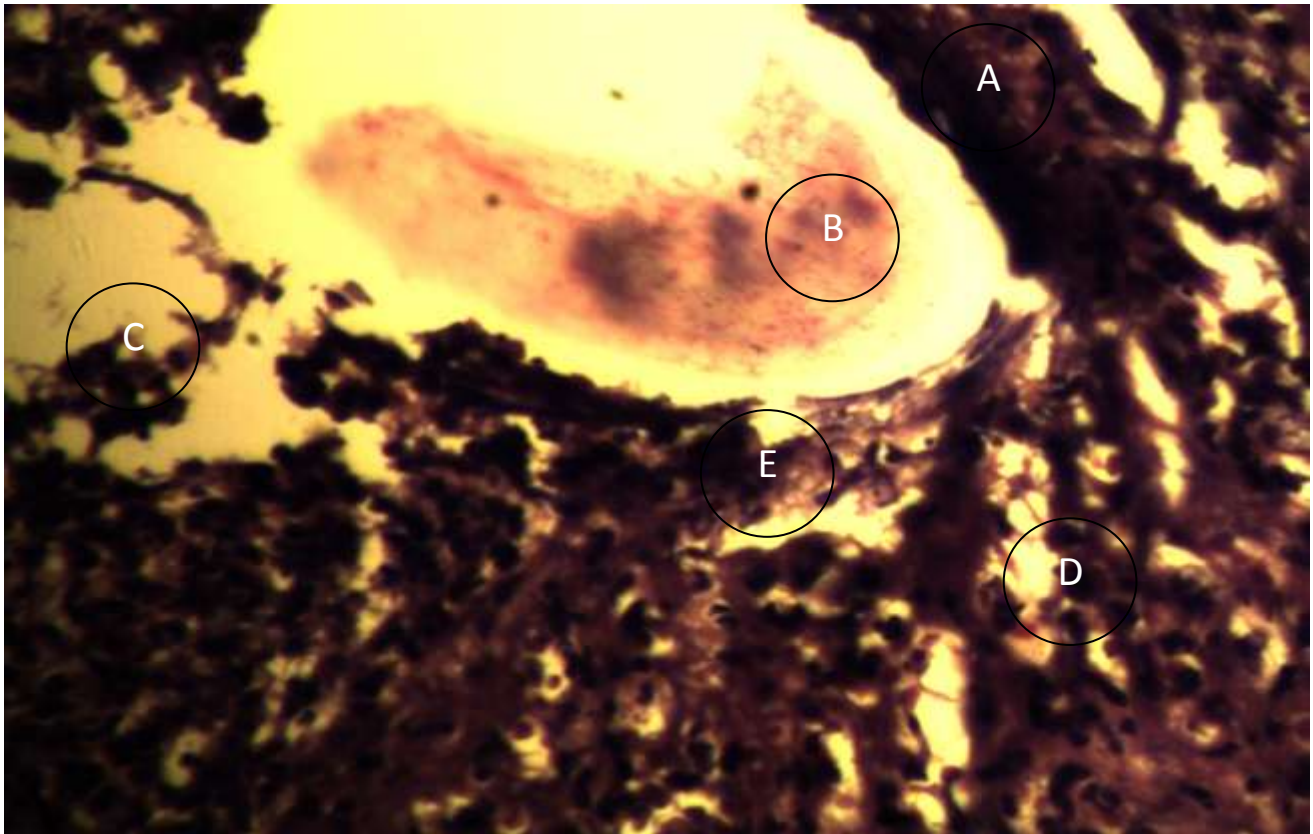


Fig.(7)after2week(5%con.solution)Downward hyperplasia of epidermal layers(A), severe hemorrhage(B), proliferation of endothelial cells to form new blood vessels(C), and proliferation of fibroblasts to form fibrosis(D), high infiltration of inflammatory cells(E).

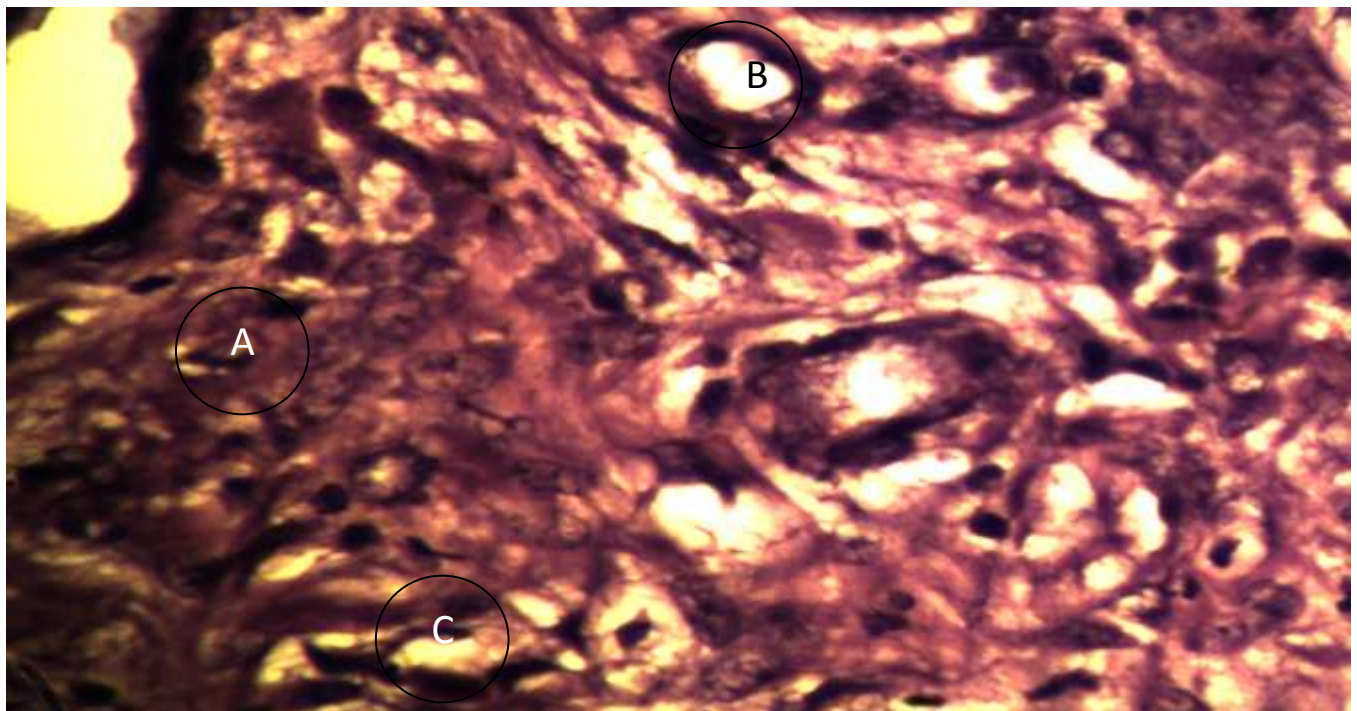


Fig.(8)after2week(10%con.solution)High thick of epidermis(A), presence of granulation tissue formation of new blood vessels vertically on the surface of skin(B) and severe fibrosis horizontally on the surface of skin(C).

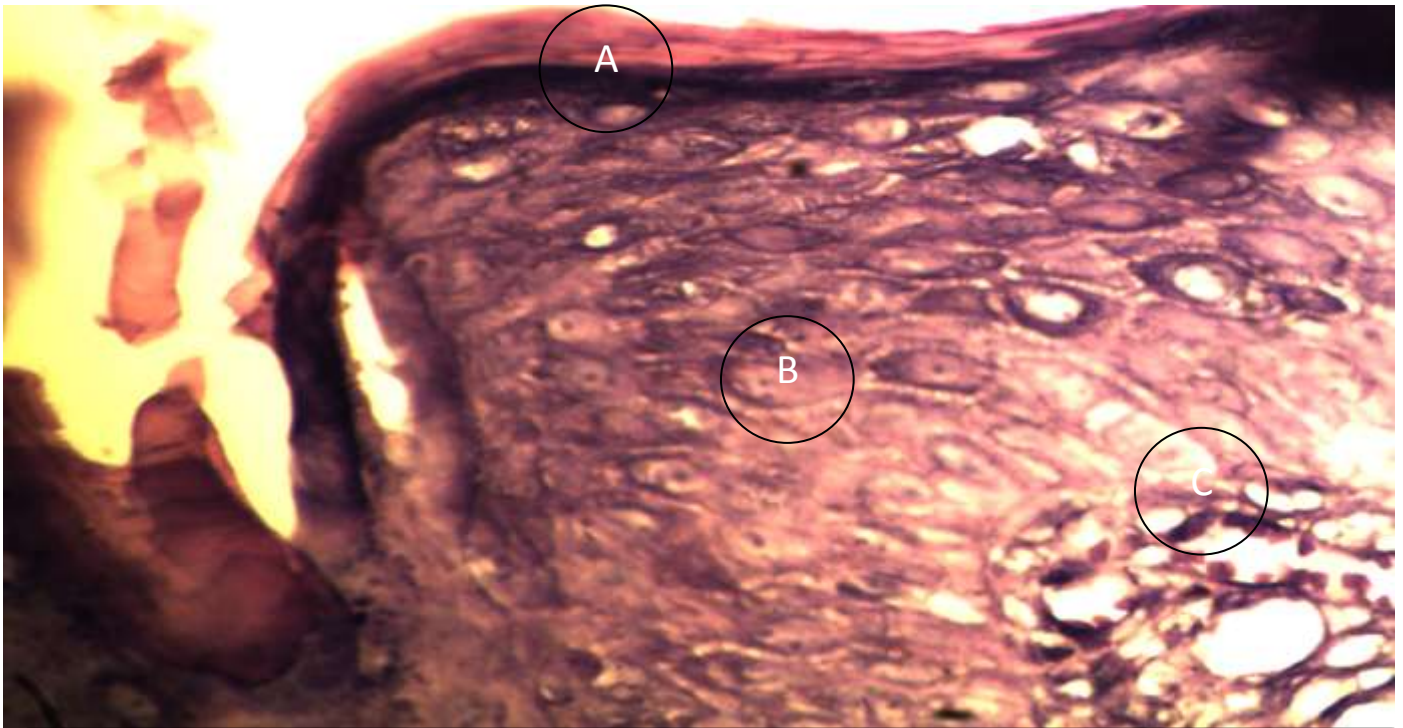

Fig.(9)after2week(15%con.solutionThick keratinized layer, thick epidermis with downward hyperplasia of epidermal layer(A), abundant collagen with profuse fibrosis(B) and severe infiltration of inflammatory cells(C).

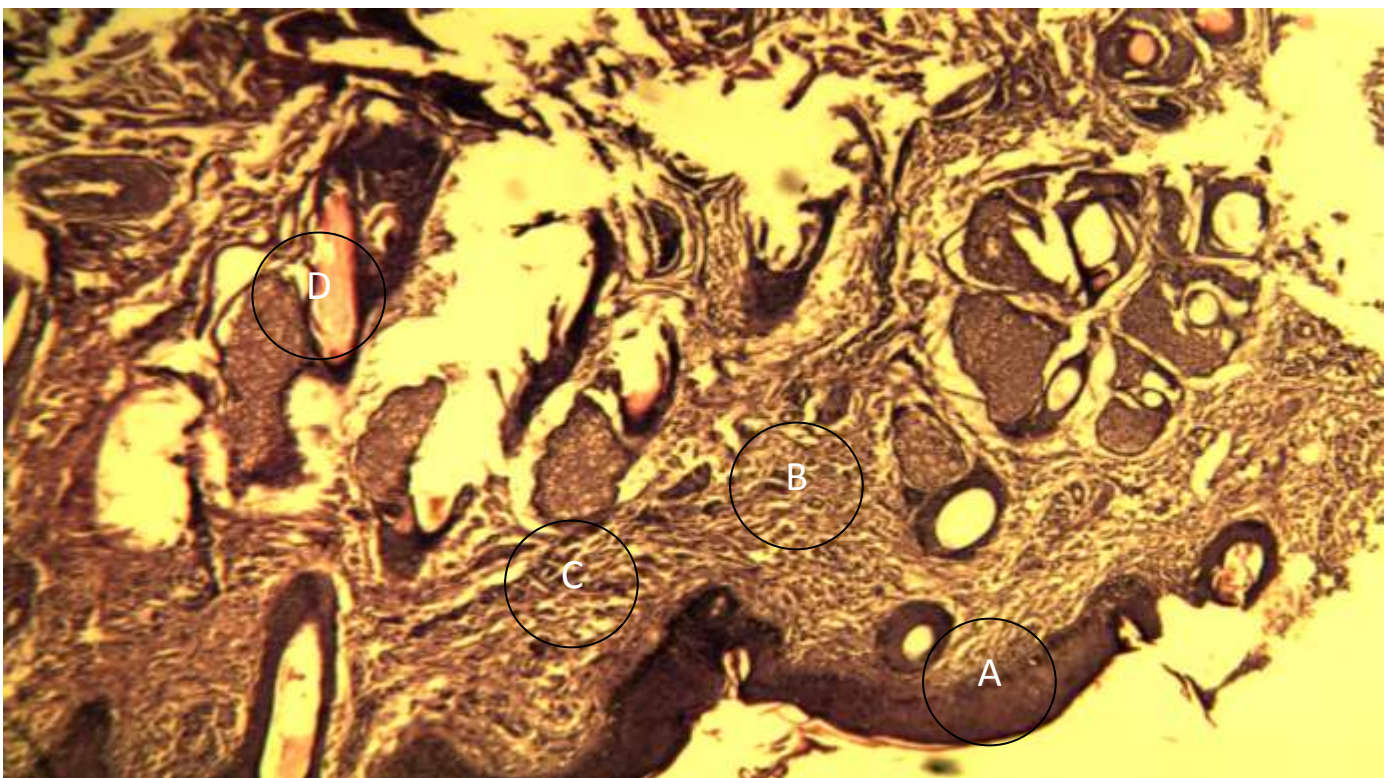


Fig.(10)after2week(20%con.solution)Thin keratinized layer(A), presence of epithelial invagination complete repair of epidermis(B), narrow coagulation zone with profuse fibrosis and abundant collagen (C)with formation of new blood vessels(D).

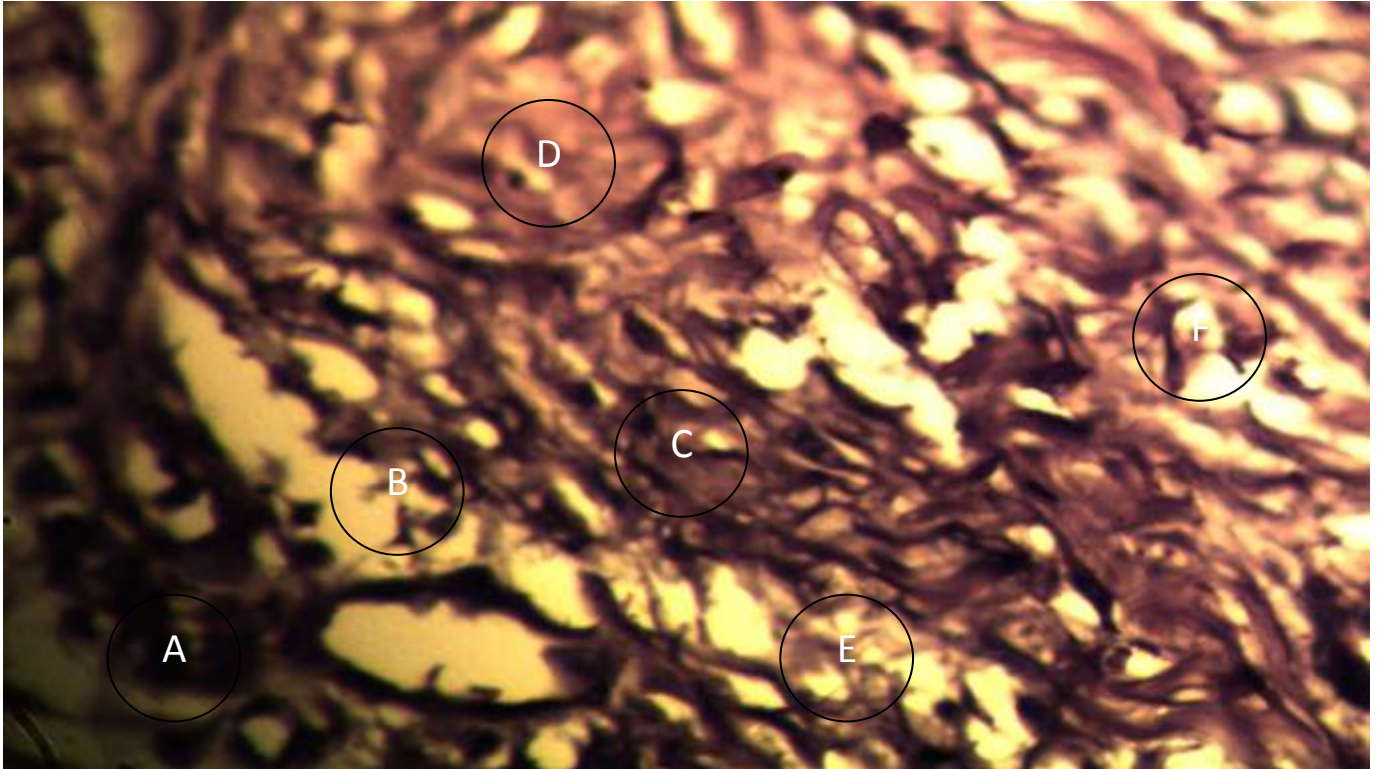


Fig.(11)after3weeks(control group)Wide scar tissue(A), absence of keratinized layer(B), thick epidermis(C), profuse fibrosis with formation of new blood vessels(D), abundant collagen (E)and scattered inflammatory cells(F).

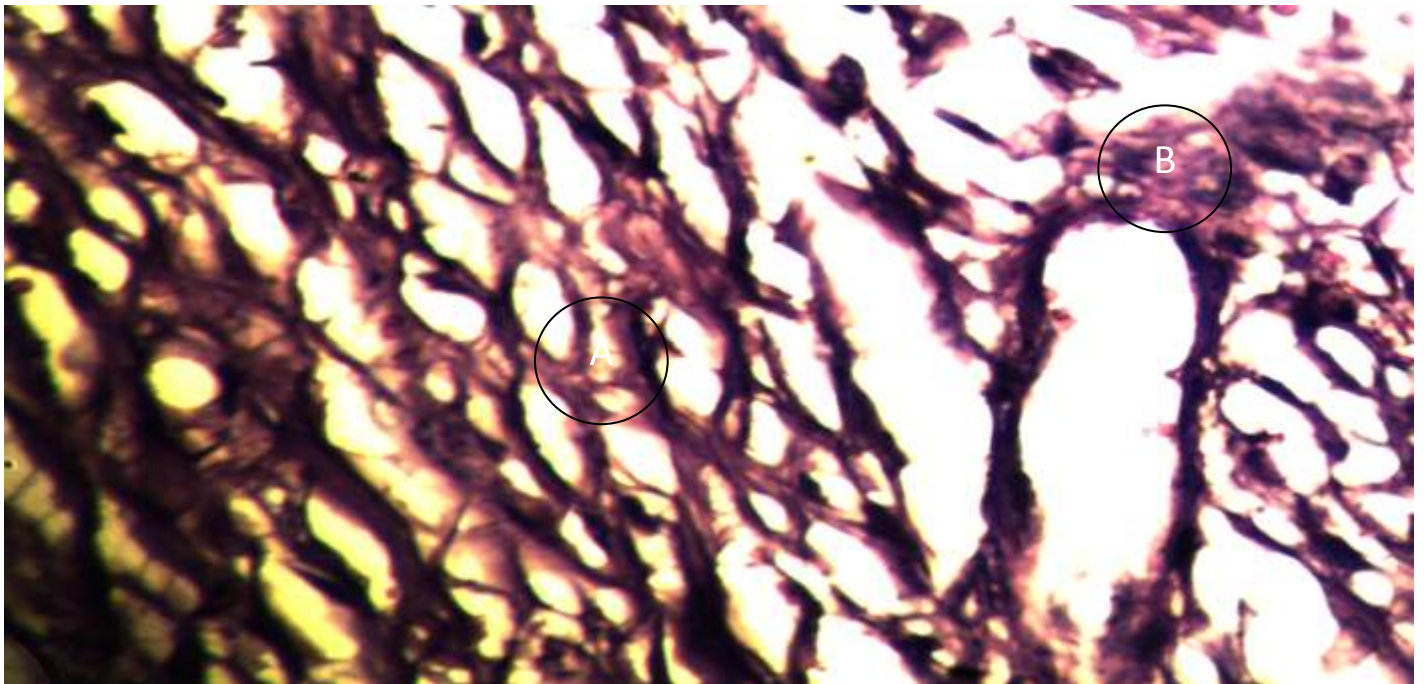


Fig.(12)after3weeks(5%con.solution)Absence of keratinized layer downward hyperplasia of epidermis, fibrous network with abundant collagen(A) and presence of hemorrhage(B).

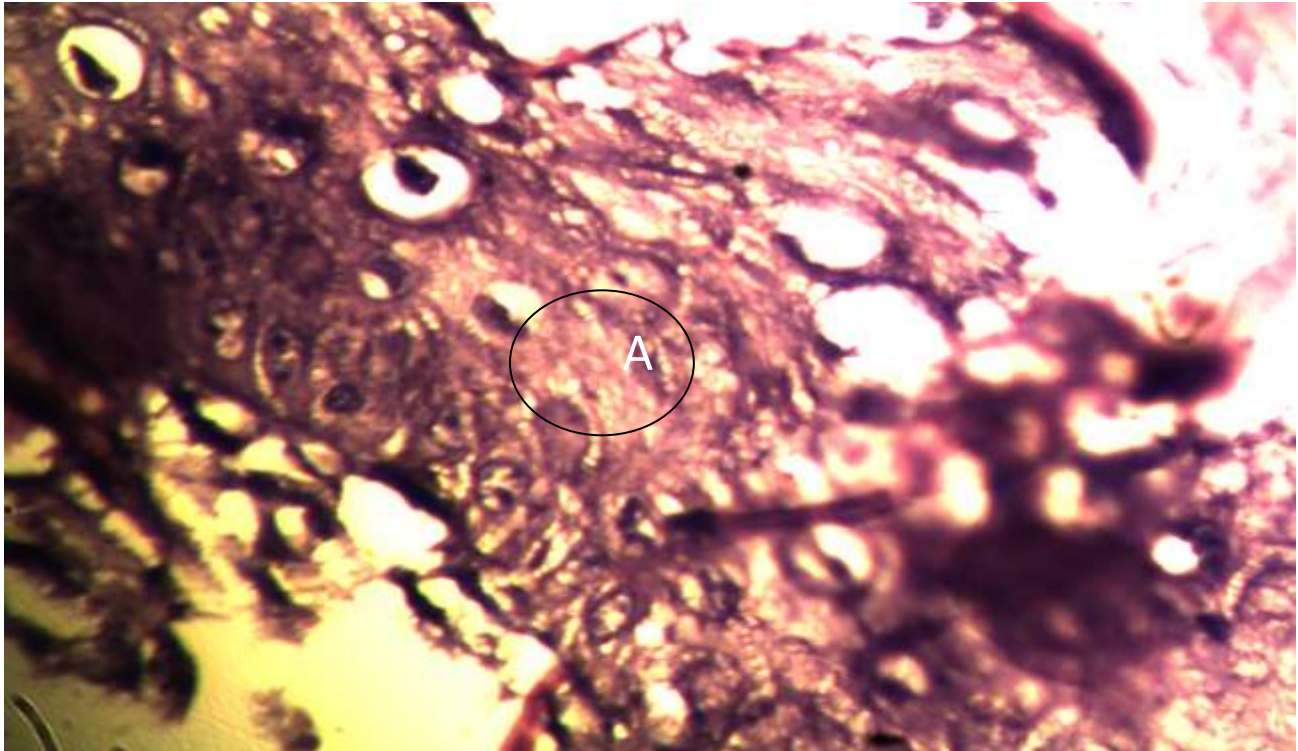


Fig.(13)after3weeks(10%con.solution)Weak healing there is proliferation of epidermal layer and fibrous extension(A) from adjacent tissue due to proliferation of fibroblast to form fibrous network to connect two edges of wound.

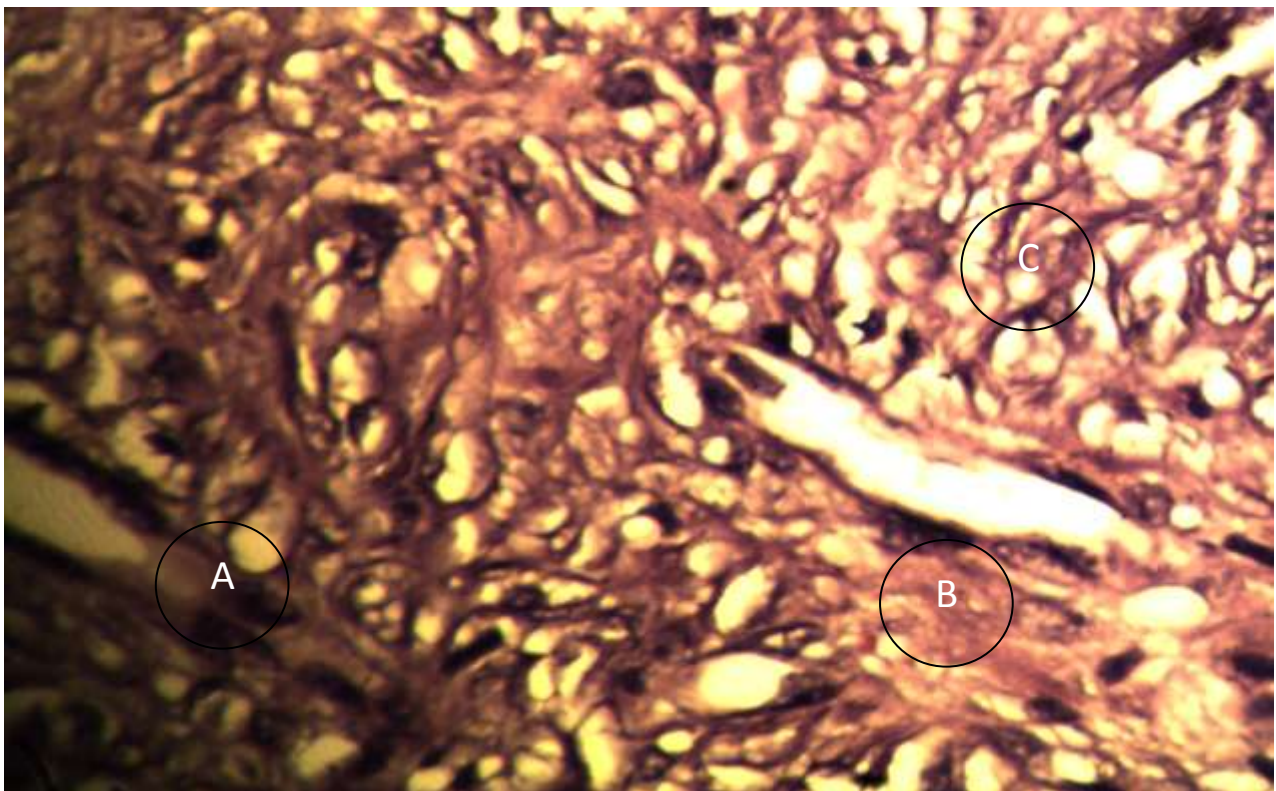


Fig.(14)after3weeks(15%con.solution)Strong and more developed healing, there is thick keratinized layer(A), high proliferation of epidermal layer (downward hyperplasia) profuse fibrosis(B) with formation (horizontal to the surface of wound) of new blood vessels (vertical to the surface of wound)(C).

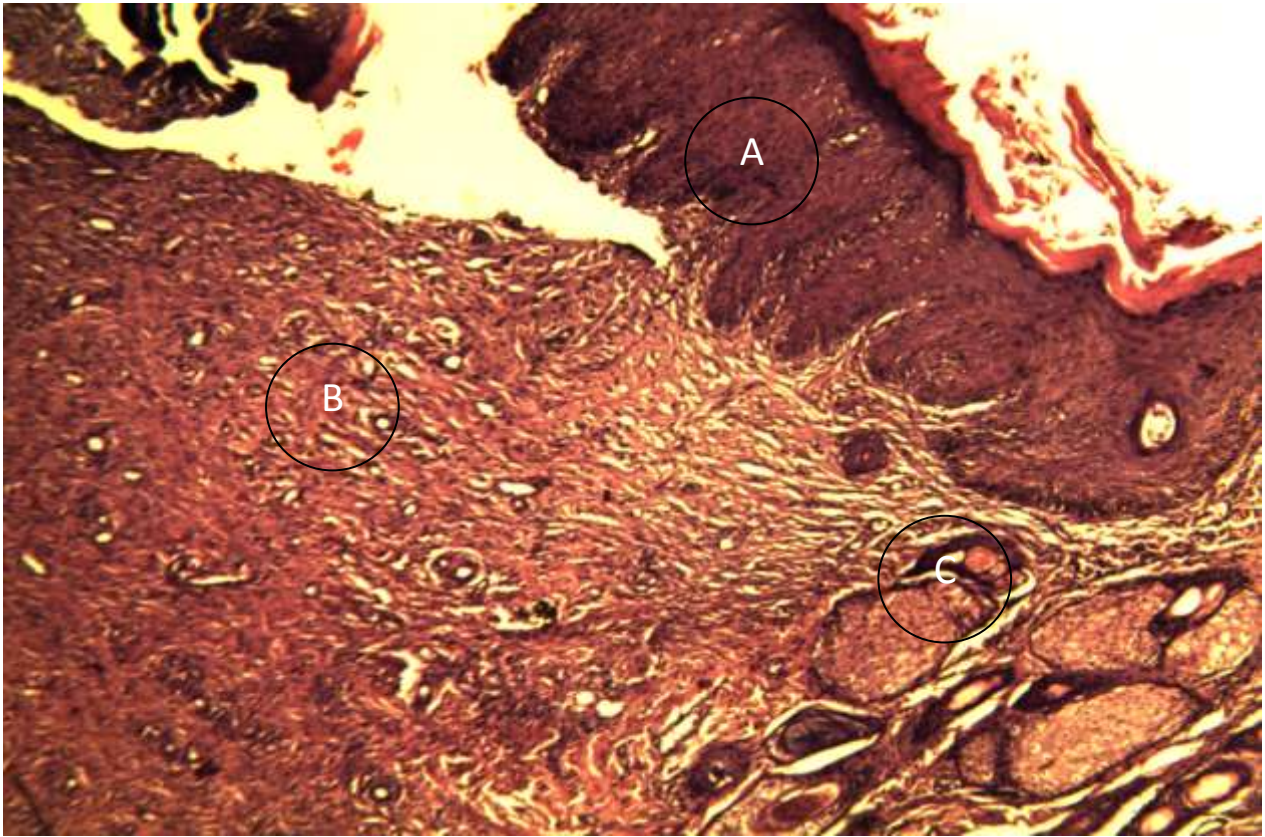


Fig.(15)after3weeks(20%con.solution)Strong and more developed healing, there is thick keratinized layer(A), high proliferation of epidermal layer (downward hyperplasia) profuse fibrosis(B) with formation (horizontal to the surface of wound) of new blood vessels (vertical to the surface of wound)(C).